

# Intramedullary K-Wire Fixation: A Feasible and Effective Technique in Treatment of Pediatric Distal Radius Fractures

## İntramedüller K-Teli Tespiti: Pediatrik Distal Radius Kırıklarının Tedavisinde Uygulanabilir ve Etkin Bir Teknik

Yusuf ERDEM<sup>1</sup>, Cagri NEYİSÇİ<sup>1</sup>

<sup>1</sup>Gülhane Training and Research Hospital, Orthopedics and Traumatology Department, Ankara

### Abstract

In this research we aimed to report the clinical and radiological results of a retrospective study performed on 6 children with severely displaced distal radial metaphyseal and diametaphyseal fractures, who were treated with percutaneous intramedullary Kirschner wire (K-wire) fixation. A total of 6 children with distal unstable radius fractures, all of whom have visible physal plate, were treated as an inpatient at our clinic January 2016 to June 2017. The average age was 8 years (range, 7–9 years). The fractures were fixed with two percutaneous intramedullary K-wires of 1.5-2 mm in diameter either transepiphyseally in three of them or both transepiphyseally and transcortically in the remaining three. Operative and short follow-up outcomes were assessed. The average operation time was 20 min (range, 15-25 min). Additional below-the-elbow splint was used in all cases for 3 weeks postoperatively. K-wires were removed after 6 weeks in all cases. Bone union was achieved at an average time of 4 weeks (range, 3-6 weeks) in all cases. No complication including malunion or early epiphyseal closure of the distal radius was identified at mean follow-up of 13 months (range, 4-18 months). Results of this study showed that reduction and osteosynthesis of distal displaced radius fractures in children by percutaneous flexible intramedullary K-wire fixation technique have many advantages regarding the maintenance of the stable construct with easy, minimally invasive and quick application. We thought that this method is a reliable treatment option for pediatric distal unstable radius fractures.

**Keywords:** Intramedullary Fixation, Pediatric, Unstable Radius Fracture

### Öz

Bu çalışmada, deplase distal metafizyal ve diametafizyal radius kırığı olan 6 çocuğun tedavisinde uyguladığımız intramedüller K-teli tespiti, klinik ve radyolojik sonuçlarını sunmayı amaçladık. Çalışmaya Ocak 2016-Haziran 2017 tarihleri arasında anstabil distal radius kırığı tanısı ile polikliniğe başvuran 6 çocuk hasta dahil edildi. Ortalama yaş 8 (dağılım 7-9) idi. Hastaların 3'ünde kırıklar 1.5-2 mm çapında perkütan uygulanan K-teli ile transepifizyal, diğerlerinde ise hem transepifizyal hem de transcortikal tespit edildi. Cerrahi sonrası kısa dönem takip sonuçları değerlendirildi. Ortalama ameliyat süresi 20 dakika idi (dağılım 15-25). Tüm vakalarda ameliyat sonrası 3 hafta boyunca ek olarak kısa kol splint kullanıldı. Tüm vakalarda 6 hafta sonra K-telleri çıkarıldı. Hastaların tümünde kemik kaynamasına ortalama 4 haftada (dağılım 3-6) ulaşıldı. Ortalama 13 aylık takipte (dağılım 4-18), malunion veya distal radiusun erken epifizyal kapanmasını içeren herhangi bir komplikasyon saptanmadı. Bu çalışmanın sonuçları, çocuklarda deplase radius distal kırıklarının perkütan olarak fleksible intramedüller K-teli tespit tekniği ile redüksiyonunun ve osteosentezinin, stabil yapının korunması konusunda kolay, minimal invazif ve hızlı uygulama gibi birçok avantajı olduğunu göstermiştir. Bu yöntemin pediatrik distal anstabil radius kırıklarında güvenilir bir tedavi seçeneği olduğu açıktır.

**Anahtar Kelimeler:** Anstabil Radius Kırığı, İntramedüller Tespit, Pediatrik

### Introduction

Pediatric distal forearm fractures are common injuries and the vast majority of which are treated by closed reduction and casting (1). However, in displaced and angulated types, regular closed traction and manipulation technique may not be enough solely thus requiring operative treatment and most commonly stabilized by percutaneous Kirschner (K)-wires.

K-wire fixation has higher advantages in simplicity of placement, ease of removal and the limited risk of physal injury as regarding not to endanger the bone growth. In conventional pinning technique, K-wire is inserted just proximal or

through the distal radial physis and transfixed across the fracture site (2,3). However, correction of angulation via conventional pinning is somehow difficult because the entry point of crossed K-wires are very close to the fracture line where the marrow cavity is getting narrower in this area. Moreover, repeated insertion trials of K-wires could possibly cause iatrogenic fracture which makes the internal fixation harder. On the other hand, classical elastic stable intramedullary nailing (ESIN) technique which is also widely used in the treatment of pediatric forearm fractures, is mostly recommended in transverse fractures of the long bone diaphysis or those on the border of diametaphyseal junction. Stable reduction of the metaphyseal region with this technique is difficult because the distal segment is too short and wide which may not be reduced with the asymmetrical insertion of the nail entry in most of the cases (4-6).

Considering this facts, we looked for a solution which eliminates these problems. In our report, we would like to introduce and present the results of our distal transphyseal intramedullary fixation technique

Yusuf ERDEM ORCID No  
0000-0002-8685-2356  
Cagri NEYİSÇİ 0000-0001-8481-7808

Başvuru Tarihi / Received: 11.03.2019  
Kabul Tarihi / Accepted : 13.03.2019

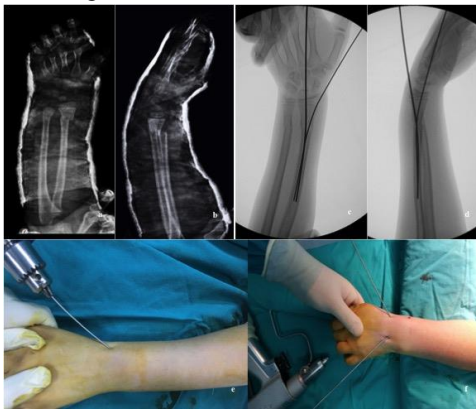
Adres / Correspondence : Yusuf ERDEM  
Gülhane Training and Research Hospital, Orthopedics and Traumatology  
Department, Ankara

e-posta / e-mail : dryusufoguzerdem@gmail.com

for severely displaced pediatric distal metaphyseal or metadiaphyseal radial fractures.

## Material and Method

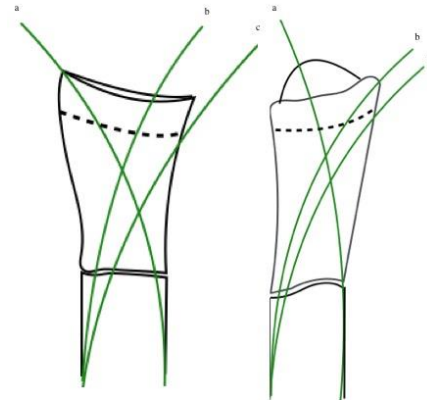
From January 2016 to June 2017, 6 patients (4 girls, 2 boys) with an average age of 8 years (range, 7-9) who has unstable distal radius fractures were included the study. Reduction with traction was applied as first line treatment as usual at the emergency department, however the desired anatomical reduction has not been achieved as expected. Surgical intervention was decided in all patients after an attempt of closed reduction in which the stable retention could not achieved. After receiving approval form our institutional review board, parents were informed and consented verbally that their children's data concerning the injuries, treatments and prognoses would be submitted for publication. 4 patients have metaphyseal, 2 patients have diaphyseal fractures without any comorbid fractures. 1.5 or 2 mm Kirshner wires were used percutaneously depending on the patient's physical sizes. First K-wire was inserted transepiphyseal into the medullary canal of the radius through the radial styloid prior to the second wire which was inserted through the end of the distal radial cortex, just located medial to Lister tubercle in 3 patients (Figure 1) and transepiphyseally at the same location in 3 patients (Figure 2).



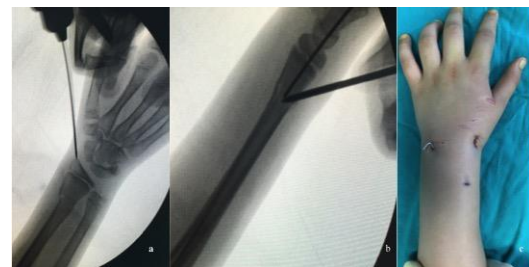**Figure 1.** Patient 1, a,b) a 7-year-old girl with a distal metaphyseal radius and ulna fracture in the left forearm which can not be reduced conservatively. c,d) The radius fracture was fixed by K-wire pinning in which one of the pin was inserted transepiphyseally while the other was inserted transcortically. e,f) The entry points of the wires outside the skin.

Just after K-wire insertion points were obtained, K-wires were reversed and the blunt end of the K-wires were pushed through the drilled holes by controlled handheld force. Intramedullary K-wires reduced the distal fragment to more anatomic position by the principle of leaning the opposite cortex of the proximal fragment. After confirmation of the stability and reduction by fluoroscopy, the distal ends of the K-wires were bent and cut to the proper length outside the skin. In case of difficulty

in proximal part reduction due to spike of the fracture site or soft tissues, reduction manoeuvre was achieved by the lever arm effect of Schanz, applied dorsally. Distal ulna fractures were aligned properly after the correction of radius fractures (Figure 3). At the end, below-the-elbow splint was applied to all patients for 3 weeks postoperatively. The patients and parents were taught about the wire site care. Patients were followed-up 1-3 and 6 weeks after discharge from the hospital, checking for the course of bone healing and complications.



**Figure 2.** K-wires were inserted through the radial styloid (a) and the posteromedial end (b) of the distal epiphysis in 3 patients and transcortically (c) in 3 patients. These wires reach the dorsal and volar cortex, respectively.

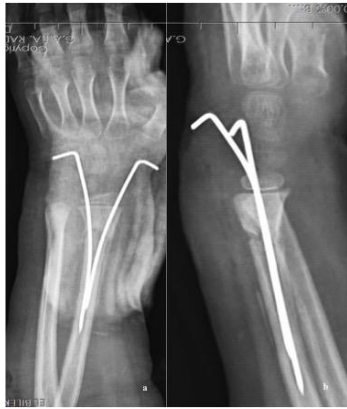

**Figure 3.** Patient 2, a) Intraoperative picture of the transphyseal entry point of the wire. b) Reduction was achieved by leveraging the proximal part with Schanz applied dorsally where the reduction of the proximal part can not be obtained. c) The distal ends of the wires were bent outside the skin.

## Results

The mean follow-up period was 13 months (range, 4-18 months). The operation was performed under general anaesthesia in all cases. The average operation time was 20 min (range, 15-25 min). Bone healing was observed at an average time of 4 weeks (range, 3-6 weeks) and K-wires were removed with local anaesthesia after 6 weeks in all patients (Table 1). On final radiographs just before K-wire removal, there was no translation or angulation in any direction and all patients achieved full wrist flexion, extension and forearm rotation. Moreover postoperative complications, such as refracture, loss of alignment, functional deficit of wrist and early

epiphyseal closure of the radius were not observed (Figure 4).



**Figure 4.** Patient 4, a,b) Complete bone union was achieved without malunion at postoperative 4th weeks.

**Table 1.** Patient summary

Patient	1	2	3	4	5	6
Age (years)	7	8	9	9	8	7
Sex	F	F	M	F	F	M
Follow-up (months)	18	16	16	15	10	4
Fracture type	RM	RM	RD	RM	RD	RM
Comorbidity	DU	DU	N	N	N	DU
Anesthesia	G	G	G	G	G	G
Surgery time (minutes)	20	25	25	20	15	15
K-wire diameter (mm)	15	15	20	15	15	20
K-wire removal (weeks)	6	6	6	6	6	6
Complication	N	N	MAPT	N	N	N

F: Female, M:Male, RM: Radius metaphysis, RD: Radius diametaphysis, DU: Distal ulna, G: General, MAPT: Minimal AP translation, N: Normal

## Discussion

Management of distal forearm fractures in pediatric population is challenging and more importance should be paid to pediatric fractures than adult fractures regarding treatment strategy. The important factors that need to be considered before selecting the appropriate treatment strategy are the age of child, duration of the healing time, and the initial position of the fracture site for the estimated remodeling potential and reintervention if required. Also parents' anxiety during the treatment should be taken into account.

The optimal treatment should include the maintenance of the reduction throughout the fracture healing period whether by surgery or conservative intervention. A 3-point moulded cast application may not be enough in unstable distal metaphyseal fractures, especially in the course of advanced swelling and displacement due to the nature of fracture mechanism. Most of the severely displaced

radius fractures are seen in Galeazzi-equivalent variants in pediatric population. High-velocity trauma may damage the distal ulna and radioulnar ligaments additionally in which the cast application alone as a definitive treatment may cause poor functional outcomes in the future (7).

Percutaneous K-wire pinning is recommended for severely and completely displaced fractures (8). Several K-wire pinning techniques have been described for distal radius fractures which challenges due to the presence of physis and the size of the bone (9,10). Kapandji (11) defined intrafocal pinning for physeal fractures of the distal radius to protect the growth plate from iatrogenic injury, however this technique may put adjacent neurovascular structures and ligaments at risk (9). Moreover ensuring the stable K-wire fixation with cross pinning without penetrating the physeal plate is technically demanding due to long distance to the fracture site which is also narrower site of the bone. Also difficulty of opposite cortex penetration of the bone at an optimal distance and the spread of the pins at the fracture site may not be sufficient to achieve the stability both in anteroposterior and lateral plans (2,12).

ESIN has been accepted as an option in case of such difficulties mentioned above (13-15). ESIN is generally used to stabilize the unstable diaphyseal and diametaphyseal fractures with high utilization rate, however three point stabilization cannot be provided in the distal metaphyseal fractures due to the short distal fragment (9,12). Varga et al. used short, double elastic nail fixation to eliminate the failure of the classical ESIN method, however the more rotational stability was achieved with thicker nails, and shorter nails (16).

Flexible double intramedullary K-wire pinning was successfully applied to distal metaphyseal and diametaphyseal radius fractures in our study, moreover comorbid ulna fractures in half of the patient population were managed conservatively which were considered incomplete and distal radioulnar stability was stable. We can explain this phenomenon with ligamentotaxis effect of ensuring sufficient fixation in more anatomical position at the fracture site. Our technique was similar to Py-Desmanet procedure (17,18), whereas our insertion point for the medial pin was located just at the end of the distal cortex of the radius, not at the tip of the posteromedial physis as described by Py-Desmanet's method. So the second pin in our study was not transphyseal, it was cortical. Moreover, the pins did not push forward to the radial head or physis, unlike the Py-Desmanet's technique. After drilling the insertion points, we reversed the K-wires and push the blunt tips of the K-wires by controlled handheld force intramedullary, so the possibility of the opposite cortex penetrating of the bone and the thermal injury of the physis were eliminated. This is considered as the last dissimilarity of our technique.

On the other hand, no need for skin incision, soft tissue dissection and further anaesthesia for nail removing unlike Varga et al.'s technique in which the implants were sank under the skin are considered as another advantages of our technique.

Intramedullary insertion of the K-wires maintained a spring effect where the distal fragment moved to reduced position in our technique. Our technique allowed a micromotion at the fracture site, which stimulates the formation of callus. In this technique we have observed only mild complications like skin irritations which were caused by the end of the dorsally inserted and relatively too short K-wires outside the skin. However, we hypothesize that this problem can be attributed to improper cut-off of K-wires during the learning curve period of the technique. When distal end of the K-wires is cut in a maximally palmar-flexed position of the wrist and left long outside the skin, this irritation problem ceases. Also minimal translation was observed in one case, however as long as the physes were open, remodelling occurred. Physeal arrest or growth disturbance was not observed in our patients, however in some studies a risk of premature physeal closure was reported after transphyseal pinning of the distal radius fractures (19,20).

In conclusion, intramedullary K-wire fixation technique is easy and a reliable for treatment of displaced distal radial fractures in pediatric population. Our follow-ups were relatively short, and further prospective and long-term studies are required to support our experience.

**Ethics Committee Approval:** Gülhane Military Medical Academy Local Ethics Committee Permission was obtained with the letter dated 2016 and numbered 17.

## References

1. Eichinger JK, Agochukwu U, Franklin J, Arrington ED, Bluman EM. A new reduction technique for completely displaced forearm and wrist fractures in children: a biomechanical assessment and 4-year clinical evaluation. *J Pediatr Orthop.* 2011;31(7):73-9.
2. Parikh SN, Jain VV, Youngquist J. Intrafocal pinning for distal radius metaphyseal fractures in children. *Orthopedics.* 2013;36(6):783-8.
3. Miller BS, Taylor B, Widmann RF, Bae DS, Snyder BD, Waters PM. Cast immobilization versus percutaneous pin fixation of displaced distal radius fractures in children: a prospective, randomized study. *J Pediatr Orthop.* 2005; 25:490-4.
4. Walton NP, Brammar TJ, Hutchinson J, et al. Treatment of unstable distal radial fractures by intrafocal, intramedullary K-wires. *Injury.* 2001;32:383-9.
5. Flisch CW, Della Santa DR. Osteosynthesis of distal radius fractures by flexible intramedullary nailing (Geneva experience). *Chir Main.* 1998;17:245-54.
6. Bukvić N, Marinović M, Bakota B, et al. Complications of ESIN osteosynthesis--Experience in 270 patients. *Injury.* 2015;46(6):40-3.
7. Letts M, Rowhani N. Galeazzi-equivalent injuries of the wrist in children. *J Pediatr Orthop.* 1993;13(5):561-6.
8. McLauchlan GJ, Cowan B, Annan IH, Robb JE. Management of completely displaced metaphyseal fractures of the distal radius in children. *J Bone Joint Surg.* 2002;84B:413-7.
9. Lieber J, Schmid E, Schmittenebecher PP. Unstable diaphyseal forearm fractures: transepiphyseal intramedullary Kirschner-wire fixation as a treatment option in children. *Eur J Pediatr Surg.* 2010; 20:395-8.
10. Miller BS, Taylor B, Widmann RF, Bae DS, Snyder BD, Waters PM. Cast immobilization versus percutaneous pin fixation of displaced distal radius fractures in children: a prospective, randomized study. *J Pediatr Orthop.* 2005; 25:490-4.
11. Kapandji A. Internal fixation by double intrafocal plate. Functional treatment of non articular fractures of the lower end of the radius. *Ann Chir.* 1976;30:903-8.
12. Sano K, Hashimoto T, Kimura K, Ozeki S. Percutaneous flexible double pinning (Py-Desmanet's procedure) for pediatric distal radius fractures. *Hand (N Y).* 2013;8(4):392-6.
13. Illing P, Lascombes P. Case collection of forearm fractures. In: Dietz HG, Schmittenebecher PP, Slongo T, Wilkins E, editors. *Elastic stable intramedullary nailing (ESIN) in children (AO manual of fracture management series).* New York: Thieme; 2006: 71-108.
14. Cai H, Wang Z, Cai H. Prebending of a titanium elastic intramedullary nail in the treatment of distal radius fractures in children. *Int Surg.* 2014;99:269-75.
15. Joulié S, Laville JM, Salmeron F. Posteromedial elastic stable intra-medullary nailing (ESIN) in volarly displaced metaphyseal-diaphyseal distal radius fractures in child. *Orthop Traumatol Surg Res.* 2011;97:330-4.
16. Varga M, Józsa G, Fadgyas B, Kassai T, Renner A. Short, double elastic nailing of severely displaced distal pediatric radial fractures: A new method for stable fixation. *Medicine (Baltimore).* 2017;96(14):e6532.
17. Desmanet E. Osteosynthesis of the radius by double elastic springpinning. Functional treatment of the distal end fracture of the radius. A study of 130 cases. *Ann ChirMain.* 1989;8:193-206.
18. Py C, Churet JP. Tentative de mobilisation immediate des fractures de l'extrémité inférieure de radius. Personal communication, Tours and Western Center Surgical Society Meeting, 18 June, 1969.
19. Abzug JM, Little K, Kozin SH. Physeal arrest of the distal radius. *J Am Acad Orthop Surg.* 2014;22:381-9.
20. Boyden EM, Peterson HA. Partial premature closure of the distal radial physis associated with Kirschner wire fixation. *Orthopedic.* 1991;14:585-8.