

Tam Tıkalı Ana İliak Arterin; İyonize Kontrast Madde Kullanmaksızın CO₂'i Kontrast Ajan Olarak Kullanarak Endovasküler Yönetimle Tedavisi

Endovascular Treatment of Totally Occluded Main Iliac Artery Using CO₂ without Iodinated Contrast Medium

Mahmut Tuna KATIRCIBAŞI¹, Uğur ÖZKAN²

¹ Prof. Dr. Kahramanmaraş Sütçü İmam University Faculty of Medicine, Department of Cardiology, KAHRAMANMARAŞ

² Ass. Prof. Dr. Private Ortadoğu Hospital, Department of Radiology, ADANA

Özet

Periferik arter hastaları arasında; kronik böbrek hastalığı yaygın olarak görülür. Güncel kılavuzlar bu hastalarda endovasküler tedavi yöntemlerini ilk tedavi seçeneği olarak önermektedir. Kontrastın indüklediği nefropati önceden kronik renal hastalığı, kalp yetersizliği olan veya işlem öncesi dehidrate kalan hastalarda oldukça yaygın olarak görünür ve bu durum hastanede yatış süresini ve mortaliteyi artırmaktadır. Bu tür hastalarda CO₂ alternatif bir kontrast ajan olarak kullanılabilir ve diğer gazlardan farklı olarak hemen hemen tamamı hızlı bir şekilde absorbe edilir. Bu vaka bildirisinde kronik böbrek hastalığı (glomerular filtration rate of 24 ml/min/1.77 m²) olan sol ana iliak arteri tam tıkalı bir hastada; kontrast ajan olarak CO₂ in kullanıldığı bir vaka bildirilmiştir.

Anahtar Kelimeler: CO₂, kontrast ajan

Abstract

Chronic kidney disease is a common comorbidity in patients with peripheral artery disease (PAD). Current guidelines recommend an “endovascular first” strategy in cases where for revascularization is indicated Contrast-induced nephropathy (CIN) is a particularly common complication in patients with pre-existing chronic renal disease, diabetes, heart failure, and dehydration which is associated with increased time in hospital and long-term mortality Carbon dioxide (CO₂) gas can be used as an alternative contrast agent, as it is absorbed almost instantaneously as opposed to other gases. In this report, we describe a case of percutaneous transluminal angioplasty of an occluded left main iliac artery using CO₂ as contrast medium due to the presence of severe chronic kidney disease (glomerular filtration rate of 24 ml/min/1.77 m²).

Key Words: CO₂, contrast medium

INTRODUCTION

Chronic kidney disease is a common comorbidity in patients with peripheral artery disease (PAD). Current guidelines recommend an “endovascular first” strategy in cases where for revascularization is indicated (1). Contrast-induced nephropathy (CIN) is a particularly common complication in patients with pre-existing chronic renal disease, diabetes, heart failure, and dehydration which is associated with increased time inhospital and long-term mortality (2, 3). Instead of conventional nephrotoxic contrast medium, carbon dioxide (CO₂) gas can be used as an alternative contrast agent, as it is absorbed almost instantaneously as opposed to other gases (4).

In this report, we describe a case of percutaneous transluminal angioplasty of an occluded left main iliac artery using CO₂ as contrast medium due to the presence of severe chronic kidney disease (glomerular filtration rate of 24 ml/min/1.77 m²). This complex procedure required double vascular access through the antegrade main femoral artery, which was performed successfully despite the lack of aniodinated contrast medium.

CASE REPORT

An 83 year old male patient who presented with a clinical history of hypertension, diabetes mellitus, chronic

kidney disease without hemodialysis (Cr 2.9 mg/dl), and smoking dyslipidemia was referred to our hospital due to an open sore on left foot toes. In spite of optimal antibiotic medication according to microbiological and anti-biogramtests, the wound was gowned and opened.

A clinical decision was made to perform conventional peripheral angiography for both legs following Doppler examination. Peripheral angiography was performed by using CO₂ as a contrast agent due to the chronic renal failure disease (Figure 1). Carbon dioxide was injected via a similar type of catheter as the one which is used for conventional contrast agent.

Briefly, the gas was passed through a pressure-lowering valve (1.3atm) via a 3-way valve into a non-special 50-mL syringe in which the piston could be fixed to accommodate a certain volume and hold the supra-atmospheric pressure. By turning the 3-way valve in a second position, the syringe containing pressurized CO₂ gas was connected to the intra-arterial catheter. This allowed the gas to expand and passively flow through the intra-arterial catheter in the arterial lumen. Images were taken by digital subtraction angiography (DSA).

During the process, 6F and 7F sheaths were placed both main femoral arteries by antegrade puncture.

İletişim: Dr. M. Tuna Katırcıbaşı, KSÜ Tıp Fakültesi Kardiyoloji AD, Kahramanmaraş

DOI: 10.17517/ksutfd.314305

Tel : 0 532 522 11 89

E-Posta : doktortuna@gmail.com

Geliş Tarihi : 17.05.2017

Kabul Tarihi : 25.09.2017

Figure 1

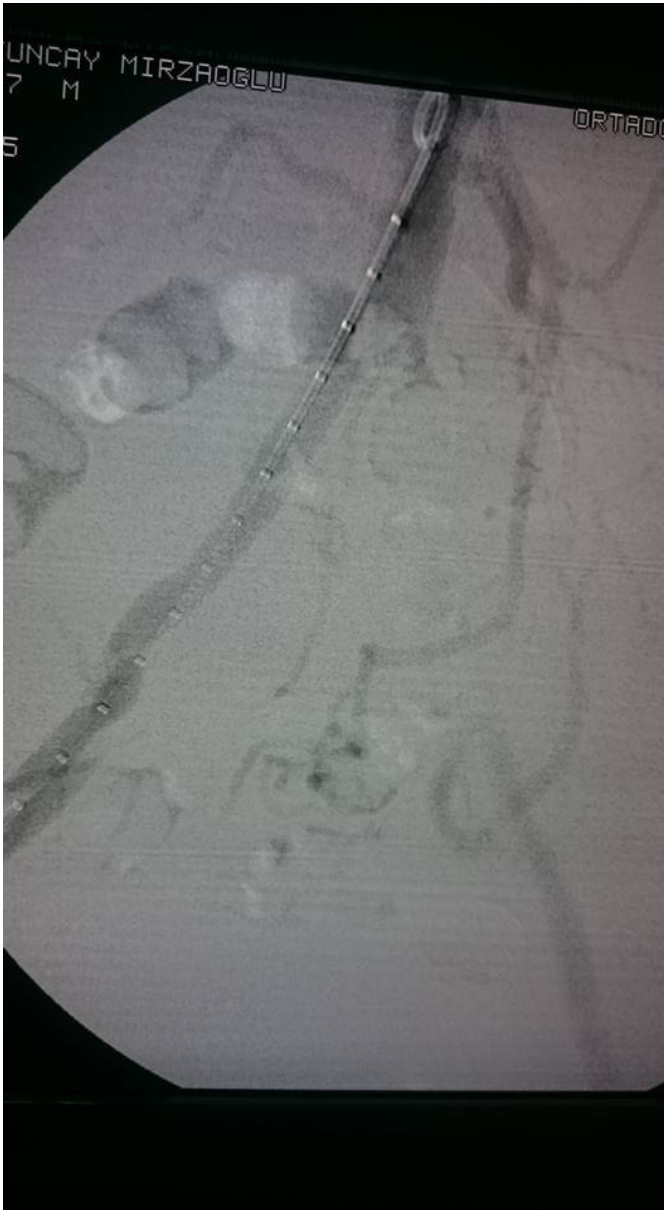
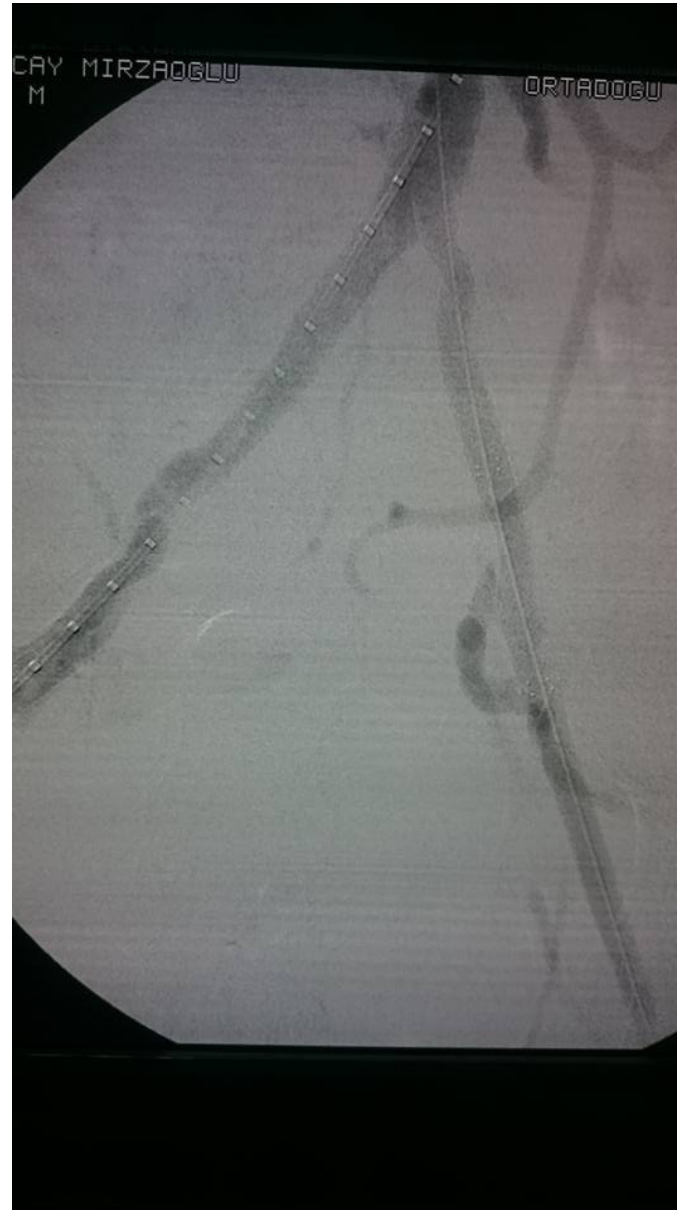


Figure 2



Predilatation was performed on the left common iliac artery with a 5mm balloon after passing a left common iliac artery occlusion by an antegrade approach. Since the transition was subintimal, a 9x59 mm balloon expandible stent graft was placed on the left common iliac artery to prevent rupture. After, the artery was dilated with a 8mm balloon by placing a stent with the size of 8x40mm to external iliac artery stenosis. A control angiograph indicated that blood flow was ideal (Figure 2).

DISCUSSION

This report documents the results of angiography and subsequent stent implantation using CO₂ in a patient with a history of chronic kidney disease. Although images made by the infusion of CO₂ alone are not necessarily sufficient for optimal visualization, much progress has been made in the quality of the images by digital subtraction angiography (DSA), which enabled us to perform a diagnostic angiography in PAD patients with contraindication to iodinated contrast medium as in this particular case study. Furthermore, the images by

CO₂ DSA enabled us to perform endovascular therapy in the iliac and infra-inguinal peripheral arteries.

The main benefit of CO₂ as a contrast agent is the lack of renal toxicity and anaphylactic response. Therefore, it is the preferred alternative contrast agent in patients with renal failure and contrast allergies in this case study. Since CO₂ is eliminated by the lungs in a single pass, unlimited volumes of CO₂ can be used; however, injections should be separated by 2 to 3 minutes. The other advantage of CO₂ stems from its low viscosity. CO₂ can be injected through a micro-catheter with the inner diameter of 0.021inch (0.533 mm), thinneedles (21 g to 25 g), between the catheter and guide wire, and through the side port of the sheath and stent delivery system. The other important advantage of using CO₂ is that it is a safe and effective flushing medium for the catheter and sheath. Because CO₂ is immiscible with blood, it can prevent clots developing in the catheter. During the angiographic and endovascular procedures, 50 mL of CO₂ is injected into the catheter every 2-3 minutes. As a cost benefit, CO₂ is inexpensive in comparison with nonionic iodinated contrast medium.

There are several limitations with CO₂ angiography. CO₂ requires a special delivery system to prevent air contamination and gas compression. CO₂ should not be used as a contrast agent for imaging the coronary artery or the cerebral circulation because of its potential neurotoxicity and likelihood of on coronary artery gas embolism causing myocardial ischemia (6-7). The intracoronary CO₂ injection has a profound effect on the left ventricular function in swine (7). Potential image degradation presents a problem with CO₂ use. Since CO₂ is a negative contrast agent imaged using the DSA technique, bowel gas, peristalsis, and other motion degrade CO₂ imaging. The buoyancy of CO₂ causes incomplete filling of the vessels dependent upon vessel size and the location of area of interest. In addition, the renal artery coursing posterior to the aorta may not fill with injected CO₂ within the aorta.

This case report underscores the value of CO₂ as an alternative contrast agent that can be used routinely to lower contrast volume and prevent CIN during peripheral vascular procedures in patients with PAD. New developments with computer software and imaging techniques will likely further improve results of CO₂ arteriography and as CO₂ is a cost-effective contrast agent, the benefits of CO₂ arteriography in patients with peripheral vascular disease are significant.

REFERENCES

1. Tendera M, Aboyans V, Bartelink ML, Baumgartner I, Clément D, Collet JP, et al. ESC Guidelines on the diagnosis and treatment of peripheral artery diseases: Document covering atherosclerotic disease of extracranial carotid and vertebral, mesenteric, renal, upper and lower extremity arteries: the Task Force on the Diagnosis and Treatment of Peripheral Artery Diseases of the European Society of Cardiology (ESC). *Eur Heart J* 2011; 32: 2851-2906
2. Katsiki N, Athyros VG, Karagiannis A, Mikhailidis DP. Contrast-induced Nephropathy: An “All or None” Phenomenon? *Angiology* 2014; 66: 508-513.
3. Maioli M, Toso A, Leoncini M, Gallopin M, Musilli N, Bellandi F. Persistent renal damage after contrast-induced acute kidney injury: incidence, evolution, risk factors, and prognosis. *Circulation* 2012; 125: 3099-3107.
4. Moos JM, Ham SW, Han SM, Lew WK, Hua HT, Hood DB et al. Safety of carbon dioxide digital subtraction angiography *Arch Surg* 2011; 146: 1428-1432.
5. Beese RC, Bees NR, Belli AM. Renal angiography using carbon dioxide. *Br J Radiol* 2000 Jan. 73(865):3-6
6. Moresco KP, Patel N, Johnson MS, Trobridge D, Bergan KA, Lalka SG. Accuracy of CO₂ angiography in vessel diameter assessment: a comparative study of CO₂ versus iodinated contrast material in an aortoiliac flow model. *J Vasc Interv Radiol* 2000; 11: 437-444.
7. Diaz LP, Pabon IP, Garcia JA, de la Cal Lopez MA. Assessment of CO₂ arteriography in arterial occlusive disease of the lower extremities. *J Vasc Interv Radiol* 2000; 11: 163-169.