

RUPTURED CORNUAL HETEROTOPIC PREGNANCY AFTER IN VITRO FERTILIZATION AND EMBRYO TRANSFER: A CASE REPORT

IN VITRO FERTİLİZASYON VE EMBRYO TRANSFERİ SONRASI RUPTURE KORNUAL HETEROTOPIK GEBELİK: BİR OLGU SUNUMU

Barış BÜKE¹, Hasan Onur TOPÇU², Deniz ŞİMŞEK¹, Mert KAZANDI¹

¹Ege University, Department of Obstetrics and Gynecology İzmir, Turkey

²Zekai Tahir Burak Women's Health Education and Research Hospital, Ankara

Geliş Tarihi: 18.10.2013 Kabul Tarihi: 13.10.2013

Abstract

Heterotopic pregnancy, characterized by the condition of coexisting intrauterine and extrauterine pregnancy, until recently, was considered to be a rare event occurring once in every 30000 cases. Herein, we report a case of ruptured cornual pregnancy, coexisting intrauterine pregnancy, diagnosed during 11th week of in vitro fertilization (IVF) pregnancy who was on hemorrhagic shock and successfully managed by cornual repairment and salpingectomy.

Key words: In vitro fertilization, cornual heteropic pregnancy embryo transfer

Özet

Heterotopik gebelik, 30 000 vakada bir görülen, ekstrauterin gebeliğin intrauterine gebeliğe eşlik ettiği nadir görülen bir durumdur. Olgumuzda, ruptüre kornual gebeliğe, intrauterine gebelik eşlik etmektedir. Heterotopik gebelik tanısı, 11.gebelik haftasında ve hemorojik şok tablosunda iken konulmuştur. Tedavisi salfenjektomi ve kornual onarımla başarı ile yapılmıştır.

Anahtar kelimeler: İn vitro fertilizasyon, kornual heterotopik gebelik embryo transferi

Heterotopic pregnancy, characterized by the condition of coexisting intrauterine and extrauterine pregnancy, until recently, was considered to be a rare event occurring once in every 30000 cases [1]. It occurs most often 1-3% after assisted reproduction technology (ART) and previous pelvic inflammatory disease (1, 2). Risk factors for development of interstitial pregnancy include previous ectopic pregnancy, previous salpingectomy, uterine anomalies, ipsilateral salpingectomy, ART therapy, ovulation induction, and sexually transmitted infections [3-5].

As the pregnancy grows in the area of the fallopian tube that enters the uterus, surrounding myometrial tissue allows for further development of the pregnancy into the second trimester. Rupture of such an advanced gestation may result in catastrophic hemorrhage, with a mortality rate of up to 2% [3-5]. Diagnosis of interstitial pregnancies relies heavily on ultrasound and potentially on laparoscopic evaluation[6]. Ultrasound frequently shows a thin rim of myometrial tissue surrounding the ectopic pregnancy sac.[7]. The diagnosis of heterotopic cornual pregnancy is difficult and rupture is a frequent mode of revelation.

We report a case of ruptured heterotopic cornual pregnancy, diagnosed during 11th week of in vitro fertilization (IVF) pregnancy admitted to hospital with hemorrhagic shock and successfully managed by cornual repairment and salpingectomy.

Case

A 30-year-old nulliparous woman presented to our emergency unit with severe abdominal pain and hemodynamic instability. The blood pressure was 75/40 mmHg with a weak and rapid pulse rate of 130 beat per minute. Abdominal examination revealed acute abdomen with severe tenderness, guarding and rigidity. Abdominal ultrasonography demonstrated massive intraperitoneal fluid and a normal-looking intra uterine pregnancy with a positive fetal heart rate, and an interstitial pregnancy with a positive fetal heart rate.

An emergency exploratory laparotomy with midline incision was performed under general anesthesia, leading to a finding of source of bleeding. Approximately 2000 cc of blood was evacuated from peritoneal cavity (Figure 1). On the right cornual part of the uterus, there was a site at about 1cm in diameter. The myometrium was too thin and fragile. With an incision to interstitial area, a fetus with 2.5 cm length was removed (Figure 2). After removing the fetus, fetoplacental remnants were removed by sharp curette. Cornual area was sutured with baseball method. Some areas were bleeding from the tuba but before fixing the tuba, we checked the cardiac activity of the intrauterine fetus. It was still alive but it had bradycardia. After salpingectomy was done we checked the cardiac activity of the intrauterine fetus. As there was no heartbeat, vacuum aspiration was performed for the intrauterine pregnancy. After aspiration, uterine cavity was checked again with ultrasonography.

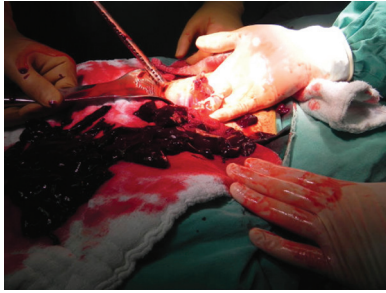

Figure 1: Ruptured cornual pregnancy with 11 weeks of gestation.

Intraoperative hemoglobin was 5mg/dl and hematocrit value was 14% 4 units red blood cells were transfused. Admission serum beta-human chorionic gonadotropin (beta-hCG) was 13496 IU/ml and serum beta-hCG levels progressively decreased after the operation.

Discussion

Heterotopic pregnancy (co-existence of intrauterine and ectopic pregnancies) is a rare event and its incidence is 1 in 30,000 [1]. However, with the increased use of ART, the incidence has expectedly risen to 1 in 100 pregnancies [8]. Previous tubal damage, ectopic pregnancy and assisted reproduction technique are risk factors for heterotopic pregnancy [8, 9].

Tal et al. [9] reported that 70% of the heterotopic pregnancies were diagnosed between 5 and 8 weeks of gestation, 20% between 9 and 10 weeks of gestation and only 10% after the 11 weeks of gestation. Our case was diagnosed when the ectopic pregnancy was ruptured at 11 weeks of gestation.

The early diagnosis of heterotopic pregnancy is often difficult due to non-specific clinical symptoms. Abdominal pain, adnexal mass, peritoneal irritation and an enlarged uterus were defined as four common presenting signs and symptoms, in the literature [10].

The recent advances in transvaginal sonography (TVS) helped in the early diagnosis of heterotopic pregnancy. TVS is an invaluable instrument on the diagnosis of heterotopic pregnancy. The typical image of a heterotopic pregnancy on ultrasound examination is the presence of an IU gestation coexisting with an ectopic cornual pregnancy containing an embryo [11]. The traditional treatment of interstitial pregnancy has been cornual resection or hysterectomy in the cases with severely damaged uteri [6].

In our case; we restored the damaged area primarily without resection. Another treatment modality for interstitial pregnancy could be methotrexate therapy. But there is no established treatment scheme of methotrexate therapy for the treatment of interstitial pregnancies. And also, similar with our case, in ruptured heterotopic interstitial pregnancies this mode of therapy cannot be a choice of treatment [12]. Herein we reported a case of ruptured heterotopic interstitial pregnancy in the state of hypovolemic shock necessitating emergent laparotomy [13]. Conservative management was not available for this case but in hemodynamically stable patients conservative management should be considered as the preferred treatment, especially in cases desiring fertility.

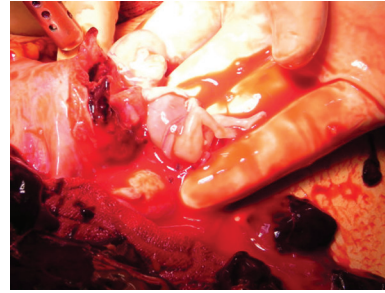


Figure 2: View of the ruptured cornual pregnancy.

References

1. Duce, M.N., et al., Heterotopic pregnancy: case report. *Abdom Imaging* 2002. 27(6): 677-9.
2. Fernandez, H. and A. Gervaise, Ectopic pregnancies after infertility treatment: modern diagnosis and therapeutic strategy. *Hum Reprod Update* 2004. 10(6): 503-13.
3. Tulandi, T. and D. Al-Jaroudi, Interstitial pregnancy: results generated from the Society of Reproductive Surgeons Registry. *Obstet Gynecol* 2004. 103(1): 47-50.
4. Rock J, T.J., *Telinde's Operative Gynecology*. 2003, 9th ed. Philadelphia, PA: Lippincott-Raven. .
5. Lau, S. and T. Tulandi, Conservative medical and surgical management of interstitial ectopic pregnancy. *Fertil Steril* 1999. 72(2): 207-15.
6. Katz, D.L., et al., Combined hysteroscopy and laparoscopy in the treatment of interstitial pregnancy. *Am J Obstet Gynecol* 2003. 188(4): 1113-4.
7. Advincula, A.P. and S. Senapati, Interstitial pregnancy. *Fertil Steril* 2004. 82(6): 1660-1.
8. Luo, X., et al., Heterotopic pregnancy following in vitro fertilization and embryo transfer: 12 cases report. *Arch Gynecol Obstet* 2009. 280(2): 325-9.
9. Tal, J., et al., Heterotopic pregnancy after ovulation induction and assisted reproductive technologies: a literature review from 1971 to 1993. *Fertil Steril* 1996. 66(1): 1-12.
10. Reece, E.A., et al., Combined intrauterine and extrauterine gestations: a review. *Am J Obstet Gynecol* 1983. 146(3): 323-30.
11. Poujade, O., G. Ducarme, and D. Luton, Cornual heterotopic pregnancy: a case report. *J Med Case Rep* 2009. 3: 7233.
12. Fisch, J.D., et al., Medical management of interstitial ectopic pregnancy: a case report and literature review. *Hum Reprod* 1998. 13(7): 1981-6.
13. Chen, C.L., et al., Successful conservative treatment for advanced interstitial pregnancy. A case report. *J Reprod Med* 2002. 47(5): 424-6.

Corresponding Author

Dr Hasan Onur Topçu, M.D. dronurtopcu@gmail.com
Dr.Zekai Tahir Burak Women Health Education and Research Hospital, Ankara, Turkey