

Fine-Needle Aspiration Cytology of Malignant Fibrous Histiocytoma (Giant Cell Type) in an Angora Cat

Nihat YUMUSAK^{1*}, Murat CALISKAN², Osman KUTSAL³

¹Harran University, Faculty of Veterinary Medicine, Department of Pathology, Sanliurfa, Turkey.

²Ankara University, Faculty of Veterinary Medicine, Department of Surgery, Ankara, Turkey.

³Ankara University, Faculty of Veterinary Medicine, Department of Pathology, Ankara, Turkey.

Geliş Tarihi: 01.12.2017

Kabul Tarihi: 26.05.2018

Abstract: This case study presents the radiological, cytopathological and histopathological description of the giant cell type of a malignant fibrous histiocytoma on the back of a 9-year-old female Angora cat. Latero-lateral and ventro-dorsal thoracic radiographs was taken to evaluate invasion. Radiologically the mass was invasive but had not invaded the bone. Under general anaesthesia, cytopathological samples were taken from the tumour, using the Fine-Needle Aspiration Cytology (FNAC) technique, and were later stained with May-Grünwald Giemsa solution. The surgically extracted biopsy sample was subjected to routine tissue processing and stained with Haematoxylin-Eosin (HE). The biopsy material was 8x6x6 cm and 95 g, was covered by skin, multilobular appearance and hard consistency. Cross-sections was greyish white and necrotic appearance. Cytopathological examination revealed the presence of numerous histiocyte- or fibrocyte-like cells of anaplastic character and pleomorphic shape, which were associated with giant cells with multiple nuclei and a broad and vacuolar cytoplasm. Histological examination demonstrated the presence of histiocyte-like atypical cells arranged in the form of swirls and extending in various directions, or numerous giant cells with 8 to 12 nuclei and a broad cytoplasm situated in between connective tissue cells.

Keywords: Cat, Cytology, Radiology, Histopathology, Malignant fibrous histiocytoma.

Bir Ankara Kedisi'nde Malign Fibröz Histiositomun (Dev Hücreli Tip) İnce İğne Aspirasyon Sitolojisi

Özet: Bu olguda, 9 yaşlı, Ankara ırkı, dişi bir kedinin sırtında radyolojik, sitopatolojik ve histopatolojik olarak dev hücreli malign fibröz histiositoma olgusu tanımlandı. Latero-lateral ve ventro-dorsal olarak tümöral kitlenin invazyonu radyolojik olarak belirlendi. Radyolojik incelemede kitle invaziv görüntüde olup kemiğe bağlantısı yoktu. Genel anestezi altında tümöral bölgeden İnce İğne Aspirasyon Sitolojisi (İİAS) tekniğine göre sitopatolojik örnekler alınarak May-Grunwald Giemsa yöntemine göre boyandı. Cerrahi operasyonla uzaklaştırılan biyopsi örneği ise rutin doku takibine alınarak hematoksilen eosin (HE) ile boyandı. Biyopsi materyali 8x6x6 cm ve 95 gr ağırlığında, deriyle kaplı, multilobuler yapıda ve sert kıvamlıydı. Kesit yüzü gri beyaz ve nekrotik manzaradaydı. Sitopatolojik incelemelerde anaplazik özelliklerde, pleomorfik şekilli histiosit benzeri yada fibrosit benzeri çok sayıda hücreyle beraber, geniş ve vakuoler sitoplazmalı, çok çekirdekli dev hücreleri dikkati çekti. Histolojik incelemelerde ise, çeşitli yönlere girdaplar şeklinde dizilim yapmış atipik özellikler gösteren histiosit benzeri veya bağ dokusu hücrelerinin aralarında, çok sayıda, geniş sitoplazmalı, 8-12 çekirdekli dev hücreleri fark edildi.

Anahtar Kelimeler: Kedi, Sitoloji, Radyoloji, Histopatoloji, Malign fibröz histiositom.

Introduction

While the giant cell type of malignant fibrous histiocytoma is frequently encountered in humans, it is uncommon in domestic animals. This tumour is generally observed in the dog, pig and horse and is localized to the skin, lungs, spleen, joints and deep connective tissue (Ford et al., 1975; Gleiser et al., 1979; Meuten, 2002). In cats, this tumour is also referred to as the malignant tumour of the soft tissues, and is categorized into four groups, including the fibrous, mixoid, inflammatory and giant cell types (Meuten, 2002). In this case study, giant cell type of a malignant fibrous histiocytoma in an Angora cat was investigated by the

radiologically, cytopathologically and histopathologically examinations.

Case History

A 9-year-old female Angora cat, with a swelling on the back measuring 8x6x6 cm in size, constituted the material of this case study. On radiological examination, a solid tumoral mass was detected in the interscapular region. Latero-lateral and ventro-dorsal thoracic radiographs was taken to evaluate tumoral invasion. For the purpose of early diagnosis, cytopathological samples were taken

from the animal using the FNAC technique, under general anaesthesia. Smears were prepared from these samples, and were air-dried and stained with May-Grünwald Giemsa solution. Subsequently, the biopsy samples obtained by surgery were fixed in 10% formaldehyde solution for pathological examination. The fixed tissues were dehydrated by passage through a graded series of alcohol and xylol, and blocked in paraffin. Five-micron-thick sections were cut from the paraffin blocks and stained with haematoxylin-eosin (HxE).

Radiological examination showed that radio opaque and radiolucent mass had infiltrated into the deeper layers, but had not invaded the bone tissue (Figure 1). Macroscopically, the biopsy material, which weighed 95 g and measured 8x6x6 cm, was covered by skin and had a lobular appearance and hard consistency. It was determined that the mass was not solid, but had a lobular appearance (Figures 2A, 2B). Cross-sections presented with a greyish white colour and a necrotic appearance with patches of haemorrhage. Furthermore, the cytopathological examination of the preparations revealed the presence of atypical, large and polymorphic histiocyte-like cells associated with many atypical spindle-shaped fibroblast-like cells. In these areas, many giant cells with a rather broad vacuolar cytoplasm and 8-12

nuclei were also observed (Figure 2C). Histopathologically, broad areas of loose stroma containing atypical histiocyte-like or connective tissue-like cells, which were arranged in the form of swirls and extended in various directions, were detected. These structures were associated with many giant cells characterized by a broad cytoplasm and 8-12 nuclei as well as with many atypical mitotic figures (Figure 2D). Broad areas of connective tissue and stroma were hyalinized and necrotic.

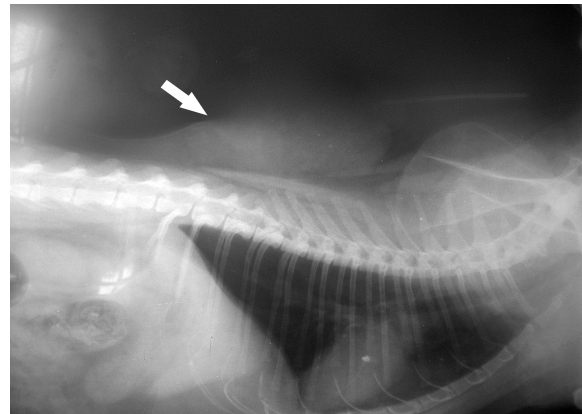


Figure 1. Radiological view of the mass on the back of the cat.

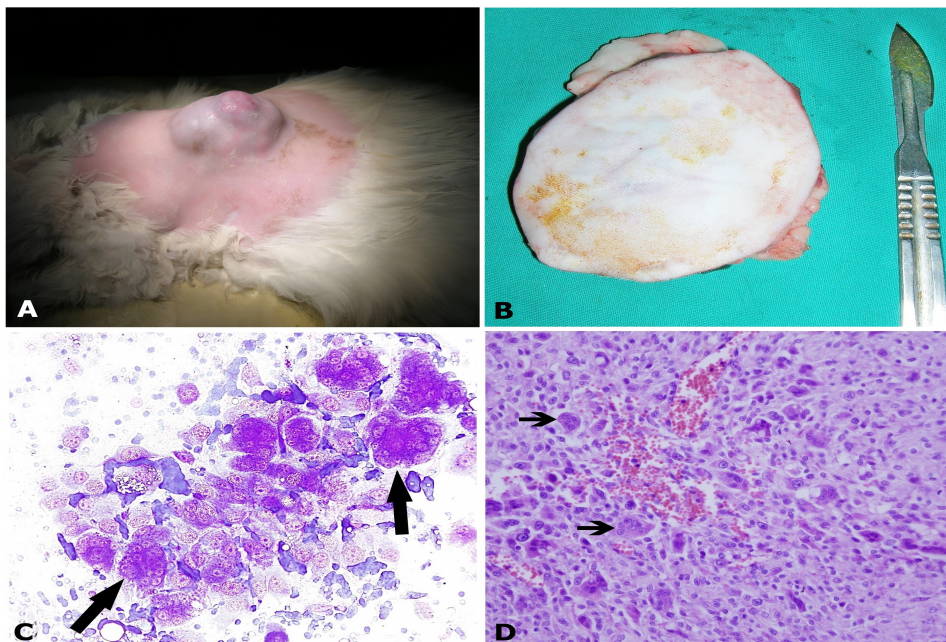


Figure 2. A) Macroscopic view of the swelling on the back of the cat. B) Postoperative view of the mass. C) Atypical histiocytic and multinuclear cells (arrows), X20 objective, MGG. D) Atypical histiocytic and multinuclear cells, spindle-shaped arrangement (arrows), X10 objective, HxE.

Discussion and Conclusion

Although the histogenic structure of malignant fibrous histiocytomas remains unclear, these tumours are considered to be of mesenchymal

origin (Goldschmidt and Shofer, 1992; Morris et al., 2002). In an immunohistochemical study, Aydın et al. (2003) reported the tumour cells to have reacted positively for anti-vimentin and anti-SMA antibodies. To differential diagnosis of this tumor from metastatic tumors, osteosarcoma and

fibrosarcoma are radiological and histological techniques (Bullough, 1997; Enneking, 1990). But there are no specific findings of radiology. In this case, radiologically radio opaque and radiolucent mass were seen and had infiltrated but not invaded the bone tissue. The cytopathological findings obtained pointed to features of a mesenchymal tumour. The malignant fibrous histiocytomas has a nodular, multinodular and firm macroscopic appearance. Cut surfaces of tumors has non specific appearance such as necrosis, not encapsulated and with pale white color (Datarkar and Hazare, 2009; Kiran et al., 2005; Turk, 2010). The macroscopic findings determined in this case study were found to be in parallel with those reported in previous case studies. However, as the location of the tumour was in a region where mostly vaccine site-associated sarcomas are located, a similarity to those tumours was detected. The tumor contains histiocyte like cells in varying proportions and numerous large multinucleated tumor giant cells. The neoplastic histiocytes were collagen production. Fibrosis may extensive and hyalinized. (Al-Agha and Igbokwe, 2008; Datarkar and Hazare, 2009; Gokce et al. 2008). Vaccine site-associated sarcomas mostly originate from fibrocytes and fibroblasts, and present with a limited number of giant cell formations (Goldschmidt and Shofer, 1992; Meuten, 2002). Histopathologically these tumors have five subtypes which storiform pleomorphic, myxoid, giant cell, inflammatory and angiomatoid (Pobirci et al. 2011). In this case giant cell type of malignant fibrous histiocytomas was diagnosed histopathological. Histopathologically it was observed that the tumour contained a large number of giant cells with 8-12 nuclei and that the tumour cells were histiocyte-like. Malignant fibrous histiocytomas generally have a superficial location, are in the form of small masses, and can be easily removed by surgery (Guccion and Enzinger, 1972; Hamir, 1989; Kiran et al., 2005). In contrast to available literature reports, the tumour in this case study was observed to have infiltrated into the deeper layers. Cytopathological diagnosis is not only rapid and inexpensive, but is also easily applicable and reliable when used for the early diagnosis of superficial lesions (Wellman, 1990). The comparison of the evaluation results of the cytopathological samples taken in the preoperative period for early diagnosis and the histopathological findings confirmed that the cytopathological and histopathological diagnoses were consistent.

In conclusion, cytopathological findings were found to be useful in the early diagnosis of

malignant fibrous histiocytoma. Furthermore, in view of the location of the tumour and the subject being an Angora cat indigenous to Turkey, this case study is considered to contribute to future studies on this subject and to the clinical approaches of veterinary practitioners.

References

- Aydın Y, Vural SA, Öznur N, 2003: Bir kedide dev hücreli malign fibröz histiyositom. *Ankara Üniv Vet Fak Derg*, 50, 247-249.
- Bullough PG, 1997: Orthopaedic Pathology, 3rd edition, Time Mirror International Publishers Ltd., London.
- Datarkar A, Hazare VK, 2009: Malignant fibrous histiocytoma: a case report. *J Maxillofac Oral Surg*, 8, 196-198.
- Enneking WF, 1990: Clinical musculoskeletal pathology, 3rd revised edition, University of Florida Press/J. Hillis Miller Health Science Center, Gainesville, Florida, 1990.
- Ford GH, Empson RN, Plopper CG, Brown PH, 1975: Giant cell tumor of soft parts: A report of an equine and a feline case. *Vet Pathol*, 12, 428-433.
- Gleiser CA, Raulston GL, Jardine JH, Gray KN, 1979: Malignant fibrous histiocytoma in dogs and cats. *Vet Pathol*, 16, 199-208.
- Goldschmidt MH, Shofer FS, 1992: Skin Tumors of the Dog and Cat. Pergamon Press, Oxford, 175-178.
- Guccion, JG, Enzinger, FM, 1972: Malignant giant cell tumor of soft parts: an analysis of 32 cases. *Cancer*, 29, 1518-1528.
- Hamir AN, 1989: Equine giant cell tumor of soft tissues. *Cornell Vet*, 2, 173-177.
- Kiran MM, Karaman M, Hatipoglu F, Koc Y, 2005: Malignant fibrous histiocytoma in a dog: a case report. *Vet Med Czech*, 50, 553-557.
- Meuten DJ, 2002: Tumors in Domestic Animals. 233-237. In: DJ Meuten (ed), 4th ed. Iowa.
- Morris JS, Mcinnes EF, Bostock DE, Hoather TM, Dobson JM, 2002: Immunohistochemical and histopathologic features of 14 malignant fibrous histiocytomas from Flat-Coated Retrievers. *Vet Path*, 39, 473-479.
- Pobirci DD, Bogdan FL, Pobirci OANA, Petcu CA, Rosca ELENA, 2011: Study of malignant fibrous histiocytoma: clinical, statistic and histopatological interrelation. *Rom J Morphol Embryol*, 52, 385-388.
- Turk NS, Kelten C, Ozdemir NO, Duzcan E, 2010: Primary malignant fibrous histiocytoma of the kidney: Report of a case. *Turk J Urol*, 26, 165-167.
- Wellman ML, 1990: The cytologic diagnosis of neoplasia. *Vet Clin North Am Small Anim Prac*, 20, 919-937.

***Corresponding Author:** Nihat Yumusak

Harran University, Faculty of Veterinary Medicine
Department of Pathology, 63000, Sanliurfa-Turkey
e-mail: nihatyumusak@harran.edu.tr