

Mucocele Of The Appendix: A Rare Clinical Entity, Case Report And Review Of Literature

Apandiks'in Mukoseli: Nadir Bir Klinik Durum, Olgu Sunumu ve Literatür Derlemesi

Oğuzhan Dincel¹, Fatih Basak²

¹Department of General Surgery, Adıyaman University, Faculty of Medicine, Adıyaman, Turkey

²Department of General Surgery, Umraniye Education and Research Hospital, Istanbul, Turkey

Corresponding author:

Oğuzhan Dincel

Adıyaman Üniversitesi Tıp Fakültesi, Genel Cerrahi Ana Bilim dalı, Adıyaman, Türkiye

Email: droguzhandincel@yahoo.com

Telefon: +905366010630

Geliş tarihi / Received: 24.02.2015

Kabul tarihi / Accepted: 14.07.2015

Abstract

Mucocele of the appendix is a rare entity, characterized by distension of the appendix lumen due to accumulation of mucus. If untreated, mucocele may rupture producing a potentially fatal entity known as pseudomyxoma peritonei. The type of surgical treatment is related to the dimensions and the histology of the mucocele. Appendectomy is used for simple mucocele or for cystadenoma. In this paper, we report a case of symptomatic 54-year-old woman in whom mucocele was found by surgery because of acute abdomen clinic and preoperative computed tomography scan. Surgery revealed a big appendix measuring 6cm in length and 3cm in diameter. The pathologic diagnosis was simple mucocele, no further operation was performed.

Key words: Acute abdomen, Mucocele, Appendicitis

Öz

Apandiks'in mukoseli mukus birikimi sonrası lümenin tıkanması ve apandiks'in distansiyonu ile ortaya çıkan nadir görülen bir durumdur. Tedavi edilmez ise mukosel parçalanıp dağılılabılır ve pseudomyxoma peritonei olarak bilinen potansiyel hayati bir klinik tabloya sebep olabilir. Cerrahi tedavinin tipi boyutlarına ve mukosel'in histolojisine bağlıdır. Basit mukosel veya kistadenom tedavisinde appendektomi yeterlidir. Bu yazıda, mukoseli akut karın nedeni ile yapılan ameliyatta ve ameliyat öncesi bilgisayarlı tomografi bulgularıyla tanı koyulan 54 yaşında bayan hastayı sunuyoruz. Ameliyatta 6cm uzunluğunda 3cm çaplı büyük bir apandiks görüldü. Patolojik değerlendirme basit mukosel idi ve ek bir ameliyat yapılmadı.

Anahtar kelimeler: Akut karın, Mukosel, Apandisit

Introduction

Appendiceal mucocele (AM) is a rare pathology of the appendix, characterized by a cystic dilation of the lumen with stasis of mucus. The incidence ranges between 0.2% and 0.3% of all appendectomies, with a higher frequency in

females (4/1) and age of 50 years and more (1). It may be a benign or malignant process. There are four histological types, which lead to individualized surgical treatment and course in each case. The disease usually is presented as acute appendicitis (2). In this report, we aimed to

present case of AM, and discuss under the review of literature, and to inform surgeons' knowledge about the disease and treatment strategies.

Case report

A 54-year-old woman was admitted to the emergency department because of pain in the right lower quadrant of the abdomen for a week. He had no vomiting or nausea. Physical examination showed rebound tenderness in the right lower quadrant and he had diagnosed as acute abdomen. Laboratory tests, blood count and leukocyte levels was normal. Abdominal ultrasonography (USG) examination revealed cystic mass in the appendiceal area and proposed advanced investigation. Computed tomography (CT) of abdomen demonstrated a well demarcated, elliptical 6 x 3 cm cystic dilated mass in the right lower quadrant of the abdomen (figure 1). Surgical exploration revealed that the mass is arising from the appendix (figure 2). Appendiceal radix was free of disease, and simple appendectomy was performed. Serum levels of CA 19-9 and carcino-embryonic antigen were within normal ranges. Pathological examination revealed a mucinous cystadenoma with dimensions of 6 x 3 x 2.5 cm. Cecum was free of the disease and AM restricted only to the appendix. No further operation was needed. The patient's postoperative course was unremarkable, and he was discharged on the 6th postoperative day.

Discussion

There are many etiologies for an AM, which can be malignant or benign. The mucocele may occur as a simple retention cyst caused by the accumulation of mucus in the appendix. This accumulation can be caused by its obstruction by a coprolith or proximal to an inflammatory stenosis or tumor. Other etiologies are mucus-secreting tumors, including mucinous cystadenoma and mucinous cystadenocarcinoma. Increase of tumor markers

may indicate a probable neoplastic origin (3).

Symptomatology of AM is not specific, 25% of patients with very large lesions can be asymptomatic. The most common presentation is right lower quadrant pain, similar to an acute appendicitis; a palpable mass can be found in 50% of cases, whereas urinary dysfunction or hematuria is rarely related (4). The rare complications include intestinal bleeding and intestinal obstruction frequently caused by intussusception (4, 5).

Appendix diameter 15 mm or more in USG examination has been determined as the threshold for AM diagnosis with a sensitivity of 83% and a specificity of 92% (2). Abdominal USG shows a cystic, encapsulated lesion, firmly attached to the cecum, with liquid content and an internal variable echogenicity related to mucus density (6). Abdominal CT scan is important in the diagnosis and evaluation of the extent of the disease. A typical CT scan findings of an AM are a round, low-density, thin-walled, encapsulated mass, communicating with the cecum (6-8).

Therapy is surgical, but laparoscopic approach is not advised because of the risk of rupture (9). The worst complication is pseudomyxoma peritonei, characterized by peritoneal dissemination caused by iatrogenic or spontaneous rupture of the mucocele. In benign mucocele, the pseudomyxoma is confined to the peri-appendicular area. In malignant cases, this dissemination is considered a real metastatic entity; retro-peritoneal or pleural implants are occasionally reported (10).

Conclusion

The mucocele of the appendix is an uncommon disorder which is often asymptomatic but sometimes causes acute appendicitis like symptoms. Sometimes, patients with mucocele can present with confusing symptoms. Preoperative suspicion and diagnosis of appendiceal mucocele are important. Ultrasonography and computed tomography are

useful tools for the diagnosis of appendiceal mucocele. Surgical treatment of the AM is mandatory because of the potential for malignant transformation and prevention of pseudomyxoma peritonei due to spontaneous rupture of the

mucocele. Therefore, preoperative diagnosis or suspicion is required for carefully planned resection of lesion. Very careful surgical excision should be performed, but it is important not to rupture the mass.

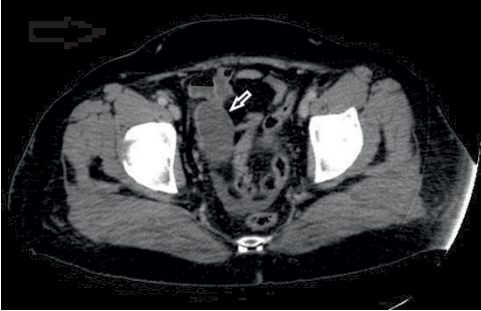


Figure 1: Axial CT image shows a dilated appendix which is coming down to the pelvis.

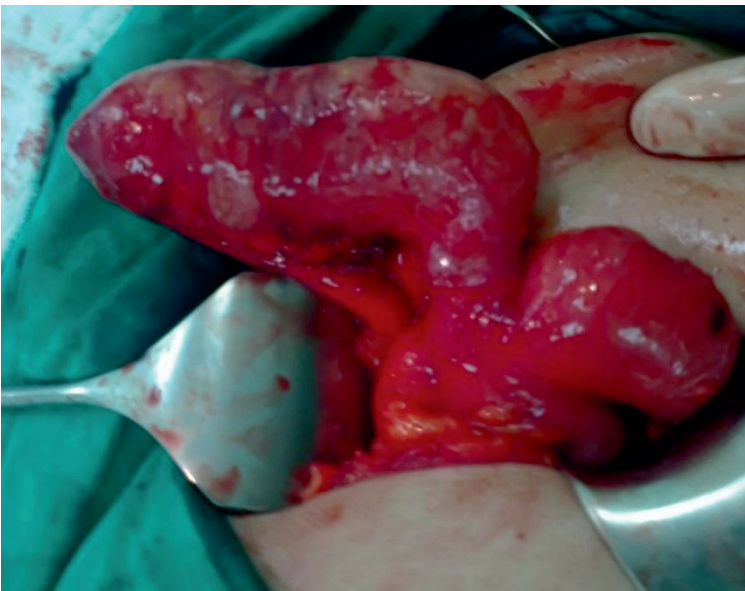


Figure 2: View of dilated appendix at the operation.

References

1. Louis TH, Felter DF. Mucocele of the appendix. Proc (Bayl Univ Med Cent). 2014; 27(1): 33-4.
2. Lien WC, Huang SP, Chi CL, Liu KL, Lin MT, Lai TI, et al. Appendiceal outer diameter as an indicator for differentiating appendiceal mucocele from appendicitis. Am J Emerg Med 2006;24(7):801-5.
3. Pickhardt PJ, Levy AD, Rohrmann CA Jr, Kende AI. Primary neoplasms of the appendix: radiologic spectrum of disease with pathologic correlation. RadioGraphics 2003;23(3):645-662.
4. Rojnovceanu G, Ghidirim G, Mishin I, Vozian M, Mishina A. Preoperatively diagnosed mucocele of the appendix. Chirurgia (Bucur) 2014; 109(3): 416-20.
5. Hassan S, Dhebri A, Lin L, Haque M. Appendiceal mucocele: a missed diagnosis. BMJ Case Rep 2013 Jan 11;2013. doi: 10.1136/bcr-2012-007983.
6. Kim SH, Lim HK, Lee WJ, Lim JH, Byun JY. Mucocele of the appendix: ultrasonographic and CT findings. Abdom Imaging 1998; 23(3): 292-6.
7. Zissin R, Gayer G, Kotos E, Apter S, Peri M, Sharipo-Feinberg M. Imaging of mucocoele of the appendix with emphasis on the CT findings: a report of 10 cases. Clin Radiol 1999;54(12):826-32.
8. Isaacs KL, Warshauer DM. Mucocele of the appendix: computer tomographic, endoscopic, and pathologic correlation. Am J Gastroenterol 1992;87(6):787-9.
9. Gonzalez Moreno S, Shmookler BM, Sugarbaker PH. Appendiceal mucocele. Contraindication to laparoscopic appendectomy. Surg Endosc 1998;12(9):1177-9.
10. Stevens KJ, Dunn K, Balfour T. Pseudomyxoma extraperitonei: a lethal complication of mucinous adenocarcinoma of the appendix. Am J Gastroenterol 1997;92(10):1920-2.