



Evaluation Of Tumoral Lesions Of The Skin And Subcutaneous Tissue Of The Head And Neck In Geriatric Population

Kemal Koray Bal¹, Talih Özdaş², Emin Kapı³, Sedat Alagöz¹, Elif Burcu Şenyurt⁴,
Asiye Merve Erdoğan⁵, Ragıp Onur Öztornacı⁶

1 Otorhinolaryngology Specialist, Department of Otorhinolaryngology & Head and Neck Surgery, University of Health Sciences Adana City Hospital, Adana, Turkey

2 Associate Professor, Department of Otorhinolaryngology & Head and Neck Surgery, University of Health Sciences Adana City Hospital, Adana, Turkey

3 Associate Professor, Department of Plastic, Aesthetic and Reconstructive Surgery University of Health Sciences Adana City Hospital, Adana, Turkey

4 Pathology Specialist, Department of Pathology University of Health Sciences Adana City Hospital, Adana, Turkey

5 Research Assistant, Department of Otorhinolaryngology & Head and Neck Surgery, University of Health Sciences Adana City Hospital, Adana, Turkey

6 PhD Student, Department of Biostatistics and Medical Informatics, University of Mersin, Mersin, Turkey

Received: 14.07.2020; Revised: 02.02.2021; Accepted: 14.02.2021

Abstract

Introduction: Malignant tumors of the skin include basal cell carcinoma, squamous cell carcinoma, malignant melanoma and tumors of the skin appendages. Skin lesions in the head and neck region are frequently encountered in the geriatric population. Although these lesions are generally benign, it is widely known that the prevalence of malignant lesions increases with age. In adults, 80% of the masses in the neck, except benign thyroid diseases, are of neoplastic origin and this rate reaches 90% after the 5th decade. About 70% of these neoplastic masses are malignant, and three-quarters of these are metastatic and one-fourth is primary malignancies.

Objectives: Increasing world population, increasing survival time and increasing geriatric patient population create some differences in healthcare. We planned this study for this purpose.

Methods: The data of 73 patients aged 65 and over were retrospectively analyzed. Patients were divided into two groups as 65-75 years old (Group 1), > 75 years old (Group 2), by age.

Results: Premalignant lesions were found to be statistically significantly higher in Group 1 ($p < 0.01$). It was observed that malignant lesions were statistically significantly more common in the skin compared to the subcutaneous tissue. ($p = 0.015$) Malignant skin lesions were observed statistically significantly more frequently in the neck region compared to other regions ($p = 0.004$).

Conclusions: The risk of malignancy in the patient group over 75 years is approximately doubled. It is necessary to approach the neck and subcutaneous masses carefully in terms of malignancy in the geriatric patient group

Keywords: Geriatric, Otorhinolaryngology, Skin, Subcutaneous, Tumor

DOI: 10.5798/dicletip.

Correspondence / Yazışma Adresi: Kemal Koray Bal, Otorhinolaryngology Specialist, Department of Otorhinolaryngology & Head and Neck Surgery, University of Health Sciences Adana City Hospital, Adana, Turkey e-mail: dr.kemalkoraybal@gmail.com

Geriatrik Populasyonda Baş Boyun Cilt, Ciltaltı Tümöral Lezyonlarının İncelenmesi

Öz

Giriş: Derinin malign tümörleri arasında bazal hücreli karsinom, skuamöz hücreli karsinom, malign melanom ve deri eklerinin tümörleri bulunur. Geriatrik popülasyonda baş ve boyun bölgesindeki deri lezyonlarına sıklıkla rastlanmaktadır. Bu lezyonlar genellikle iyi huylu olmakla birlikte, malign lezyonların prevalansının yaşla birlikte arttığı yaygın olarak bilinmektedir. Yetişkinlerde benign tiroid hastalıkları dışında boyundaki kitlelerin 80%'i neoplastik kökenlidir ve bu oran 5. dekattan sonr 90%'a ulaşır. Bu neoplastik kitlelerin yaklaşık 70%'i maligndir, bunların dörtte üçü metastatik malignite ve dörtte biri birincil malignitelerdir.

Amaç: Dünya nüfusunun artması, sağkalm süresinin artırılması ve geriatrik hasta popülasyonunun artırılması sağlık hizmetlerinde bazı farklılıklar yaratır. Bu çalışmayı bu amaçla planladık.

Yöntemler: 65 yaş ve üstü 73 hastanın verileri retrospektif olarak incelendi. Hastalar yaşa göre 65-75 yaş (Grup 1), > 75 yaş (Grup 2) olmak üzere iki gruba ayrıldı.

Bulgular: Premalign lezyonlar Grup 1'de istatistiksel olarak anlamlı derecede yüksek bulundu ($p < 0.01$). Malign lezyonların ciltte deri altı dokuya göre istatistiksel olarak anlamlı derecede daha yaygın olduğu gözlemlendi. ($p = 0.015$) Malign deri lezyonları boyun bölgesinde diğer bölgelere göre istatistiksel olarak anlamlı derecede daha sık gözlemlendi ($p = 0.004$).

Sonuçlar: Malignite riski 75 yaşın üzerindeki hasta grubunda yaklaşık iki katına çıkar. Geriatrik hasta grubunda boyun ve deri altı kitlelere malignite açısından dikkatle yaklaşmak gerekir.

Anahtar Kelimeler: Geriatrik, Kulak Burun Boğaz, Deri, Subkutan, Tümör.

INTRODUCTION

Malignant tumors of the skin include basal cell carcinoma, squamous cell carcinoma, malignant melanoma and tumors of the skin appendages. Malignant skin tumors account for half of the cancer cases diagnosed annually in the United States¹. Biological behavior of these tumors is quite variable and basal cell carcinoma (BCC) constitutes the majority of cases among them, followed by squamous cell carcinoma (SCC), malignant melanoma (MM) and tumors of skin appendages, in descending order². Actinic keratosis, keratoacanthoma, Bowen Disease are premalignant lesions and can turn into SCC³. Proliferative Pilar tumor (also called proliferative trichilemmal tumor) can be benign, premalignant or malignant. Those which are malignant have cellular dysplasia, connective tissue invasion, abnormal and/or high mitoses, cellular pleomorphism, cytological atypia, necrosis, infiltration, aneuploidy and their probability of to be metastatic is 25%⁴. Inflammatory causes (nonspecific dermatitis), cysts (dermoid cyst, etc.), reactive lesions (hypertrophic scar), neoplastic lesions (lipoma, hemangioma,

lymphangioma, neurofibroma, nevus, etc.) and growth disorders are among benign skin and subcutaneous lesions⁵.

Skin lesions in the head and neck region are frequently encountered in the geriatric population. Although these lesions are generally benign, it is widely known that the prevalence of malignant lesions increases with age. In this respect, the most common malignant pathology is basal cell carcinoma (BCC), followed by squamous cell carcinoma (SCC) and malignant melanoma (MM). Prolonged exposure of the head and neck to ultraviolet (UV) rays is an important risk factor for skin cancer development in geriatric patients. BCC and SCC (Non Melanom Skin Cancer, NMSC) are often observed as locally invasive ulcers⁶.

SCCs seen in the head and neck and lymph nodes carry a higher risk of recurrence than SCCs in the trunk and extremities. Head and neck BCCs are more likely to recur than those in the trunk and extremities. BCCs are much less likely to metastasize than SCCs^{7,8}. In Dalal's study, the nose and cheek areas were reported as the most common localization for BCC. In another study,

SCC was significantly higher in the perilabial region^{9,10}.

In adults, 80% of the masses in the neck, except benign thyroid diseases, are of neoplastic origin and this rate reaches 90% after the 5th decade. About 70% of these neoplastic masses are malignant, and three-quarters of these are metastatic and one-fourth is primary malignancies. While diagnosis can be made by history and physical examination in children and young adults, the excision of the mass is generally required for definitive diagnosis in adults^{11,12}.

Malignant skin lesions in the nose and ear have a higher rate of recurrence¹³. Swanson found that high-risk areas fall into the "H" zone of the face. The locations designated by Swanson are the place where the nasolabial fold intersects with the nasal ala, the nasal septum, the nasal ala, the medial cantus, the lower eyelid of the periorbital region, extension of the preauricular region to the extends to the temporal bone, and some scalp lesions¹⁴.

Increasing world population, increasing survival time and increasing geriatric patient population create some differences in healthcare. We planned this study for this purpose.

METHODS

This study was carried out between 01.05.2019 and 01.05.2020 at University of Health Sciences Adana City Training and Research Hospital ENT and Plastic, Reconstructive and Aesthetic Surgery clinics. The data of 73 patients with the age of 65 years and over and who presented with a lesion in the head and neck area, and who underwent excision of the lesion with histopathological diagnosis were retrospectively analyzed. Patients were divided into two groups according to age as 65-75 years (Group 1) and >75 years (Group 2).

Anatomical localizations were divided into 10 areas as scalp, occipital region, neck,

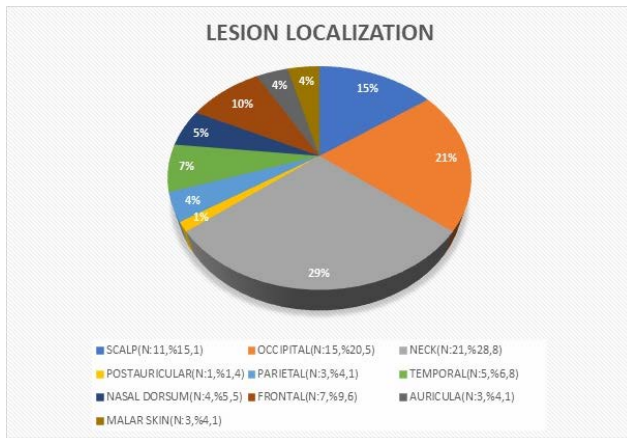
postauricular region, parietal region, temporal region, nasal skin, frontal region, auricle, and malar skin. Cancers of lips were excluded. Lesions were categorized as benign, premalignant, malignant and neoplastic and nonneoplastic. Benign lesions are epidermal cyst, neurofibroma, fibroma, seborrheic keratosis, lipoma, ulcer, intradermal nevus, foreign body reaction-granulation, hemangioma and trichilemmal tumor. Premalignant lesions are pilar tumor, keratoacanthoma and actinic keratosis. Malignant lesions are basal cell carcinoma (BCC), squamous cell carcinoma (SCC), Non-Hodgkin lymphoma (NHL) and malignant epithelial tumor metastasis. (METM) In this study, we did not have a pilar tumor case that fully met the criteria for malignancy. Cases with necrosis and atypia were included in the category of premalignant lesions. Nonneoplastic lesions were epidermal cysts, granulation tissue, ulcers, and all other lesions were neoplastic.

Statistical analysis of the data was performed by using SPSS 21.0 statistical package program (trial version). Descriptive statistics were presented as mean and standard deviation for continuous variables, and categorical variables were expressed as numbers and percentages. Categorical variables were analyzed by using Chi-Square test. Test of normal distribution for continuous variables was performed by using Shapiro-Wilks and Kolmogorov-Smirnov tests, and parametric tests were used for variables with normal distribution. Non-parametric statistical tests were used for variables with non-normal distribution. The level of significance in all analyses was considered as 0.05 (p value). Ethics Committee approval was obtained from the Clinical Ethics Board of the Adana City Training and Research Hospital (Dated 27 February 2020 and numbered 740).

RESULTS

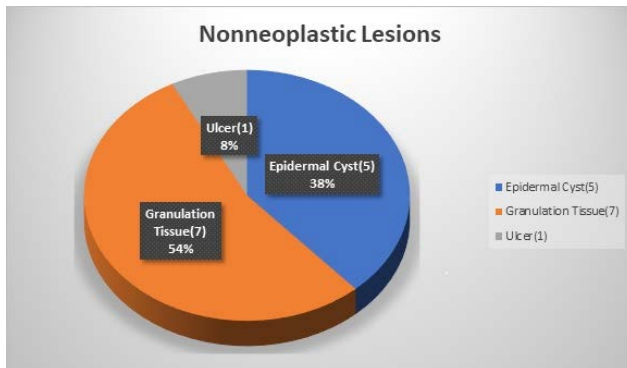
A total of 73 patients, 56 males (76.7%) and 17 females (23.3%) were included in the study. The ages of the patients were between 65 and 92 years with a mean age of 73 years. There were 48 patients (65.7%) in Group 1 and 25 patients (34.3%) in Group 2.

Among the patients, 44 had skin (60.2%) and 29 patients had subcutaneous lesion (39.8%). The most common localization of the lesions was the neck region in 21 patients (29%), while the rarest localization was postauricular region in 1 patient (1.4%). (Graphic 1).



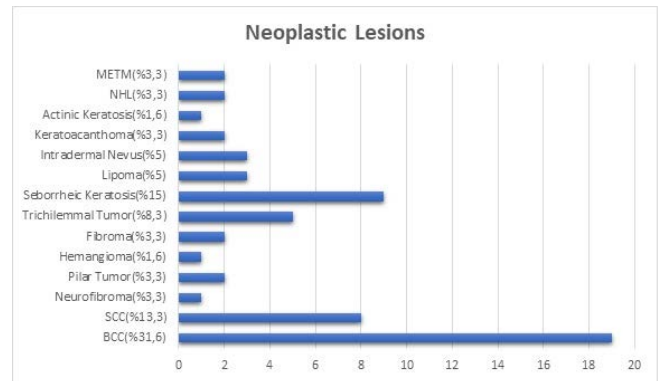
Graphic 1: Localizations of Lesions

Sixty (82.1%) of the lesions were neoplastic and 13 (17.9%) of them were nonneoplastic. The most common nonneoplastic lesion was granulation tissue in 7 patients (53.8%) (Graphic 2).

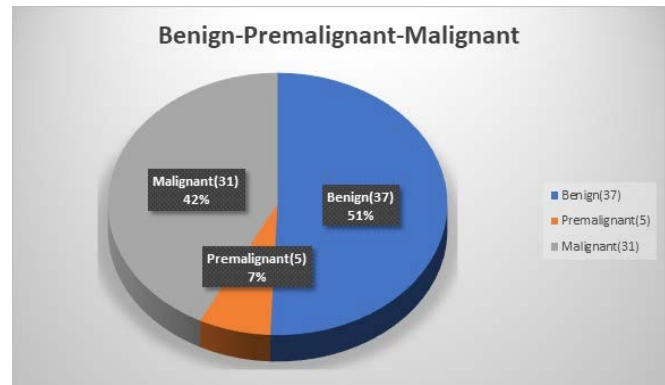


Graphic 2: Nonneoplastic Lesions

The most common lesion (26%) and neoplastic lesion (31.6%) was basal cell carcinoma in 19 patients (BCC). Benign (51%), premalignant (5%) and malignant (42%) lesions were detected in 37, 5 and 31 patients, respectively (Graphic 3, Graphic 4). The most common benign lesion was seborrheic keratosis (24.3%), most common premalignant lesion was pilar tumor and keratoacanthoma (40%, 40%), and most common malignant lesion was BCC (61.2%). Malignant skin tumor (34.2%) was detected in 25 patients, and the most common malignant skin tumor was BCC (76%).



Graphic 3: Neoplastic Lesions

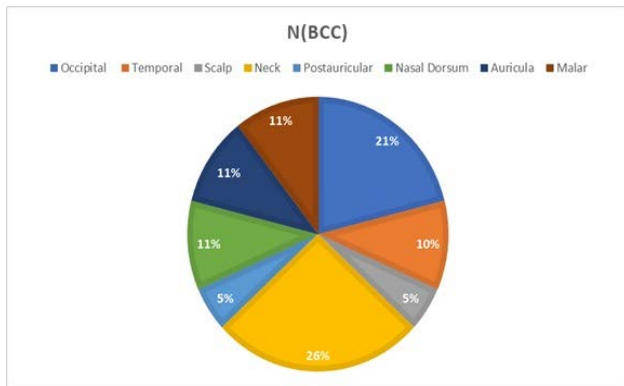


Graphic 4: Benign-Premalignant-Malignant Lesions Frequency

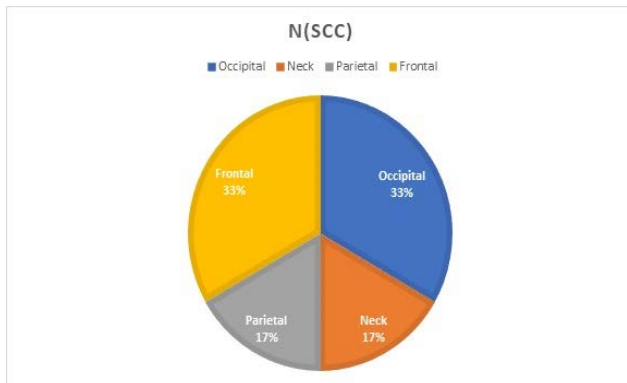
According to the age distribution (Group 1 and Group 2), the most common localization of the lesions was occipital region (25%) and neck (44%) in Group 1 and Group 2, respectively. The most common lesion was BCC with an incidence of 20.8% and 36% in Group 1 and Group 2, respectively. All the premalignant lesions were

seen in Group 1. Malignancy was seen in 33% and 60% in Group 1 and Group 2, respectively.

Of the malignant lesions, 25 were skin tumors (80.6%), 2 were subcutaneous neck metastasis of SCC (6,4%), 2 were NHL (neck, subcutaneous, 6.4%), and 2 were METM (neck, subcutaneous, 6.4%). Nineteen of malignant skin tumors were BCC (76%) and 6 were SCC (24%). BCC was most commonly detected in the neck localization (5 patients, 26%), and skin SCC was most common in the occipital and frontal region (2 patients, 33% each). (Graphic 5, Graphic 6).



Graphic 5: Skin Bcc Localizations



Graphic 6: Skin Scc Localizations

No statistically significant association was found between the age groups and the localization of the lesion as skin or subcutaneous tissue ($p=0.451$). The rate of benign character of the lesion was statistically different in the two groups. Benign lesions were observed to be more common in Group 1. ($p=0.03$) Premalignant lesions were found to be statistically significantly higher in Group 1

($p<0.01$). No significant difference was observed between the two groups in terms of malignant lesions. ($p=0.856$) No statistically significant difference was seen between the gender and the character of the lesion as benign, premalignant and malignant ($p=0.174$).

No statistically significant association was observed between the localization of the lesion as skin or subcutaneous tissue and the character of the lesion as benign or premalignant. ($p=0.625$, $p=0.634$) It was observed that malignant lesions were statistically significantly more common in the skin compared to the subcutaneous tissue. ($p=0.015$) Malignant skin lesions were observed statistically significantly more frequently in the neck region compared to other regions ($p=0.004$).

DISCUSSION

Duduyemi et al. evaluated 451 patients between the ages of 4 and 85 years and with skin and subcutaneous soft tissue lesions. The study included 201 males and 250 females⁵. In this present study, there were 73 patients, all >65 years old, and 56 of them were males and 17 were females.

Among all the cancers diagnosed, malignant skin tumors account for approximately more than half of the cases. More than 1,300,000 new cases of skin tumors were reported in the United States alone in 2003¹⁵. Many factors have been blamed for the etiology of these tumors. However, among these, the most important factors for the development of BCC and SCC is sun damage. BCC and SCC are mainly seen in the white race. Males are twice as likely to develop BCC and SCC compared to females. Fortunately, although it is so common, mortality in malignant skin tumors is low. Total excision of the lesion with adequate surgical margins and repair of the defect formed constitute the basis of the treatment. 86% of BCC lesions and 70% of SCC lesions appear in the facial area^{16,17}.

Studies have reported a high increase in the incidence of BCC in white patients over the age of 65. More than 80% of skin SCC cases occur in elderly patients, with a mean age at diagnosis of 70 years¹⁸. Although there are studies on skin diseases in the geriatric population in the literature, detailed studies on the surgical results of lesions in the head and neck region in this age group are quite less¹⁹. In our study, the male / female ratio is 3.3, the most common BCC is in the neck skin (26%), SCC is in the occipital and frontal region (33%, 33%).

In the study by Hussein, 262 malignant skin tumors were examined and mean ages were found as 66 years (+/- 10) for BCC and 60 years (+/- 5.18) for SCC²⁰. In our study, the mean age of cases with BCC and SCC was 74.6 and 76.2 years, respectively.

Duduyemi evaluated the benign and malignant skin and subcutaneous lesions and found the localization of the lesions, in descending order of frequency to be upper extremity (26.8%), lower extremity (23.9%), head (22.2%), trunk (16.4%), perineum (5.3%) and neck (5.3%). The author reported that 68.3% of the lesions were neoplastic and 92.9% of them were benign⁵. In our study, neoplastic lesions (82%) were seen in 60 patients and 51% of all lesions were benign.

BCC originates from the basal cells of the epidermis. It typically occurs after the 4th decade²¹. According to the results of Shanoff's study on the distribution of BCCs in the body, 93% of BCCs were observed in the head and neck. BCC was seen most commonly in the nose (26 %), followed by, in descending order of frequency, malar region (18%), eye (8%), ear (8%), infraorbital region (5%), upper lip (5%), forehead (5%), postauricular region (4%), chin (3%) and cheek (1%)¹⁶. In our study, there were 19 patients with BCC, 15 were males and 4 were females. The most common localization of BCC was the skin of the neck in 5 patients (26.3%),

followed by the occipital region in 4 patients (21%).

In Freeman's study investigating the anatomical location of SCC lesions, 79% of the lesions were observed in the head and neck region, 45% in the cheek and lip region, 13% in the nose region, and 12% in the ear region¹⁷. The most common localization of SCC in our study was occipital (33%) region and frontal region (33%, each). Other areas where SCC was seen were the parietal region and the skin of the neck.

Inflammatory lesions are the most common cause of neck masses in developing countries, while congenital and neoplastic masses are more frequent in developed countries²². Ucak et al., most frequently encountered psoriasis (46.5%) lesions in pediatric patients with skin lesions, while the rate of neoplasms was 6.8%²³. Duduyemi reported the rate of nonneoplastic lesions as 31.7% .5 (Inflammatory 16.9%, cyst 13.1%, reactive 1.6%, developmental disorder-hamartome 0.2%) Lymphadenopathy can develop due to primary lymphoproliferative or infiltrative diseases, as well as in infectious and non-infectious conditions. Hamartomas may rarely develop from the neck lymph nodes^{24,25}. In our study, the most common localization of subcutaneous tumors was the neck in 11 patients (37.9%). Among the masses in the neck, 54.5% were malignant. The most common malignant tumors in the neck were SCC (18.1%), NHL (18.1%), and METM (18.1%).

CONCLUSION

The world population is getting older day by day. The differences in the diagnosis and treatment of the geriatric group and the planning of health services due to these differences are important. The risk of malignancy in the patient group over 75 years is approximately doubled. It is necessary to approach the neck and subcutaneous masses carefully in terms of malignancy in the geriatric patient group. Early diagnosis and treatment is

vital in malignant skin tumors. Further examination should be performed for the palpable subcutaneous masses in the head and neck region, and an excisional biopsy should be performed if necessary.

Ethical Committee Approval: Ethics Committee approval was obtained from the Clinical Ethics Board of the Adana City Training and Research Hospital (Dated 27 February 2020 and numbered 740).

Declaration of Conflicting Interests: The authors declare that they have no conflict of interest.

Financial Disclosure: No financial support was received.

REFERENCES

1. Miller DL, Weinstock MA. Nonmelanoma skin cancer in the United States: incidence. *J Am Acad Dermatol.* 1994; 30: 774-8.
2. Aubry F, Mac Gibbon B. Risk factors of squamous cell carcinoma of the skin: A case-control study in the Montreal region. *Cancer.* 1985; 55: 907-11.
3. Paolino G, Donati M, Didona D, Mercuri SR, Cantisani C. Histology of Non-Melanoma Skin Cancers: An Update. *Biomedicines.* 2017; 5: 71.
4. Sutherland D, Roth K, Yu E. Malignant Proliferating Trichilemmal Tumor Treated with Radical Radiotherapy: A Case Report and Literature Review. *Cureus.* 2017; 9: e999.
5. Duduyemi BM, Omonisi AE, Titiloye NA. Skin and Soft Tissue Lesions in a District Hospital in Central Nigeria: A Histopathological Study. *Dermatol Res Pract.* 2019; 2019: 8143680.
6. Korkmaz MO, Dikicier BS, Bahçecitapar M, Elden SG, Güven M. Approach to Cutaneous Lesions of the Head and Neck in the Geriatric Age Group: Retrospective Analysis of 170 Cases. *Turkish Journal of Geriatrics.* 2020; 23: 206-15.
7. Kim JYS, Kozlow JH, Mittal B, Moyer J, Olenecki T, Rodgers P. Guidelines of care for the management of cutaneous squamous cell carcinoma. *J Am Acad Dermatol.* 2018; 78: 560-78.
8. Losquadro WD. Anatomy of the skin and the pathogenesis of nonmelanoma skin cancer. *Facial Plast Surg Clin North Am.* 2017; 25: 283-9.
9. Dalal AJ, Ingham J, Collard B, Merrick G. Review of outcomes of 500 consecutive cases of non-melanoma skin cancer of the head and neck managed in an oral and maxillofacial surgical unit in a District General Hospital. *Br J Oral Maxillofac Surg.* 2018; 56: 805-9.
10. Ozturk K, Gode S, Erdogan U, Akyildiz S, Apaydin F. Squamous cell carcinoma of the lip: survival analysis with long-term follow-up. *Eur Arch Otorhinolaryngol.* 2015; 272: 3545-50.
11. Koç C, Akyol U, Özdem C. Boyun Kitleleri. *Ankara Tıp Mecmuası.* 1995; 48: 243-52.
12. Alvia A, Johnson JT. The neck mass a challenging differential diagnosis. *Postgrad Med.* 1995; 97: 87-90, 93-4, 97.
13. Panje WR, Ceilley RI. The influence of embryology of midface on the spread of epithelial malignancies. *Laryngoscope.* 1979; 89: 1914-20.
14. Swanson NA. Mohs surgery: technique, indications, applications, and the future. *Arch Dermatol.* 1983; 119: 761-73.
15. Jemal A, Murray T, Samuels A, et al. Cancer statistics, 2003. *CA Cancer J Clin.* 2003; 53: 5-26.
16. Shanoff LB, Spira M, Hardy SB. Basal cell carcinoma: A statistical approach to rational management. *Plast Reconstr Surg.* 1967; 39: 619-24.
17. Freeman RG, Knox JM. Clinical diagnosis of skin tumors by dermatologists. *Arch Dermatol.* 1963; 87: 350-6.
18. Albert A, Knoll MA, Conti JA, Zbar RIS. Nonmelanoma skin cancers in the older patient. *Curr Oncol Rep.* 2019; 21: 79.
19. Yaldiz M. Dermatological diseases in the geriatric age group: Retrospective analysis of 7092 patients. *Geriatr Gerontol Int.* 2019; 19: 582-5.
20. Hussein MR. Skin cancer in Egypt: a word in your ear. *Cancer Biol Ther.* 2005; 4: 593-5.
21. Goldberg LH. Basal cell carcinoma. *Lancet.* 1996; 347: 663-7.

22. McGuirt WF. Differential Diagnosis of Neck Masses. In:Cummings CW, Frederickson JM, Harker LA, Krause CJ, Richardson MA, Schuller DE. Eds.Otolaryngology Head and Neck Surgery, 3th. edn, St Louis, Mosby year book, 1998; 1686-99.
23. Ucak M, Ucmak D, Akkurt ZM, ve ark. Bir üniversite hastanesi dermatoloji polikliniğine başvuran çocuk hastaların deri biyopsilerinin klinikopatolojik korelasyonu. Dicle Med J. 2014; 41: 526-8.
24. Altun E,Azatcam M.Servikal lenf nodunda lokalize anjiomyomatöz hamartom: Olgu sunumu. Dicle Med J. 2015; 42: 86-8.
25. Gul M, Aliosmanoglu I, Turkoglu A. Erişkin çağı periferik lenfadenopatileri: Eksizyonel biyopsi uygulanan 67 hastanın sonuçları. Dicle Med J. 2013; 40: 245-9.