

BENIGN RETROPERITONEAL SCHWANNOMA; A RARE ENTITY

Nadir bir antite; Benign retroperitoneal schwannoma

Saurabh Jain¹, Souvik Chatterjee², Jyoti Ranjan Swain¹, Santanu Sinha¹

Postgraduate trainee, Department of General Surgery¹, Medical College and Hospital, Kolkata
Department of General Surgery², North Bengal Medical College and Hospital, Darjeeling / India
Corresponding Address: Dr. Souvik Chatterjee dr.souvikchatterjee@gmail.com

Cer San D (J Surg Arts), 2014;7(1):43-45. <http://dx.doi.org/10.14717/jsurgarts.2014.134>

ABSTRACT

Retroperitoneal schwannoma is a rare retroperitoneal tumor. As the presentation is usually not specific and lack of any typical evidences in imagine or other laboratory studies, so the preoperative diagnosis is often difficult. Here we are reporting a rare case of retroperitoneal schwannoma in an 18 years old male patient presenting as an asymptomatic retroperitoneal lump in the lower abdomen. Histopathological examination following surgical excision of the lump revealed benign retroperitoneal schwannoma, which was confirmed by immunohistochemistry.

Key words: Schwannoma, retroperitoneum.

ÖZET

Retroperitoneal schwannoma nadir görülen bir tümördür. Hastalığın belirtilerinin değişken olması, laboratuvar ve görüntüleme çalışmalarının nonspesifik olması nedeniyle, preoperatif tanı genellikle zordur. Burada 18 yaşındaki bir erkek hastamızda görülen alt abdomen retroperitoneal bölgede yerleşmiş olan asemptomatik benign schwannoma olgusu sunuldu. Histopatolojik muayene sonucunda konulan tanı immünhistokimyasal olarak teyid edildi.

Anahtar kelimeler: Schwannoma, retroperiton.

INTRODUCTION

Schwannomas are soft tissue tumors originating from schwann cells of peripheral nerve sheaths. They are usually present in cranial and peripheral nerves in the head and neck or in the upper extremities (1, 2). Retroperitoneal schwannomas accounts for only 0.7-2.7% of all schwannomas (3), whereas retroperitoneal schwannomas accounts for only 1.2% of all retroperitoneal tumors (4). Schwannomas are benign tumor but they may turn in to a malignant one (1). Benign variety usually presents as painless slow growing lump. The chance of recurrence is very low following complete excision of benign lesion.

CASE

An 18 years old male patient presented in our out-patient-department with chief complaints of a swelling in abdomen at the level of umbilicus for

last 3 months. The swelling was progressively increasing in size without any history of abdominal pain, alteration of bowel habit, black tarry stool, urinary symptoms and swelling of lower extremities. There was no history suggestive of tuberculosis. His past medical and surgical history and family history were unremarkable. On physical examination a firm, non tender, globular, non mobile lump measuring (6×6 cms) was palpable in left side of umbilical region of abdomen, which was retroperitoneal in location. There was no palpable lymph node. Examination of external genitalia & digital rectal examination revealed also within normal limit. No neurovascular deficit was detected in lower limbs. Café-au-lait spot or dermal neurofibroma were absent.

Ultrasonography of whole abdomen revealed a rounded solid mass measuring (62x61) mm with central anechoic area in retroperitoneum around left paravertebral area. Contrast enhanced CT scan

of whole abdomen showed a thick walled necrotic lesion (71x60x68 mm) seen in left prevertebral area at lower abdomen suggesting abscess; it was situated anteromedially to left psoas muscle & left external and internal iliac arteries were displaced medially (Figure 1). CT scan of abdomen was otherwise within normal limit without any evidence of lymphadenopathy.

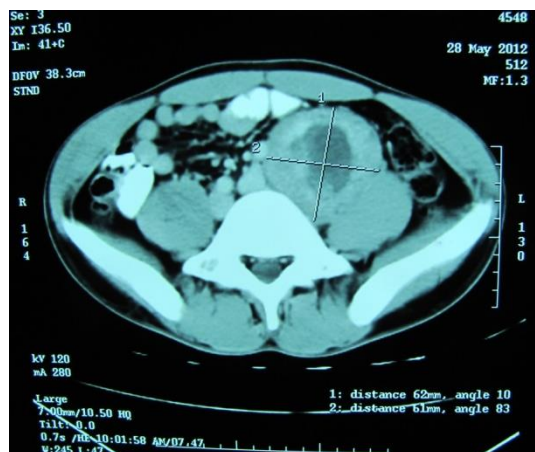


Figure 1: CT scan showing schwannoma.

CT guided FNAC report was inconclusive. Chest X-Ray, x-Ray lumbosacral spine, Mantoux test, colonoscopic examination & routine blood examination didn't show any abnormality.

Based on available data, patient was undergone transabdominal exploration via standard midline incision under general anesthesia. On exploration pancreas, liver & other organs appeared normal. A (7x6x7) cm lobulated, encapsulated mass was noted in retroperitoneum displacing left external & internal iliac artery without any evidence of enlarged lymph nodes, intraabdominal metastasis (Figure 2).

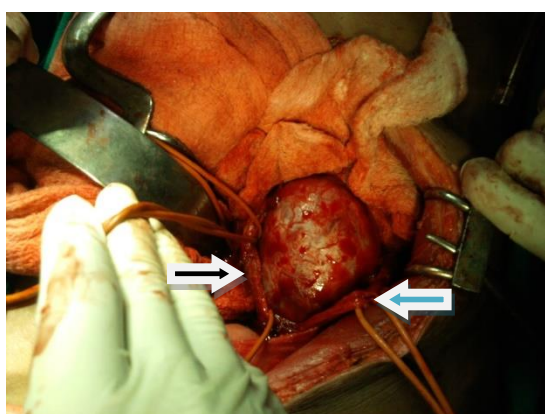


Figure 2: Operative picture; black arrow and blue arrow show left iliac vessels and left ureter respectively.

The mass was excised & sent for histopathological examination. Histopathological examina-

tion showed (Figure 3) spindle shaped cells with elongated nuclei, mild nuclear pleomorphism, Verocay bodies and mitosis, suggestive of benign schwannoma of retroperitoneum. The resection margins were free from tumor invasion. Immunohistochemistry study of the tumor cells expresses S-100 protein positivity with negative results for Desmin, SMA and CD-34. Post operative period was uneventful with discharge from hospital on 5th post operative day. He is under regular follow up in our out patients' department for last 3months following operation without any evidence of recurrence.

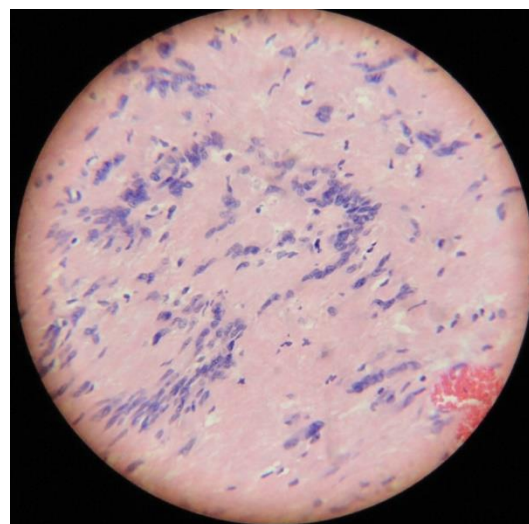


Figure 3: Microscopic view of schwannoma (Magnification – 400x; Stain used HE).

DISCUSSION

Retroperitoneal schwannomas are rare soft tissue tumors of neurogenic origin excepting von Recklinghausen's disease. They arise from Schwann cells of peripheral nerve sheath and can occur anywhere in the body where Schwann cells are present. Most common locations are head and neck region and upper and lower extremities (1, 2). Schwannomas can also occur in posterior mediastinum and rarely in retroperitoneum. Retroperitoneal schwannomas accounts for only 0.7-2.7% of all schwannomas (3). The usual site for retroperitoneal schwannomas (RSs) is either paravertebral space or presacral region (1, 5). RSs are generally affects the patients between 40-60 years of age without any sexual predilection. It uncommonly affects patients with young ages as in our case.

Schwannoma may be benign or malignant (6). Only 0.7% of benign schwannoma are located at retroperitoneum, whereas 1.7% of malignant variety involves retroperitoneum (1). Benign schwannoma are solitary, slow growing tumors and can reach a large size before producing any symptom. Though the mass effect with tumor impinging on the adjacent structures produces symptoms, most of them are usually non specific and vague. There may

be sense of fullness or pain in lumbar region or paresthesia in the distribution of affected nerve. As the retroperitoneal space is large and flexible, the RSs will reach considerably large size before diagnosis. On the other hand, non specific symptoms and lack of typical imaging findings make preoperative diagnosis often difficult (7). They are often found incidentally (8) as in our case report. Malignant forms may infiltrate the surrounding structures leading to hematuria or bone pain (9). Malignant lesions may present with features of metastasis.

Benign forms are well encapsulated, which is formed by epineurium. MR images shows hypointensity on T1 and hyperintensity on T2 weighted images. They may show cystic degenerative changes in 66% of cases. Typical MRI findings e.g. 'fascicular sign' and 'target sign' are rarely seen (7). So a high degree of suspicion is required to diagnose these cases preoperatively. CT scan may demonstrate calcification only in 23% of cases. A definitive diagnosis can only be made after careful histological and immunohistochemical examination. There are two distinct microscopic patterns seen in histological examination: a highly cellular component areas (Antoni A areas) and a loose, hypocellular, myxoid component areas (Antoni B areas). S-100 positivity and CD-34 negativity in immunohistochemistry confirm neuroectodermal origin of the schwannoma. In absence of typical radiological finding, histopathological finding and immunohistochemistry clinch the diagnosis in our case.

Complete surgical excision of the tumor with negative margin is considered to be the best treatment modality. Adjuvant therapy with radiotherapy and chemotherapy have got limited role even in malignant tumor (10,11). Surrounding involved viscera are needed to be sacrificed whenever necessary. In our patient, complete surgical excision with negative margin proves to be adequate.

Conclusion: RSs are rare retroperitoneal tumors. Though it commonly involves middle aged patients, it may affect young patients too. Due to vague symptoms and absence of typical radiological findings, RSs always poses a preoperative diagnostic challenge. Histopathology and immunohistochemistry clinch the diagnosis. Surgical excision with negative margin is treatment modality of choice.

REFERENCES

1. Goh BKP, Tan Y, Chung YA, Chow PKH, Ooi LPJ, Wong WK. Retroperitoneal schwannoma. *American J Surg* 2006;192(1):14-8.
2. Samarakoon L, Weerasekera A, Sanjeeva R, Kollure S. Giant presacral schwannoma presenting with constipation: a case report. *J Med Case Rep*. 2012;6(3):285.
3. Tortorelli AP, Papa V, Rosa F, Pacelli F, Doglietto GB. Image of the month - retroperitoneal schwannoma. *Arch Surg* 2006;141:1259-1261.

4. Li Z, Wang H, Li J, Ten L. Recurrent retroperitoneal schwannomas displaying different differentiation from primary tumor: Case report and literature review. *World J Surg Oncol*. 2010;8(1):66.

5. Song JY, Kim SY, Park EG, Kim CJ, Kim DG, Lee HK, Park IY. Schwannoma in the Retroperitoneum. *J Obstet Gynaecol* 2007;33(4):371-5.

6. Kalaycı M, Akyüz Ü, Demirağ A, Gürses B, Özkan F, Gökçe Ö. Retroperitoneal schwannoma: A rare case. *Case Rep Gastrointest Med*. 2011;2011(7):465062.

7. Kudo T, Kawakami H, Kuwatani M, et al. Three cases of retroperitoneal schwannoma diagnosed by EUS-FNA. *World J Gastroenterol* 2011; 17(29):3459-64.

8. Descazeaud A, Coggia M, Bourriez A, Goeau-Brissonniere O. Laproscopic resection of a retroperitoneal schwannoma. *Surg Endosc* 2003;17(6):520.

9. Kapan M, Önder A, Gümüş M, Gümüş H, Girgin S. Retroperitoneal schwannoma. *J Surg Case Rep* 2011;2011(10):1.

10. Lei GU, Wei LIU, Qing XU, Zhi-yong WU. Retroperitoneal schwannoma mimicking hepatic tumor. *Chinese Med J* 2008;121(17):1751-2.

11. Strauss DC, Hayes AJ, Thomas JM. Retroperitoneal tumours: review of management. *Ann R Coll Surg Engl* 2011;93(4):275-80.