



Treatment of Coxofemoral Luxation and Type-1 Salter Harris Femur Fracture in a Cat by Toggle Pin and Cross Pin Methods

Muhammed Enes ALTUĞ Ziya YURTAL Mehmet Zeki Yılmaz DEVECİ
Cafer Tayer İŞLER Halil ALAKUŞ

Hatay Mustafa Kemal University, Faculty of Veterinary Medicine, Department of Surgery, Hatay, Turkey

Received: 12.07.2018

Accepted: 16.12.2018

ABSTRACT

This case was 5 month of age, 1 kg in weight and a hybrid male cat. In radiographic examination, coxofemoral luxation and right Type-1 Salter Harris femur fracture were diagnosed. It was performed by methods of Toggle pin in hip luxation and cross pin in Type-1 Salter Harris femur fracture respectively. A toggle pin was inserted into the pelvic cavity through the acetabular tunnel formed first. Then the femoral tunnel was created and the ends of 0.5 mm diameter monofilament nylon cord that connected to the Toggle pin were passed through this tunnel and the joint motion was controlled by placing the caput femoris into the acetabulum. Finally, the ends of the rope were fixed by knotting the caudolateral angle of the trochanter. Type-1 Salter Harris femoral fracture was reached with a craniolateral approach to the knee joint. The distal part of the femur was exposed in order to perform cross pinning and the medial and lateral condyles were fixed by pins 2-3.2 mm in diameter. After the surgery, the hindlimb was supported with aluminium splint bandage and the hip was covered with soft bandage. Routine postoperative medications carried out for one week and the splint bandage removed after three weeks postoperatively. The patient could able to walk on second day postoperatively and it was full weight bearing after bandage removal at 3rd week. Also on 3rd week radiographs, fracture callus formation were evaluated as adequate and hip stabilisation was excellent. Any postoperative complication was not observed.

Keywords: Cat, Coxofemoral luxation, Toggle pin, Salter Harris

ÖZ

Bir Kedide Koksofemoral Luksasyon ve Tip-1 Salter Harris Femur Kırığının Toggle Pin ve Cross Pin Yöntemleriyle Sağaltımı

Vakayı 5 aylık, 1 kg ağırlığında, melez erkek bir kedi oluşturdu. Radyografide sağ koksofemoral çıkık ve sağ Salter Harris Tip-1 femur kırığı belirlendi. Kalça çıkığında Toggle pin ve Tip-1 Salter Harris femur kırığında çapraz pin yöntemleri ile fiksasyon uygulandı. Öncelikle oluşturulan asetabular tünelden pelvis boşluğuna Toggle pin yerleştirildi. Takiben femoral tünel oluşturularak Toggle pine bağlı 0.5 mm çaplı monofilament naylon ipin uçları bu tünelden geçirildi ve caput femoris asetabulumuna yerleştirilerek eklem hareketi kontrol edildi. Son olarak ipin uçları trohanter mayörün kaudolateral açısında düğümlenerek sabitlendi. Tip-1 Salter Harris femur kırığında kranio lateral yaklaşım ile diz eklemine ulaşıldı. Femurun distal bölümü açığa çıkarılarak 2-3.2 mm çaplı pinler ile mediyal ve lateral kondüllerden femura çapraz çivileme ile fiksasyon yapıldı. Ameliyat sonrasında arka bacak alüminyum atelli bandaj ile desteklendi ve kalça bölgesi yumuşak bandaj ile korundu. Rutin postoperatif ilaç uygulamaları bir hafta süreyle yapıldı ve destekli bandaj 3 hafta sonra çıkarıldı. Hastanın ameliyattan sonraki ikinci günde yürüyebildiği ve 3 hafta sonra bandaj uzaklaştırıldığında tam ağırlık vererek basabildiği gözlemlendi. Aynı zamanda 3 hafta sonraki radyografilerde kırık kallus oluşumunun yeterli düzeyde ve kalça eklemi stabilizasyonunun çok iyi olduğu değerlendirildi. Postoperatif herhangi bir komplikasyona rastlanmadı.

Anahtar Kelimeler: Kedi, Koksofemoral luksasyon, Toggle pin, Salter Harris

INTRODUCTION

Hip luxations occurs due to tear of ligamentum ossis capitis femoris that inserting to fovea capitis. Although it is most common treatment method, relaxation may occur in

%50-70 of cases that treated with closed reduction (Trostel et al. 2000). Various methods have been described for open reduction as intraarticular and extraarticular (Lubbe and Verstraete 1990; Trostel et al. 2000; Martini et al. 2001; Demko et al. 2006; Çetinkaya and Olcay 2011;

Tamburro et al. 2013; Ergin et al. 2016). Toggle pin method has been described in 1953 by Knowles as an intraarticular technique (Piermattei et al. 2006) and it's positive results have been reported (Çetinkaya and Olcay 2011; Tamburro et al. 2013; Ergin et al. 2016).

Salter-Harris fractures includes epiphyseal region of bone and it's described five type of Salter-Harris fracture. Most common type of Salter-Harris fracture is Type-1 in cats (Kaya and Candaş, 2000). It is used Steinmann pins, intramedullary pin, cross pin, double pins intersecting at one point and Rush pin-like application methods for treatment of Type-1 Salter-Harris fractures (Çağatay and Sağlam, 2013). It was evaluated treatment with cross pin and toggle pin methods performed to a cat that femur fractured and hip luxated in the same hindlimb in this case report.

CASE HISTORY

In the present case; a five months aged, one kg in weight, mixed breed male cat that has it's right hindlimb dysfunctional for a day, because of falling from highrise, was evaluated for diagnosis and treatment. Lameness, anormal mobility and crepitation of femoral and hip regions were determined in clinical examination. Radiographs revealed a Type-1 Salter-Harris supracondylary femur fracture and craniodorsal luxation of right coxofemoral joint (Figure 1 a,b). It was planned toggle pin and cross pin methods for treatment of hip luxation and femure fracture respectively.

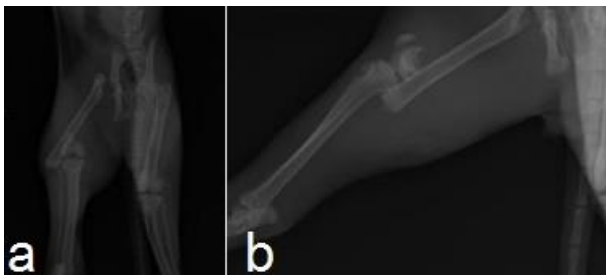

Figure 1. a) Preoperative VD radiograph, b) Preoperative ML radiograph

General anesthesia was provided with combination of xylazine HCl (Alfazyne®, Egevet 20 mg/ml) 2 mg/kg IM and ketamine HCl (Alfamine®, Egevet 100 mg/ml) 10 mg/kg IM. It was used craniolateral approach in order to expose coxofemoral joint. Remains of torn ligamentum capitis ossis femoris were removed. Then the acetabular tunnel created from the point that ligamentum teres originated into pelvic cavity with a drill 3.5 mm in diameter. From this hole; a 1 cm in length toggle pin that made of 0.5 mm diameter Kirschner wire according to Modified Knowles technique (Piermattei ve ark. 2006) was placed into the pelvic cavity with 0.5 mm diameter monofilament nylon rope (Oskar KYOTO DIL®, max. resistance ~31kg) (Figure 2 a,b). Placement of toggle pin is checked by pulling the double parts of rope together. Then, the caput femoris externally rotated and femoral tunnel was created with a 2 mm diameter drill by retrograde orientation from fovea capitis to caudolateral of trochanter major. After inserting of the ropes retrogradely to this tunnel, joint reduction was made. Then the rope was tightened by pulling and the joint was stabilised as tight as to able to do normal joint movements. Finally; a 1 mm diameter hole was opened to the trochanter major transversally and the toggle pin application was completed with fixation of reciprocating inserted of the ropes.

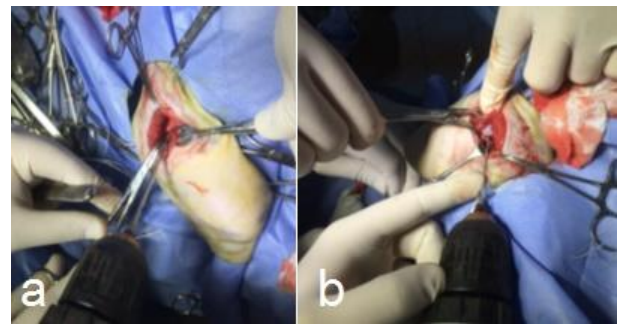


Figure 2. a) Acetabular tunnel application, b) Femoral tunnel application

A craniolateral approach was used in order to expose the knee joint and distal part of femur and reduction has been established. Fixation achieved by performing a 3.2 mm diameter pin from lateral epicondylus to medial cortex of distal femur and a 2 mm diameter pin from medial epicondyle to lateral cortex (Figure 3 a,b).

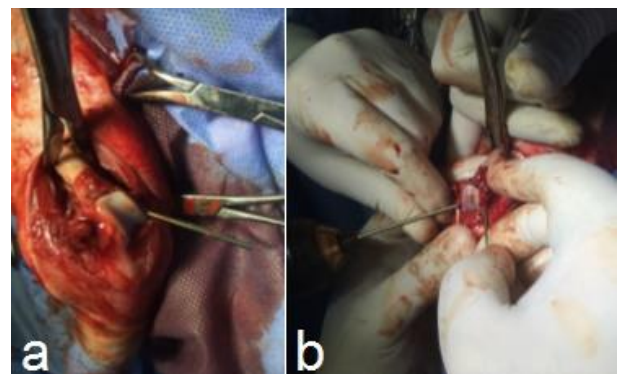


Figure 3. a,b) Cross pin application

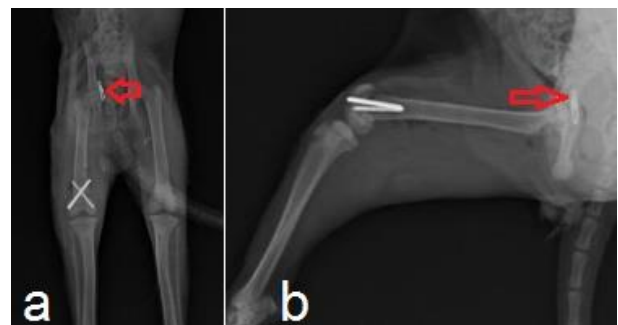

Figure 4. a) Postoperative VD radiograph, b) Postoperative ML radiograph

Postoperative control radiography was performed (Figure 4 a,b). The distal femur fracture fixation supported with aluminium splint bandage and the hip was covered with soft bandage. Cefazolin sodium (Sefazol®, Mustafa Nevzat, Turkey) 22 mg/kg/12 hour IM postoperatively for seven days and Tolfenamic acide tablets (Tolfedine®, Novakim, Turkey) 4 mg/kg/day for five days orally. The bandage removed after three weeks postoperatively and 3rd week radiographs were taken. Fracture healing and callus formation were evaluated as adequate. Hip stabilisation was also excellent (Figure 5 a,b). The patient could able to walk on second day postoperatively and it was full weight bearing after bandage removal at 3rd week. There was no complication in early and long term period.

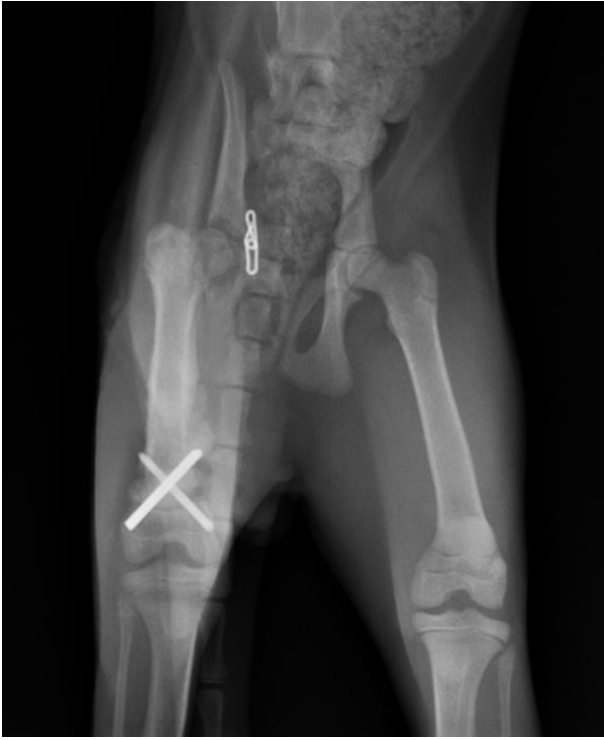


Figure 5a. Postoperative 3rd week VD radiograph

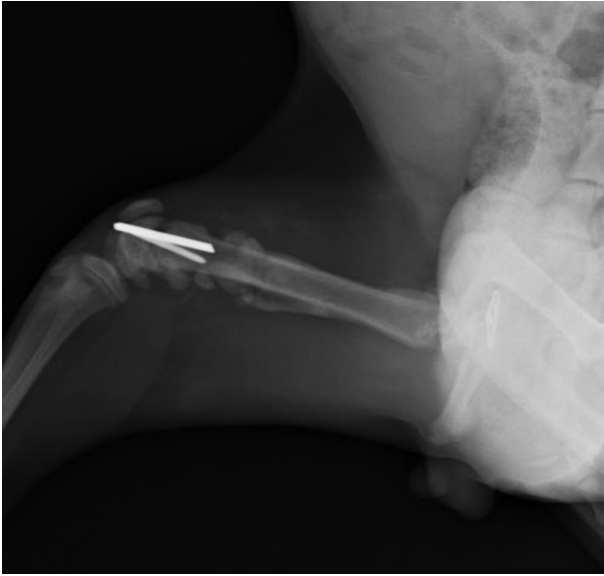

Figure 5b. Postoperative 3rd week ML radiograph

DISCUSSION and CONCLUSION

Hip luxation is one of the most common traumatic luxation type in small animal practice and mostly occurs craniodorsally (Çetinkaya and Olcay 2011). In the present case, the coxofemoral luxation was occurred craniodorsally too. Additionally, a concurrent Type-1 Salter-Harris femur fracture was determined on the same hindlimb. Choosing the appropriate method is important for the prognosis as the supracondylar femur fractures do not prevent the

continuation of the growth period (Çağatay and Sağlam 2013). In a study of force endurance measurements, it was determined that the most resistant method was cross pin in other methods that used in Type-1 Salter-Harris fractures (Sukhiani et al. 1997). Also in the present case, successful treatment was achieved with complete reduction and stabilization when the cross pin method was preferred. It was confirmed by observing of adequate callus formation at fracture site and the hip joint not relaxed radiographs on postoperative 3rd week.

It has been reported, the most common complication is relaxation due to breakdown of used material in the toggle pin technique and it occurs mostly 2nd-8th weeks (Demko et al. 2006; Çetinkaya and Olcay 2011). Similar studies have reported that if there is no any concurrent orthopaedic or general problem, the patient starts to full weight bearing at second day postoperatively (Çetinkaya and Olcay 2011; Tamburro et al. 2013; Ergin et al. 2016). However, the full weight bearing may be prolonged if there is any orthopaedic or general disease (Ergin et al. 2016). In the present case, there was no complication in postoperative period and the patient was walking with full weight bearing after bandage removal immediately. Also, it was seen no complication at 5th month check up.

In conclusion, cross pin and toggle pin methods were found to be a cheap and practical method combination for clinician veterinarians in cases of concurrent femur fracture and hip luxation in the same hindlimb.

REFERENCES

- Çağatay S, Sağlam M (2013). Clinical and radiographical assessments of treatment of Salter-Harris type fractures in cat and dog. *Ankara Üniv Vet Fak Derg*, 60:109-116.
- Çetinkaya MA, Olcay B (2011). Köpek ve kedilerde koksofemoral eklem luksasyonlarının sağaltımında monofilament naylon dikiş materyali ile toggle pin uygulamaları ve klinik değerlendirmeleri üzerine çalışmalar. *Ankara Üniv Vet Fak Derg*, 58:167-174.
- Demko JL, Sidaway BK, Thieman KM, Fox DB (2006). Toggle rod stabilization for treatment of hip joint luxation in dogs: 62 cases (2000-2005). *J Am Vet Med Assoc*, 229:984-989.
- Ergin I, Senel OO, Ozdemir O, Ulsan S, Bilgili H (2016). Treatment of Coxofemoral Luxations by Double-sided Modified Toggle Pin Technique and Assessment of Early Results in Cats: 17 Cases. *Ankara Üniv Vet Fak Derg*, 63(2): 121-126.
- Kaya Ü, Candaş A (2000). Operative management of medial condylar fracture of femur (Salter-Harris Type III) in two dogs. *Ankara Üniv Vet Fak Derg*, 47:237-241.
- Lubbe AM, Verstraete FJM (1990). Fascia lata loop stabilization of the coxofemoral joint in the dog and cat. *J Small Anim Pract*, 31:234-238.
- Martini FM, Simonazzi B, Del Bue M (2001). Extra-articular absorbable suture stabilization of coxofemoral luxation in dogs. *Vet Surg*, 30:468-475.
- Piermattei DL, Flo GL, DeCamp CE (2006). The Hip Joint. In: (Editors: Piermattei DL, Flo GL, DeCamp CE) *Handbook of Small Animal Orthopedics and Fracture Repair*. 4th ed. Philadelphia: W.B. Saunders Co. pp 461-511.
- Sukhiani HR, Holmberg DL (1997). Ex vivo biomechanical comparison of pin fixation techniques for canine distal femoral physeal fractures. *Vet Surg*, 26:398-407.
- Tamburro R, Carli F, Cinti F, Puggioni A, Venturini A (2013). Caudal approach and Mini TightRope system (mTR) application for the treatment of craniodorsal hip luxation in a cat: a case report. *Vet Med-Czech*, 58(9):500-504.
- Trostel CT, Peck JN, De Haan JJ (2000). Spontaneous bilateral coxofemoral luxation in four dogs. *J Am Anim Hosp Assoc*, 36:268-276.