

Gingival vascular hamartoma in a calf

M. Yavuz GÜLBAHAR¹

Loğman ASLAN²

İsmail ALKAN²

¹ Yüzüncü Yıl Üniversitesi, Veteriner Fakültesi, Patoloji Anabilim Dalı-VAN

² Yüzüncü Yıl Üniversitesi, Veteriner Fakültesi, Cerrahi Anabilim Dalı-VAN

SUMMARY

This report describes gingival vascular hamartoma, a rare vascular lesion in a 2-month-old male Simmental calf. The pink-red, ulcerated, cauliflower-like mass measured 3x4x5 cm in incisor region of the mandibular gingiva composed of numerous thin-walled disorganized capillaries lined by plump endothelial cells having rounded or spindle-shaped nuclei. Treatment consisted of surgical excision followed by thermocautery.

Key words: Vascular hamartoma, Gingiva, Calf.

Bir buzağında gingival vasküler hamartom olgusu

ÖZET

Bu çalışmada, 2 aylık erkek Simmental bir buzağının gingivasında rastlanan vasküler hamartom olgusu tanımlanmaktadır. Buzağının alt çenesinde incisor bölgede pembe-kırmızı renkte, karnabahar benzeri, 3x4x5 cm boyutunda ve yüzeyi ülserli bir kitle ile karşılaşıldı. Kitlenin mikroskopik incelenmesinde, yuvarlak veya fusiform nukleusu olan, şişkin endotel hücrelerinin çevrelediği çok sayıda ince duvarlı kapillar damarlar dikkati çekti. Olgunun sağaltımı cerrahi müdahaleyi takiben koterizasyon ile yapıldı.

Anahtar kelimeler: Vasküler Hamartom, Gingiva, Buzağı.

The hamartoma is a rare malformation that presents as mass of disorganized tissue indigenous to the particular site (9). Although the cellular components of a hamartoma are normal, there is a loss of regular growth, often resulting in a disorganized accumulation of cells (21). It has been considered that the lesion is a form of congenital anomaly rather than true neoplasm (7,9,17). Hamartomas are present at birth and grow with the individual (7). They may be composed of epithelial, mesenchymal or a combination of both cell types. Because vascular tissue is ubiquitous, vascular hamartomas may occur at any sites of the body (9). Vascular hamartomas have been reported in various locations in cattle (2,5,10,16,19,21), goat (11), dog (3,15), cat (13) and horse (14).

Gingival vascular hamartomas are rare congenital anomalies that occur on the gum of young calves (7). The present case report describes gingival vascular hamartoma in a calf.

CASE REPORT

A 2-month-old Simmental bull calf was admitted for pink-red, lobulated, ulcerated and cauliflower-like, hemorrhagic gingival mass to Faculty of Veterinary Medicine, University of Yüzüncü Yıl. The mass measured 3x4x5 cm was located in the labial surface of left mandibular gingiva the level of the second incisor tooth. It was noticed a dislocation to labial direction of incisor tooth, which was totally embedded into this mass (Fig.1). The calf exhibited clinical signs such as excessive salivation and strenuously nursing. According to anamnesis, the progressively growing

hemorrhagic gingival mass measured approximately 1-2 cm in diameter had first noticed by the owner at 10 days of age. The calf was referred to a local veterinarian at 30 days of age and the mass measured 3-4 cm in diameter was removed surgically by the veterinarian. The owner noted secondary regrowth in the same region at 10th days post-operation. The mass with broad margins and second incisor tooth were again surgically removed under general anesthesia with intramuscularly 0,2 mg/kg xylazine hydrochloride (Rompun®) followed by thermocautery and fixed in 10% buffered formalin. The incisor tooth removed was decalcified in 5% nitric acid solution. After embedding in paraffin wax, 5 µm thick sections were stained with hematoxylin-eosin (HE) and Masson's trichrome.

Microscopically, the mass consisted of numerous thin-walled disorganized capillaries lined by plump endothelial cells having rounded or spindle-shaped nuclei. Some capillaries showed indistinct lumina and occasionally, scattered cell or cell groups showing morphological characteristics similar to the endothelial cells were present. Most well-formed capillaries of variable diameter were empty or collapsed but, a small number contained erythrocytes or a proteinic fluid. Scant fibrous tissue among these vessels was also present (Fig. 2 and 3). In some sections, the hyperplastic mucosal epithelium showed superficial ulceration characterized by partial loss of the epithelium, bacterial colonies, neutrophil leucocytes, thrombosis of some large vessels and minimal hemorrhage. The architecture of the second incisor tooth was normal in appearance.

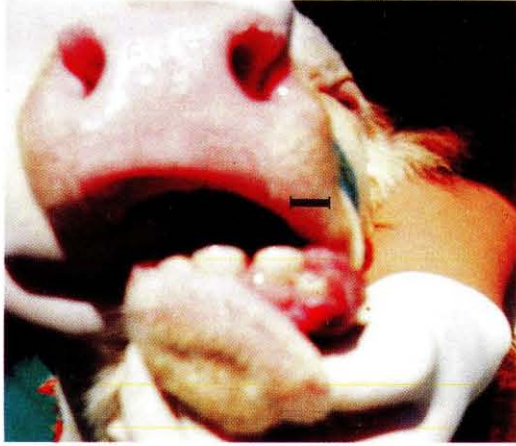

Figure 1. The pink-red cauliflower-like mass in incisor region of the mandibular gingiva of calf. Note the dislocation of incisor tooth embedded into tumoral mass. Bar: 1 cm.

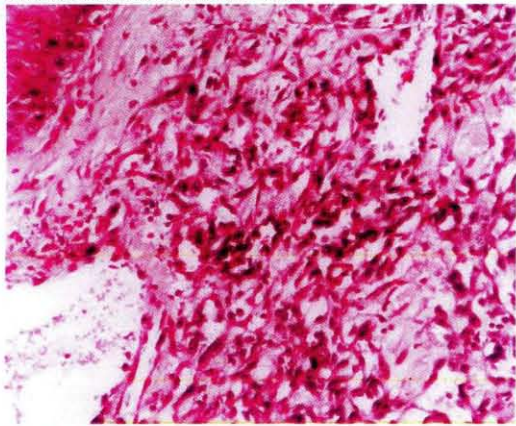


Figure 2. The numerous capillaries among the scant fibrous stroma. HE, x200.

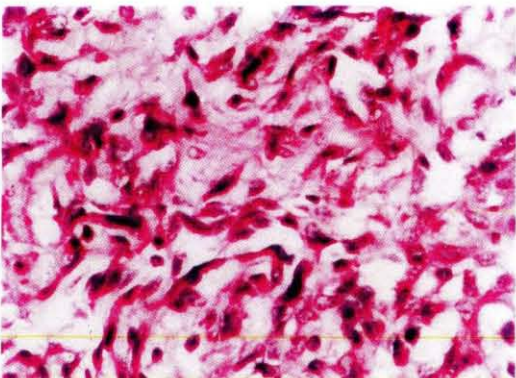


Figure 3. Vascular channels lined by plump endothelial cells having round or spindle nuclei. Note scattered cell or cell groups that were not formed vessel lumens. HE, x400.

DISCUSSION

There are some reports of bovine congenital or juvenil vascular lesions in variety of tissues, including skin and tongue (8), skin (12), meninges and kidney (5), spinal cord (2), testis (19), ovarium (10), gingiva (4, 6, 16-18, 20, 21) and disseminated throughout the body (1). The vascular congenital lesion described here reflect a distinct entity based on its predilection for gingiva as well as the previously cited reports. The higher incidence of congenital or vascular lesions in the gingiva of calves other than the species remains to be unclear. Considerable controversy still exists about the nature of vascular congenital lesions whether it represents a true neoplasm or tumor-like malformation or a vasoproliferative lesion that is secondary to chronic localized infection (7,9,12). Previous reports reflect inconsistencies in the nomenclature regarding congenital vascular growth in man and animals. Morphologically, similar lesions described in calves have been described as hamartomas in some reports (16,17,21) whereas in others they have been reported as vascular neoplasia (4,6,8,20). The features of these vascular lesions also are compatible with human pyogenic granuloma (lobular capillary hemangioma) and pregnancy tumor (9). Given the age of this calf and based upon the presence of disorganized capillaries that demonstrated overgrowth somewhat coordinated with that of surrounding tissue (7,21), the lesion described here was also diagnosed as gingival vascular hamartoma. Despite pathogenetic interest, these distinctions are of little practical importance (7). Whichever, the common lesions described are uniformly benign and sometimes may well regress or disappear spontaneously (7,9,20). However, dislocation or loss of teeth (16,17) or bony changes (17) were reported in calves with gingival vascular hamartomas. Moreover, paraparesis of hindlimbs due to thoracic vascular hamartoma in a young goat (11) and paraneoplastic hyperglycemia associated with a gingival hamartoma in a kitten (13) were reported. No discomforting condition in the present case, with exception of dislocation of incisor tooth and clinical signs mentioned, was observed. Treatment of hamartomas or similar vascular lesions consist of surgical excision followed by cryotherapy or thermocautery (16,17, 20, 21). Because of regrowth of the some gingival vascular hamartomas following excision, it has been advisable cryotherapy or thermocautery to be effective in preventing recurrence of lesion (16,17,21). Although the recurrence of lesion in the present case was observed 10 days after first surgical excision, regrowth has not been observed after second excision followed by thermocautery.

REFERENCES

- 1-Baker J.C, Huttgren B.D, Larson V.L (1982): Disseminated cavernous hemangioma in a calf. J Am Vet Med Assoc; 181: 172-173.
- 2-Cho CY, Cook JE, Leipold HW (1979): Angiomatous vascular malformation in the spinal cord of a hereford calf. Vet Pathol; 16: 613-616.
- 3-Cordy DR. (1979): Vascular malformations and hamangiomas of the canine spinal cord. Vet Pathol; 10: 12-15.

- 4-Gaag I van der, vos JH, Goedegebuure SA (1988):** Lobular capillary haemangiomas in two calves. *J Comp Pathol*; 99: 353-356.
- 5-Hodgin EC (1985):** Menigeal hemangioma and renal hamartoma in a heifer. *Vet Pathol*; 22: 420-421.
- 6-Iselin U, Lischer CJ, Lott-Stolz G, Kaser-Hotz B (1995):** Capillary hemangioma, rare neoplasia in a calf. *Schweiz Arch Tierheilkd.*; 137: 87-91.
- 7-Jubb KVF, Kennedy PC, Palmer N. (1993):** *Pathology of Domestic Animals*, 4th ed., Academic Press, Inc., New York.
- 8-Kirkbride CA, Bicknell EJ, Robl MG (1973):** Hemangioma of a bovine fetus with a chorioangioma of the placenta. *Vet Pathol*; 10: 238-240.
- 9-Kumar V, Cotran, RS, Robbins SL (1992):** *Basic Pathology*, 5th ed., WB Saunders Company, Philadelphia.
- 10-Lee CG, Ladds PW (1976):** Vascular hamartoma of the ovary in a cow. *Aust Vet J*; 52: 236.
- 11-Middleton JR, Valdez R, Britt LG, Parish SM, Tyler JW (1999):** Progressive hindlimb paraparesis in a goat associated with a vascular hamartoma. *Vet Rec*; 144: 264-265.
- 12-Misdrop W (1965):** Tumors in newborn animals. *Pathol Vet*; 2: 328-343.
- 13-Padgett SL, Tillson DM, Henry CJ, Buss MS (1997):** Gingival vascular hamartoma with associated paraneoplastic hyperglycemia in a kitten. *J Am Vet Med Assoc*; 210: 914-915.
- 14-Rhyan JC, D'Andrea GH, Smith L.S (1981):** Congenital ovarian vascular hamartoma in a horse. *Vet Pathol*; 18: 131.
- 15-Roudebush P, MacDonald JM (1984):** Mucocutaneous angiomatous hamartoma in a dog. *J Am Anim Hosp Assoc*; 20: 168-170.
- 16-Sheahan BJ, Donnelly WJC (1981):** Vascular hamartomas in the gingiva of two calves. *Vet Pathol*; 18: 562-564.
- 17-Stanton ME, Meunier PC, Smith DF (1984):** Vascular hamartoma in the gingiva of two neonatal calves. *J Am Vet. Med. Assoc*; 184: 205-206.
- 18-Tontis A (1994):** Congenital cavernous hemangioma in a brown Swiss calf, a rare oral blastoma. Case report. *Tierarztl Prax*; 22: 137-139.
- 19-Tyler JW, Hassel DM, Long MT, Henry CJ, Parish SM (1995):** Testicular vascular hamartoma in a calf. *Vet Rec*; 136: 420.
- 20-Von JE Renner, Montesinos IG, Ottino JF (1995):** Spontaneous remission of presumably hemangiomas at the mandibular symphysis in calves. *Dtsch Tierärztl Wschr*; 102: 212-213.
- 21-Wilson RB (1990):** Gingival vascular hamartoma in three calves. *J Vet Diagn Invest*; 2: 338-339.