

Left-sided malignant pleural mesothelioma presenting with recurrent pneumothorax 7 years after the right pleuropneumectomy

Umit Aydogmus¹, Erhan Ugurlu², Figen Turk¹, Gokhan Yuncu³

¹Department of Thoracic Surgery, Pamukkale University School of Medicine, Denizli, Turkey

²Department of Chest Diseases, Pamukkale University School of Medicine, Denizli, Turkey

³Department of Thoracic Surgery, Liv Hospital, Istanbul, Turkey

ABSTRACT

Malignant pleural mesothelioma (MPM) is an extremely aggressive tumor arising from the pleura with a median survival of approximately 9–12 months. It can rarely present as a spontaneous pneumothorax. We herein reported a 65-year-old female patient with the left-sided MPM presenting with episodes of recurrent spontaneous pneumothorax. She had undergone the right pleuropneumectomy due to the right-side MPM 7 years ago. She admitted to our clinic with diagnosis of left pleural effusion. The patient underwent pleural biopsy and talc pleurodesis by thoracoscopy. Histologic study showed the epithelial subtype of MPM. She received chemotherapy nine times. Seven years after pleuropneumectomy, she had recurrent left-sided spontaneous pneumothorax four times that was treated one by one with tube thoracostomy. We did not perform surgical treatment because of the unsuitable status of the patient. It should be kept in mind that, when pneumothorax develops in the remaining lung after a single-sided pneumonectomy, this may be due to the tumor.

Eur Res J 2016;2(3):240-243

Keywords: Recurrent pneumothorax; pleuropneumectomy; malignant pleural mesothelioma

Introduction

Malignant pleural mesothelioma (MPM) is almost always a fatal disease, its prognosis being affected by oncologic treatments to a limited extent [1]. Moreover, the diagnosis of MPM is usually delayed because its symptoms and findings are not specific [2]. Additionally, there are various difficulties in the

pathological diagnosis of MPM [1-3]. MPM continues being a disease that challenges modern medicine in all aspects. We present here a case with MPM, an example of which is not available in the literature due to its unique clinical progress and treatment difficulties.

Address for correspondence:

Erhan Ugurlu, MD., Pamukkale University School of Medicine, Department of Chest Diseases, 20020 Denizli, Turkey

E-mail: drerhanugurlu@gmail.com

Received: November 05, 2015; Accepted: December 17, 2016; Published Online: August 01, 2016

Case Presentation

A 65-year-old female patient admitted to the thoracic clinic with the complaints of chest pain and shortness of breath in another center 10 years ago. She did not have any exposure to asbestos in her personal history and she did not smoke. She also did not have any serious disease. Right hydrothorax was seen in lung x-ray. Computerized tomography (CT) showed a pleural thickening of nodular type on the right side (Figure 1). CT findings did not involve any pulmonary parenchymal invasion or any other important sign.

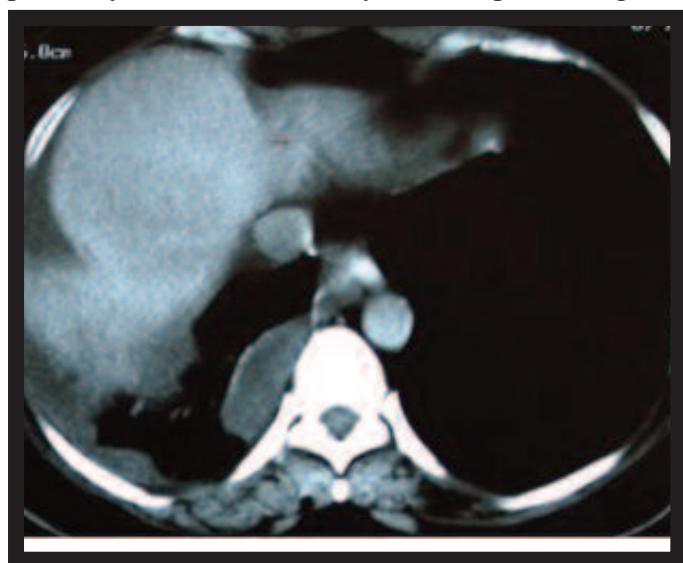


Figure 1. A pleural thickening of nodular type on the right side before extrapleural pneumonectomy operation

Pleural fluid was of exudative type and a videothoroscopic pleural biopsy was performed. Pathology resulted in an epithelial subtype of MPM.

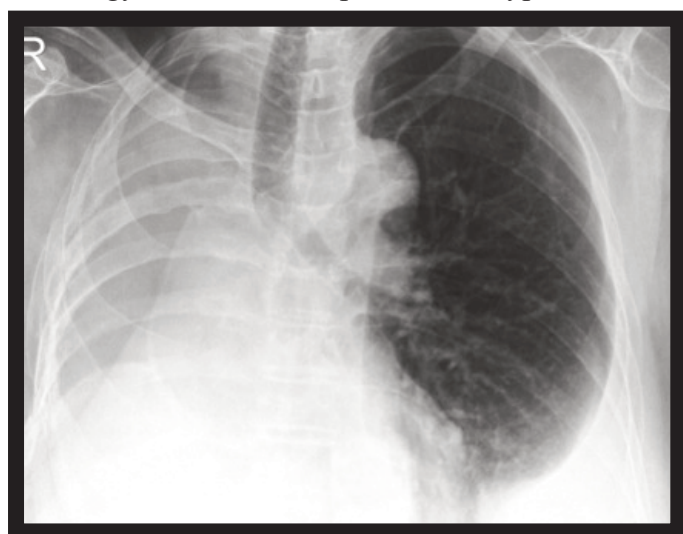


Figure 2. A left side pleurisy

Thoracic magnetic resonance imaging and upper abdominal ultrasound did not show any invasion to the underneath of diaphragm. She had undergone a

pleurectomy, but a year later she developed a local relapse and then she underwent an extrapleural pneumonectomy operation. The patient was operated once more 5 years after the extrapleural pneumonectomy due to mucinous ovarian carcinoma and 6 months after this operation she had a left side pleurisy (Figure 2).

The patient was referred to our clinic. With the initial diagnosis of malignant pleural effusion, a pleural biopsy through a left thoracoscopy under local anesthesia was performed and she underwent a chemical pleurodesis through a sterile talk insufflation. The histologic and immunohistochemical analysis of the pleural biopsy showed an epithelial subtype of MPM (Figures 3 and 4). She was administered 9 cycles of chemotherapy due to left side pleural mesothelioma.

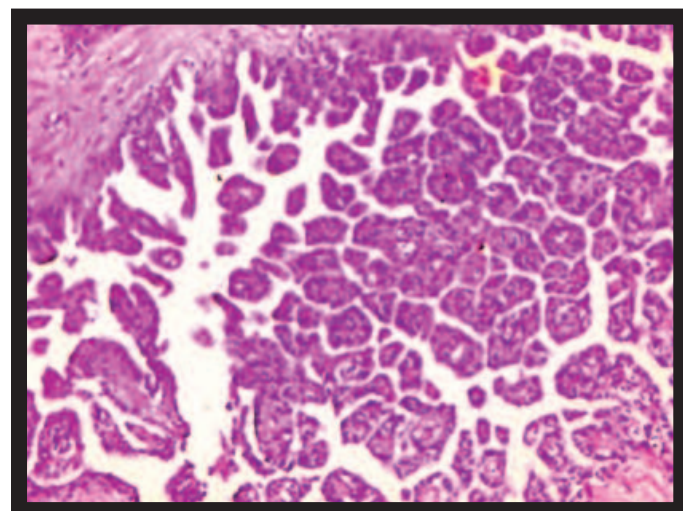


Figure 3. Malignant tumor consisting of papillary proliferation of prominent eosinophilic cytoplasm, vesicular nuclei, prominent nucleoli epithelioid cells. X20, H&E

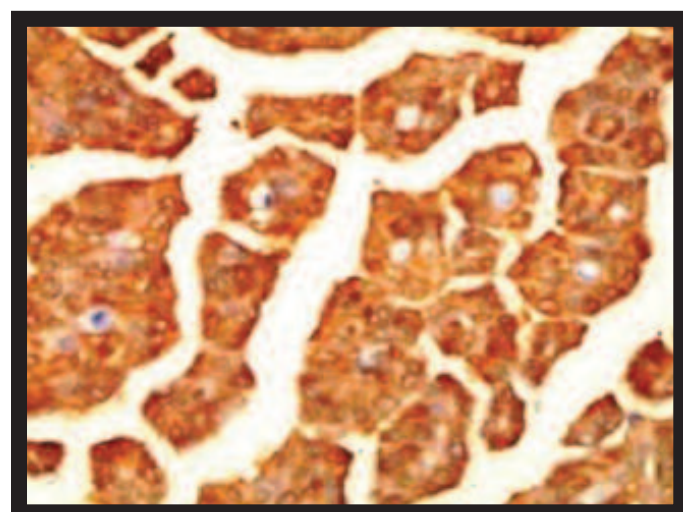


Figure 4. Positivity of calretinin for immunohistochemical X20, IHK.

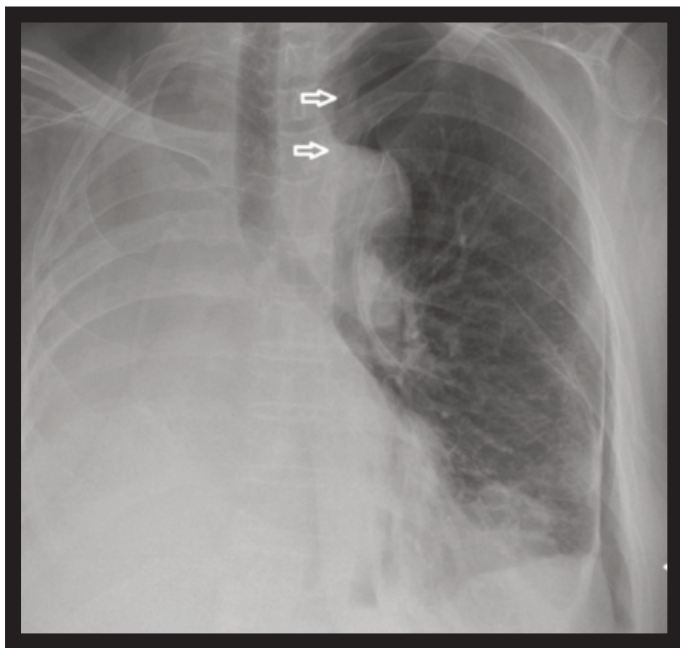


Figure 5. A spontaneous pneumothorax (arrows) attack

She had a spontaneous pneumothorax attack 7 years after the right pleuropneumectomy even though a chemical pleurodesis had been administered to the left side (Figure 5). During the following 2 years, she had 4 spontaneous pneumothorax attacks, which were treated with a tube thoracotomy each. The last pneumothorax attack lasted 23 days and had an ambulatory treatment with a Heimlich valve. The general condition of the patient was not suitable for a surgical intervention.

The patient is still alive in the 11th year of her first diagnosis and she has MPM in her left hemithorax and mucinous ovarian carcinoma-related metastases in her abdomen.

Discussion

According to many authors, MPM is inevitably fatal [4]. There is no randomized study where a neoadjuvant or adjuvant chemotherapy treatment approach is tested for MPM and the relative contributions of chemotherapy and/or radiotherapy given before or after a cytoreductive surgery are not very well known [1]. Sugarbaker *et al.* [5] have shown that the extrapleural lymph node involvement, surgical margin and cell type are associated with survival after an extrapleural pneumonectomy. Nakas and Walker [4] have reported that survival is good in those who had no nodal involvements, who were at stage T1-2, and who had epithelioid cells. Our patient had good

prognostic criteria as previously defined.

Bilateral MPM does not seen very often. Okten *et al.* [2] have reported the rate of bilateral MPM of 1.9%. A bilateral MPM may occur if the tumor directly spreads into the contralateral hemithorax along the mediastinum [6]. In our patient, a left side MPM was found 8 years after the first diagnosis of the right side and there was no recurrence at that time. This situation can be considered as a distant metastasis through the blood; it could also be a second primary MPM since it occurred 8 years after the treatment of the first tumor. Nevertheless, there are many markers, both clinical and biological, of prognosis in MPM [7]. The MPM in our patient seemed to be a very slow progressing biological subtype and with the advancement of the first MPM, the disease in the left hemithorax may be occurred.

The mechanism of pneumothorax is not clear in patients with MPM, but it has been argued that it can develop as a result of the rupture of necrotic tumor nodules [8]. There are very few MPM cases presented with pneumothorax in the literature [7, 8]. This is the first case report involving a patient who had a MPM-related recurrent pneumothorax that developed in the remaining lung years after the EPP of the other side. Our patient, who had 4 recurrences in 2 years despite the pleurodesis she went through, was finally treated with tube thoracostomy.

Conclusion

In conclusion, we presented here an interesting patient who is still alive 11 years after her first diagnosis and who had recurrent pneumothorax attacks in her other lung following an extrapleural pneumonectomy. It should be kept in mind that when pneumothorax develops in the remaining lung after a single side pneumonectomy, this may be due to the tumor. The treatment of patients who develop a tumor-related pneumothorax after a pneumonectomy is difficult to handle.

Informed Consent

Written informed consent was obtained from the patient for the publication of this case report.

Conflict of interest

The authors declared that there are no potential conflicts of interest with respect to the research, authorship, and/or publication of this article.

References

- [1] van Zandwijk N, Clarke C, Henderson D, Musk AW, Fong K, Nowak A, et al. Guidelines for the diagnosis and treatment of malignant pleural mesothelioma. *J Thorac Dis* 2013;5:E254-307.
- [2] Okten F, Koksall D, Onal M, Ozcan A, Simsek C, Erturk H. Computed tomography findings in 66 patients with malignant pleural mesothelioma due to environmental exposure to asbestos. *Clin Imaging* 2006;30:177-80.
- [3] Henderson DW, Shilkin KB, Whitaker D. Reactive mesothelial hyperplasia vs mesothelioma, including mesothelioma in situ: a brief review. *Am J Clin Pathol* 1998;110:397-404.
- [4] Nakas A, Waller D. Predictors of long-term survival following radical surgery for malignant pleural mesothelioma. *Eur J Cardiothorac Surg* 2014;46:380-5; discussion 385.
- [5] Sugarbaker DJ, Flores RM, Jaklitsch MT, Richards WG, Strauss GM, Corson JM, et al. Resection margins, extrapleural nodal status, and cell type determine postoperative long-term survival in trimodality therapy of malignant pleural mesothelioma: results in 183 patients. *J Thorac Cardiovasc Surg* 1999;117:54-63; discussion 63-5.
- [6] Aziz F. Radiological findings in a case of advance staged mesothelioma. *J Thorac Dis* 2009;1:46-7.
- [7] Prasad A, Olsen D, Sriram PS. Malignant mesothelioma presenting as a gradually enlarging pneumothorax. *Case Rep Pulmonol* 2013;2013:374960.
- [8] Saleh HZ, Fontaine E, Elsayed H. Malignant pleural mesothelioma presenting with a spontaneous hydropneumothorax: a report of 2 cases. *Rev Port Pneumol* 2012;18:93-5.