

ENDODONTIC TREATMENT OF INVAGINATED CANAL WITH MTA AND A VITAL PULP WITH TYPE 3 DENS INVAGINATUS : 2-YEAR FOLLOW UP CASE REPORT*

İNVAJİNE KANALA MTA İLE ENDODONTİK TEDAVİ VE VİTAL PULPALI TİP 3 DENS İNVAJİNATUS: 2 YIL TAKİPLİ OLGU RAPORU

Uzm. Dt. Aycan DAL*

Doç. Dr. Çağdaş ÇINAR*

Makale Kodu/Article code: 4192
Makale Gönderilme tarihi: 24.10.2019
Kabul Tarihi: 10.04.2020
DOI : 10.17567/ataunifd.717983

Aycan Dal: ORCID ID: 0000-0002-5876-4586
Çağdaş Çınar: ORCID ID: 0000-0002-0764-6387

ABSTRACT

Dens invaginatus type 3, a severe form extending beyond the cemento-enamel junction and exhibiting a second foramen into the lateral periodontal ligament or periradicular tissue. This anomaly may involve the periradicular tissue and cause pulpal necrosis and periradicular lesions.

An 11-year-old female patient was presented with slight swelling and periodic pus drainage from buccal gingiva of the maxillary left lateral incisor as her main complaint. Tooth had no pain on percussion or palpation, no color change, no caries and no mobility. Radiographic examination revealed that there was a radiolucent area on the mesial side of the coronal root. It was observed that this radiolucency was associated with apex of dens invaginatus. Because of continuous drainage through the canal, calcium hydroxide was replaced after 1 week with irrigated NaOCl. The drainage was under control after 3 weeks. Root canal treatment was applied to the malformed area by filling only the invaginated canal completely with MTA. Cavity was restored with light-cured resin composite.

Main pulp was kept vital and 2 years follow up showed periapical repair and absence of clinical symptoms. The patient was remained asymptomatic and pulp vitality was continued.

Dens invaginatus is a dental malformation, which has a complicated treatment because of the complex root canal anatomy. It is very important to be able to identify and treat this dental malformation correctly.

Keywords: dens invaginatus; maxillary lateral incisor; periradicular lesion; MTA

ÖZ

Dens invaginatus tip 3, semento-enamel bileşkenin ötesine uzanan ve lateral periodontal ligament veya periradiküler dokuya ikinci bir foramen ile açılan şiddetli bir malformasyondur. Bu anomali, pulpal nekroz ve periradiküler lezyonlara neden olabilir.

On bir yaşında kız çocuk hasta maksiller sol lateral kesici dişinin bukkal dişeti bölgesindeki şişlik ve püy drenajı şikayetiyle başvurdu. Yapılan ilk muayenede dişte perküsyona ya da palpasyona hassasiyet, renk değişikliği, çürük ve mobilite gözlenmedi. Radyografik incelemede koronal kökün mezial tarafında radyolüsent bir alan olduğu görüldü. Bu radyolüsent alanın dens invaginatusun apeksiyle ilişkili olduğu gözlemlendi. İnvajine kanaldan devam eden püy drenajı nedeniyle NaOCl ile irigasyon yapıldı ve kanalda 1 hafta kalsiyum hidroksit bekletildi. Drenaj 3 haftanın sonunda kontrol altına alındı. Tip 3 dens invaginatus tanısıyla tedaviye başlanan hastanın yalnızca invajine kanalı, MTA ile tümüyle doldurularak malforme bölgeye kök kanal tedavisi uygulandı. Üst yapı, ışıkla sertleşen kompozit rezinle restore edildi.

Ana pulpanın vital kalması ve 2 yıllık takipte periapikal onarım sağlandı ve klinik semptomların yokluğu gösterildi. Hasta asemptomatikken, pulpanın canlılığının devamı sağlandı.

Dens invaginatus, karmaşık kök kanal anatomisi nedeniyle karmaşık bir tedavisi olan dental bir deformasyondur. Bu dental deformasyonu doğru tanımlayabilmek ve doğru tedavi edebilmek önem taşımaktadır.

Anahtar Kelimeler: dens invaginatus; maksiller lateral keser; periradiküler lezyon; MTA

* Gazi University, Faculty of Dentistry, Department of Pediatric Dentistry.

Kaynakça Bilgisi: Dal A, Çınar Ç. İnvajine kanala MTA ile endodontik tedavi ve vital pulpalı tip 3 dens invaginatus: 2 yıl takipli olgu raporu. Atatürk Üniv Diş Hek Fak Derg 2021; 31: 104-8.

Citation Information: Dal A, Çınar C. Endodontic treatment of invaginated canal with MTA and a vital pulp with type 3 dens invaginatus : 2-year follow up case report. J Dent Fac Atatürk Uni 2021; 31: 104-8.

INTRODUCTION

Dens invaginatus is a rather common dental deformity, which is caused by an infolding enamel organ into the dental papilla at changing depths,

previous to the tooth calcification.¹ Incomplete lateral fusion of two germs has been depicted as one of the additional theories to clarify the morphogenesis of invaginated teeth.² Maxillary permanent lateral incisors are the most commonly involved teeth.³



Oehlers⁴ described 3 types of dens invaginatus: type 1, an enamel invagination in the crown only; type 2, an enamel-lined form that invades the root as a blind sac and may communicate with the pulp; and type 3, a severe form extending beyond the cemento-enamel junction and exhibiting a second foramen into the lateral periodontal ligament or periradicular tissue. This anomaly may involve the periradicular tissue and cause pulpal necrosis and periradicular lesions.

Various techniques for the treatment of teeth with type 3 dens invaginatus, including nonsurgical root canal therapy, endodontic surgery, and extraction. If there is no connection between invagination and pulp cavitation, non-surgical root canal treatment can only be performed with invaginated canal. Thus, the vitalities of the main canal are preserved. In many cases, the invaginated canal was necrotic whereas, the pulp in the main canal remained healthy.⁵⁻⁷

Bioceramics are highly compatible materials for non-surgical root canal treatments.⁸ They are composed of calcium-silicate-phosphate based, biocompatible nanoparticles.⁹ They are chemically stable, they are not toxic and carcinogenic.⁸ MTA is the gold standard of first generation bioceramics. It has been shown that MTA induces tissue regeneration as well as its properties such as biocompatibility, hiding and sealing.¹⁰ Meidyawati and Suprastiwi¹¹ in their study, compared MTA sealer and resin epoxy sealer in terms of their sealing ability and they did not find a statistically significant difference.

Like other bioceramics, MTA shows strong antibacterial effect against *E. faecalis* and *C. albicans*.¹² Rusdiana *et al*.¹³ reported that the sealing of MTA was better 7 days after mixing compared to Bioceramics. Also, the tightness of the MTA had a continuous antibacterial effect for up to 7 days.

In the present case, endodontic treatment of a mature maxillary lateral incisor described dens invaginatus type 3 with lesion on mesial aspect of the root and normal clinical crown. The only invaginated canal treatment was performed to achieve resolution of a substantial periodontal lesion.

CASE REPORT

An 11-year old female patient with no problems in her medical history was referred for treatment. She had suffered slight swelling and reported periodic pus drainage from buccal gingiva of the maxillary left

lateral incisor as her main complaint. Clinical examination showed no facial asymmetry and no swelling. Cervical and submandibular lymph nodes were normal on palpation. The occlusion was normal with no missing teeth. Tooth had no pain on percussion or palpation, no color change, no caries and no mobility (Figure 1). Probing depths around the tooth were less than 3 mm. Tooth had response to cold and electric pulp vitality tests. Periapical radiographic examination (Figure 2) and Computed Tomography (CT) (Figure 3) of the tooth showed evidence of a mature apex and Oehlers type 3 dens invaginatus. In addition, both clinical and radiographic evaluation showed that there was an anomaly of cingulum hypertrophy (Talon Tubercle) in other incisors.

Cross-sectional images with a clearer and detailed 0.4 mm voxel size on CT facilitated the diagnosis and treatment stages by seeing the borders and localization of the lesion. Radiolucency was only concerned with the dens invaginatus apex at the mesial aspect of the coronal third of the root. In addition, CT provided us to see that the main pulp is not associated with the invaginate pulpal tissue.

At the first appointment, after obtaining informed consent form from the parent of the patient, under local anesthesia through infiltration of 4% Articain with 1:200000 epinephrine and rubber dam isolation, access cavity of invaginated canal was prepared from the palatal side of the maxillary left lateral incisor. The length of invaginated root canal was radiographically determined with hand files (Figure 4). There was no connection between the main root canal and invaginated canal. The invaginated canal had to be prepared # 30 H file (VDW, GmbH, München, Germany) and irrigated with 2.5% sodium hypochlorite (NaOCl). The canal was dried using sterile absorbent paper points. Then a creamy paste of calcium hydroxide (Imical, Imicryl, Turkey) was placed as intracanal medication and the tooth was restored temporarily with filling material (Coltosol F, Coltene, Whaledent, OH).

Because of continuous drainage through the canal, calcium hydroxide was replaced after 1 week with irrigated NaOCl. The drainage was under control after 3 weeks. Pulp sensitivity tests were performed regularly at all the appointments. There was no sinus tract opening on the buccal gingiva of the tooth, Calcium hydroxide in the canal was irrigated with 2.5% NaOCl and saline. Canal was dried relatively

using paper points. Invaginated canal was obturated using MTA (BioMTA, Cerkamed, Stalowa Wola, Poland) as an apical barrier and also back filling (Figure 5). Cavity was restored with light-cured resin composite.

After 2 years, follow-up radiograph revealed the absence of radiolucency, the patient was remained asymptomatic and pulp vitality was continued (Figure 6).

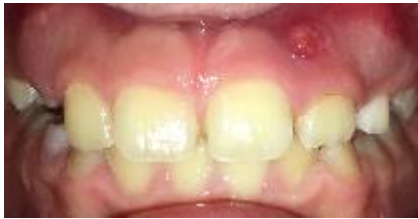

Figure 1. Labial view of the maxillary left lateral incisor.

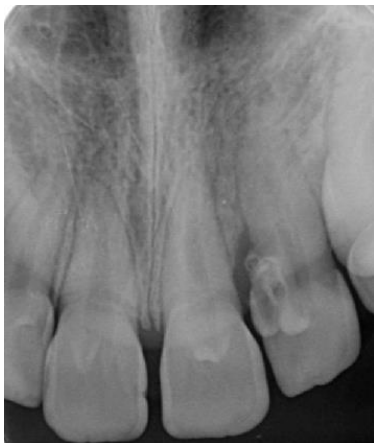

Figure 2. Periapical radiograph of maxillary lateral incisor demonstrating dens invaginatus with periradicular radiolucency.

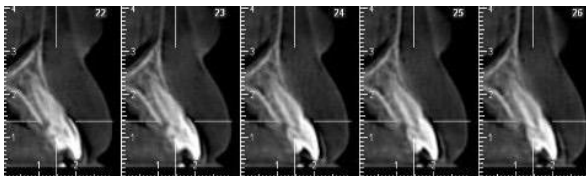


Figure 3. Computed tomography images shows revealing dens invaginatus.

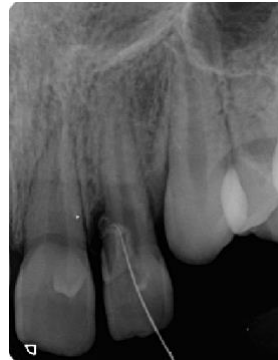

Figure 4. The length determination radiography of invaginated root canal.

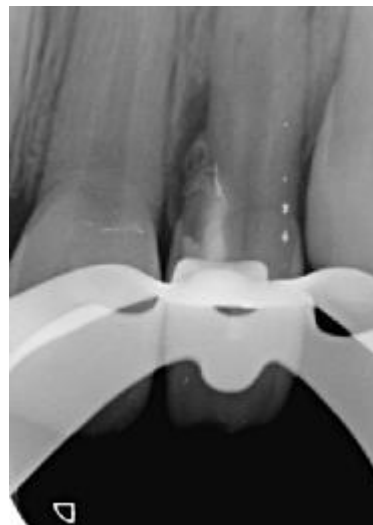

Figure 5. Periapical radiograph of maxillary left lateral incisor demonstrating MTA root canal filling of invaginated canal.

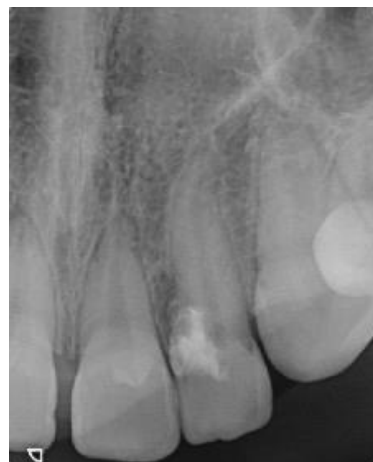

Figure 6. The 2-year follow-up periapical radiograph of maxillary left lateral incisor.

DISCUSSION

This article discusses a case in which type 3 dens invaginatus without communication with the pulp of normal clinical crown in a mature maxillary left lateral incisor were treated and obdured.

The clinical appearance of dens invaginatus varies considerably. The crown of affected teeth can have either normal morphology¹⁴ or abnormal forms.⁷ In the present case, the crown had normal morphology.

Very few cases of dens invaginatus have been reported in the same family members.¹⁵ Şıracı *et al*¹⁶ reported in their case report, talon tubercle and dens invaginatus anomalies affected both father and son together. These anomalies were found to exist on the same tooth of the father and son.¹⁶ In the present case, dens invaginatus findings were not found in the other family members of our patient.

The treatment protocol differs based on the anatomy of the invaginated tooth and the invaginated canal. Nonsurgical root canal treatment should be attempted as the first step. Nevertheless, the existence of communication between the invagination and the main canal has a key role for prognosis.⁷ Kunert *et al*¹⁷ explained that essential main canal was treated with pulpotomy, whereas invaginated canal was treated with conventional endodontic treatment, as a result of an existing communication between these two canals. In some cases, the invaginated canal is necrotic, while the main canal may remain unaffected. In addition, a number of cases also reported a dens invaginatus type 3 case in which only the invagination was treated and resulted in resolution of periapical lesion.^{5-7,18} In this case, we performed root canal treatment only for the invagination because only pulp necrosis was found in the invaginated canal without communication with the main canal. Calcium hydroxide, which has antimicrobial properties, is recommended as a root canal dressing material.¹ In this case, we used calcium hydroxide to achieve disinfection of invaginated canal.

MTA has been successfully used for the treatment of dens invaginatus.¹⁸ Soares *et al*¹⁸ also stated that MTA prevents oral contamination in treatment of dens invaginatus type 3. Due to these properties of the MTA, we performed complete MTA obturation of invaginated canal. The 2-year follow-up radiograph demonstrated normal periradicular bone structure. The main root canal vitality was maintained only after invaginated canal treatment.

The absence of knowledge regarding the possible root canal anatomical configurations may have detrimental outcomes for dentists, which can result in a failing endodontic treatment. Therefore, this case report demonstrated the significance of an accurate diagnosis for successful endodontic treatment.

CONCLUSION

As an alternative nonsurgical treatment option main pulp was kept vital and 2 years follow up showed periapical repair and absence of clinical symptoms. Success was achieved in the treatment of the lesioned invaginated canal by eliminating symptoms in the short term. The reason for this case to be successful is that the diagnosis is made correctly, the main pulp is not related to the invaginated pulpal tissue, effective biomechanical shaping at the correct working dimensions, and thus eliminating invaginated canal infection.

Sufficient clinical trials are needed to demonstrate the healing of lesions caused by dens invaginatus anomaly after non-surgical endodontic treatments and to understand the effects of substances and methods used in periapical healing.

Declaration of conflict of interest

The authors received no financial support for the research and /or authorship of this article. There is no conflict of interest.

REFERENCES

1. De Sousa SM, Bramante CM. Dens invaginatus: treatment choices. *Endod Dent Traumatol* 1998;14:152-8.
2. Ortiz P, Weisleder R, Villareal de Justus Y. Combined therapy in the treatment of dens invaginatus: case report. *J Endod* 2004;30:672-4.
3. Altuntaş A, Çınar Ç, Akal N. Endodontic treatment of immature maxillary lateral incisor with two canals: type 3 dens invaginatus. *Oral Surg Oral Med Oral Pathol Oral Radiol and Endod* 2010;110:e90-e93.
4. Oehlers FAC. Dens invaginatus (dilated composite odontome): I. Variations of the invagination process and associated anterior crown forms. *Oral Surg Oral Med Oral Pathol* 1957;10:1204-18.
5. Szajkis S, Kaufman AY. Root invagination treatment: a conservative approach in endodontics. *J Endod* 1993;19:576-8.



6. Schwartz SA, Schindler WG. Management of a maxillary canine with dens invaginatus and a vital pulp. *J Endod* 1996;22:493-6.
7. Tsurumachi T. Endodontic treatment of an invaginated maxillary lateral incisor with a periradicular lesion and a healthy pulp. *Int Endod J* 2004;37:717-23.
8. Mukhtar-Fayyad D. Cytocompatibility of new bioceramic-based materials on human fibroblast cells (MRC-5). *Oral Surg Oral Med Oral Pathol Oral Radiol Endod* 2011;112:e137-142.
9. De-Deus G, Canabarro A, Alves G, Linhares A, Senne MI, Granjeiro JM. Optimal cytocompatibility of a bioceramic nanoparticulate cement in primary human mesenchymal cells. *J Endod* 2009;35:1387-90.
10. Parirokh M, Torabinejad M. Mineral trioxide aggregate: a comprehensive literature review--Part III: Clinical applications, drawbacks, and mechanism of action. *J Endod* 2010;36:400-413.
11. Meidyawati R and Suprastiwi E. Sealing ability of MTA sealer and resin epoxy. *J Int Dent Med Res* 2017;10:134-137.
12. Dohaihem A, Al-Nasser A, Al-Badah A, Al-Nazhan S, Al-Maflehi N. An in vitro evaluation of antifungal activity of bioaggregate. *Oral Surg Oral Med Oral Pathol Oral Radiol Endod* 2011;112:e27-30
13. Rusdiana, Usman M, Meidyawati R, Suprastiwi E, Ayu NPAD. Antibacterial effects of Bioceramic and mineral trioxide aggregate sealers against *Enterococcus faecalis* clinical isolates. *J Int Dent Med Res* 2017;10:981-986.
14. Tarjan I, Rozsa N. Endodontic treatment of immature tooth with dens invaginatus: a case report. *Int J Paediatr Dent* 1999;9:53-56.
15. Hosey MT, Bedi R. Multiple dens invaginatus in two brothers. *Endod Dent Traumatol* 1996;12:44-7.
16. Şıracı E, Tekçiçek M, Turgut MD. Talon Tüberkülü ve dens invajinatus: ailesel geçişli bir olgu sunumu. *Atatürk Üniv. Diş Hek Fak Derg* 2005;15:81-7.
17. Kunert GG, Kunert IR, de Figueiredo JA, Barletta FB, Estrela C . Nonconventional therapeutic protocol for type iii dens invaginatus. *J Contemp Dent Pract* 2017;18:257-260.
18. Soares TRC, Silva LPD, Andrade Risso P, Maia LC, Primo LG. Management of a permanent maxillary lateral incisor with vital pulp and necrotic dens invaginatus type III. *J Dent Child (Chic)* 2017; 84:149-151.

Sorumlu Yazarın Yazışma Adresi

Aycan DAL
 Gazi Üniversitesi
 Fakülte: Diş Hekimliği Fakültesi
 Bölüm / Anabilim Dalı: Çocuk Diş Hekimliği
 Tlf: +90 312 203 4094
 Fax: +90 312 2239226
 E-mail: aycandal@outlook.com

