



## NASAL FLOOR AUGMENTATION AND SIMULTANEOUS DENTAL IMPLANT PLACEMENT: A CASE REPORT<sup>‡</sup>

### BURUN TABANI OGMENTASYONU İLE EŞ ZAMANLI DENTAL İMPLANT UYGULANMASI: BİR OLGU SUNUMU<sup>‡</sup>

Yrd. Doç. Dr. Sercan KÜÇÜKKURT\* Dr.Dt. Murat ÖZLE\*\*  
Prof. Dr. Sedat ÇETİNER\*\*

**Makale Kodu/Article code:** 2279  
**Makale Gönderilme tarihi:** 28.05.2015  
**Kabul Tarihi:** 29.06.2015

#### ABSTRACT

The rehabilitation of the severely atrophic edentulous maxilla is a challenging issue for dental practitioners. Nasal floor augmentation (NFA) is a method for augmentation of anterior maxilla. We represent a case of dental implant placement in conjunction with nasal floor augmentation procedure.

In this case report, a 63-year-old male patient with atrophic maxilla was treated with NFA procedure and simultaneously placed 4 dental implants. Implant supported removable prosthesis were applied 5 months after the implant placement. The healing period was uneventful. There were no signs of any complications at the 1 year follow up.

Maxillary sinus augmentation is a method used to achieve sufficient bone height for posterior maxillary implant placement and has proved highly successful. Nasal floor elevation is a very similar procedure and might be a preferred treatment modality for placing dental implants to the anterior maxilla that is limited by nasal floor elevation and bone grafting of nasal floor with simultaneously implant placement can be served as a feasible option for treatment of edentulous atrophic premaxilla with dental implants. In this case report, the patient was satisfied with the functional and esthetic results of his treatment.

**Keywords:** Nasal floor augmentation, simultaneous, Dental implant, Nasal floor lifting

#### ÖZ

Atrofik dişsiz maksillanın protetik olarak tedavi edilebilmesi diş hekimleri açısından her dönem zor bir uygulama olmuştur. Burun tabanı ogmentasyonu (BTO) maksiller ön bölgede dental implant uygulanması amacıyla uygulanan bir tedavi metodudur. Bu olgu sunumunda burun tabanı ogmentasyonu ile eş zamanlı dental implant uygulanması rapor edilmiştir.

63 yaşındaki erkek hasta kliniğimize, atrofik üst çene nedeniyle hareketli protezini kullanmakta zorluk çektiği şikayetiyle başvurmuştur. Yapılan klinik ve radyolojik muayeneler sonucu maksilla ön bölgeye BTO ile eş zamanlı olarak 4 adet dental implant yerleştirilmiş ve 5 ay iyileşme dönemi ardından implant destekli hareketli protez uygulaması yapılmıştır.

Maksiller sinus tabanı ogmentasyonu, posterior maksillada yıllardır güvenle uygulanan bir tedavi metodudur. Sinüs yükseltme işlemine oldukça benzerlik gösteren BTO, atrofik maksilla ön bölgeye eş zamanlı dental implant uygulanabilmesi amacıyla tercih edilebilecek bir yöntem olarak ön plana çıkmaktadır. Bu olgu sunumunda hasta yapılan BTO sonrasında yapılan protezin fonksiyon ve estetiğinden oldukça memnun olmuştur.

**Anahtar Kelimeler:** Burun tabanı ogmentasyonu, Eş zamanlı, Dental implant

\*İstanbul Aydın Üniversitesi Diş Hekimliği Fakültesi, Ağız, Diş ve Çene Cerrahisi AD

\*\*Gazi Üniversitesi Diş Hekimliği Fakültesi, Ağız, Diş ve Çene Cerrahisi AD

<sup>‡</sup> **Türk Oral ve Maksillofasial Derneğinin (TAOMS) Mayıs 2015'te düzenlemiş olduğu 22. Uluslararası kongresinde PP-193 kodu ile Poster olarak tebliğ edilmiştir.**



## INTRODUCTION

In recent years, the use of dental implants for replacement of missing teeth has achieved a high level of reliability and considerable rate of success. However, insertion of an endosseous implant requires sufficient bone volume for complete bone coverage around the implant<sup>1-3</sup>. Atrophic edentulous anterior maxilla rehabilitation has always been a challenge for the clinician because of the poor quality and quantity of residual bone, high aesthetic and functional demands<sup>4</sup>.

Vertical height for dental implant placement in the anterior maxilla is limited by nasal floor. Bone augmentation or short dental implants are the options for dental rehabilitation of atrophic maxilla. Bone augmentation options include such as onlay grafting, maxillary interpositional bone grafting via Lefort I osteotomy and nasal floor augmentation<sup>4, 5</sup>.

Nasal floor augmentation is an alternative method for the augmentation of edentulous, atrophic anterior maxilla (Fig. 1). NFA was first introduced by Adell et al<sup>1</sup> and Jensen et al<sup>6</sup> to reconstruct severely resorbed anterior maxilla using nasal floor elevation with autogenous bone graft. Over the past few decades many authors published their clinical studies about NFA. One of the largest case series for nasal floor elevation and dental implant placement is published by Lorean et al<sup>4</sup> in 2014. They have reported a case series of 67 patients treated with dental implants using nasal floor elevation and simultaneous placement of a total 213 dental implants.

In our case we represent a nasal floor augmentation procedure and simultaneous dental implant placement.

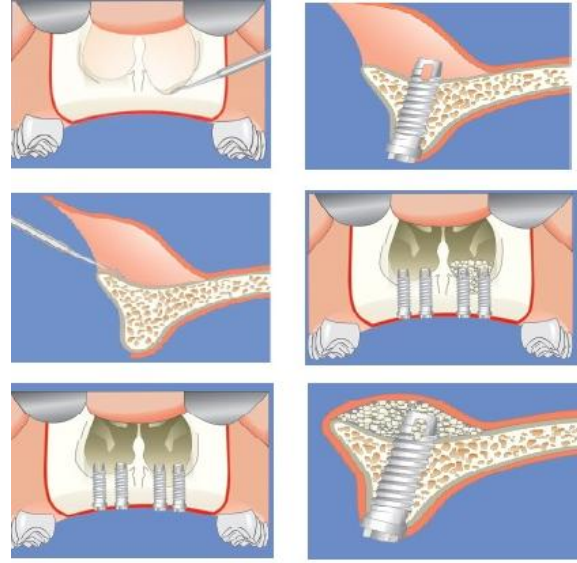


Figure 1. Procedures of the nasal floor augmentation and dental implant placement<sup>7</sup>

## CASE REPORT

A 63 years old, male patient with edentulous and severely atrophic maxilla admitted to Gazi University Oral and Maxillofacial Surgery Department with the complaint of poor retention of his removable prosthesis in the upper jaw. Intraoral examination revealed a severely atrophic, edentulous maxilla which was unable to be treated with a conventional removable prosthesis. Preoperative radiographs and dental casts were obtained for an implant-supported prosthesis. The panoramic radiograph (Fig. 2) and computed tomography (CT) (Fig. 3) revealed insufficient bone height for implant placement at premaxillary region and thin posterior maxillary bone. Thus, nasal floor elevation combined with grafting procedure for an implant-supported prosthesis was planned.

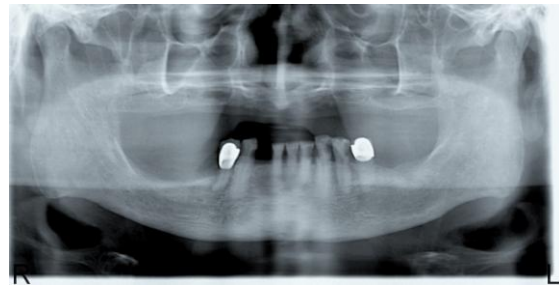

Figure 2. Pre-op panoramic radiograph

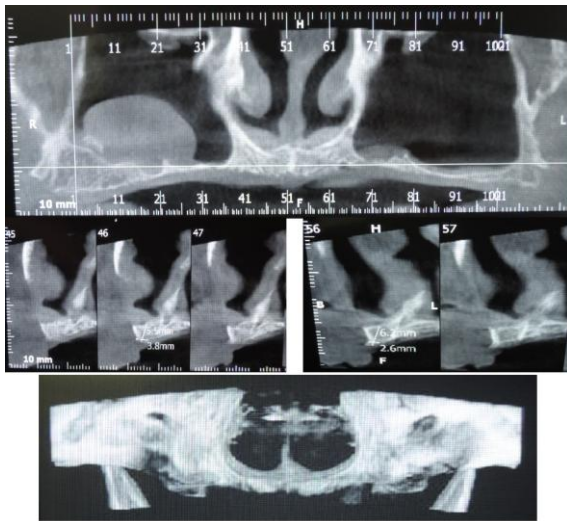


Figure 3. CT images of patient's maxilla

### Surgical Procedure

For providing anesthesia and avoid excessive bleeding, bilateral infraorbital and infiltration anesthesia was performed to the lip mucosa and palatal region by using articain hydrochloride with epinephrine 0.006 mg (Ultracaine D-S, Sanofi-Aventis Deutschland GmbH). A linear incision was made on alveolar ridge of the anterior maxillary region until the distal surfaces of canine area. Vertical releasing incisions were also made and the mucoperiosteal flap reflected (Fig.4). For elevating the nasal mucosa, maxillary sinus elevation currettes were used. Four SLA (sand blasted acid etched) surfaced, screw shaped, tissue level titanium implants (Straumann, Peter Merian-Weg 12 CH-4002 Basel Switzerland) were placed, 4.1 mm weight - 10 mm height, at the areas of the maxillary lateral incisors and canine area. The remaining bone height was around 5.5 - 6 mm in the incisors area and it was sufficient for the primary stabilization of the implants. Autogenous bone was harvested from the same surgical site by using chisels, mixed with xenograft (Botiss, botiss dental GmbH Hauptstr. 28 | 15806 Zossen – Germany) with ratio 1:2 and inserted in the space between implants and nasal mucosa. Implant placement before grafting allows comfortable entrance to the nose and space maintenance during bone graft insertion. The flap was closed with a 4/0 silk suture. The patient went on a soft, non-chewing diet and the provisional prosthesis was conditioned with a soft liner (Fig. 4).

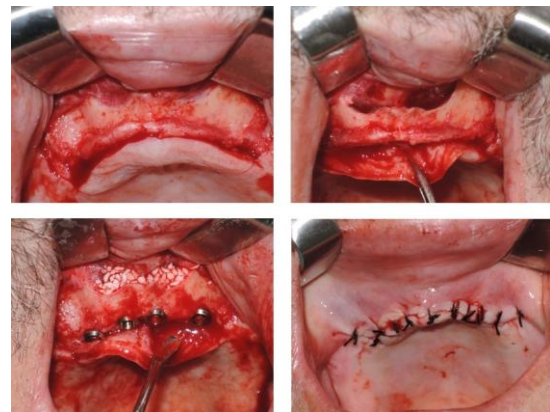


Figure 4. Surgical Procedure

Antibiotics (amoxicillin 1000 mg) were prescribed for 5 days, twice a day. Analgesics (Flurbiprofen, 2 times daily for 3 days) and decongestants (oxymetazoline) were also recommended. Decongestants provided ostial drainage and symptomatic relief. The patient was instructed to use a chlorhexidinedigluconate mouth-rinse twice a day. Against negative pressure that could damage the nasal mucosa, we suggested to patient to avoid from blowing his nose or sucking liquids through a straw. A Post-op control panoramic radiography was also taken (Fig. 5). There were no signs of bone resorption on the 1 year follow-up (Fig. 6-7).

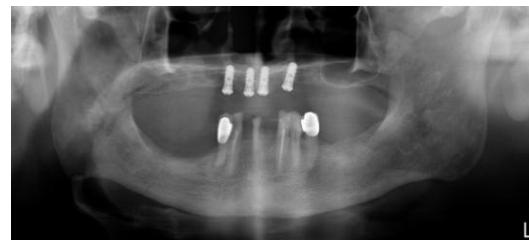

Figure 5. Post-op panoramic radiograph

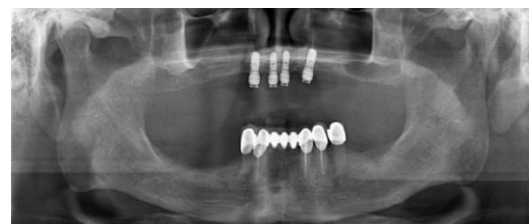

Figure 6. 1 year follow-up radiograph with locator abutments

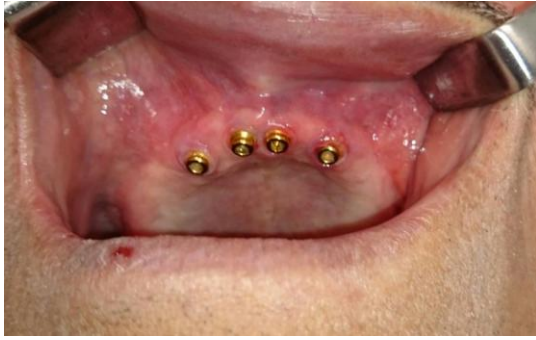

Figure 7. Intraoral image of 1 year follow up

## DISCUSSION

With the growing elderly population, increase in life expectancy and demand for a better quality of life, office-based oral surgery procedures that are associated with minimal morbidity become a necessity. The increased cost of health care is an added incentive to find cost-effective, predictable treatment modalities<sup>8</sup>. The rehabilitation of the severely atrophic edentulous maxilla is a challenging issue for dental practitioners because of poor quality and quantity of the residual bone, high aesthetic and functional demands<sup>4</sup>.

Maxillary sinus augmentation is a method used to achieve sufficient bone height for posterior maxillary implant placement and has proved highly successful. Nasal floor elevation is a very similar procedure and might be a preferred treatment modality for placing dental implants to the anterior maxilla that is limited by nasal floor<sup>9, 10</sup>.

Indications for nasal floor augmentations include unilateral or bilateral edentulism, where bone quantity/quality is inadequate for placement of a sufficient number and length of endosseous implants<sup>1</sup>. Simultaneous implant placement can be done with the grafting procedure or post pone for 3 to 6 months until graft consolidation period complete. The advantage of the immediate implant placement is avoiding an additional surgery. On the other hand it needs adequate amount of crestal bone (3–4 mm) for primary implant stabilization<sup>6</sup>. Since we have adequate vertical bone height in our case, implants were placed simultaneously.

Autogenous bone grafting with Le Fort I is an alternative method to reconstruct atrophic maxilla, but it is an extensive operation which needs donor-site

surgery, added cost of hospitalization and increased risks of complication. Another alternative procedure for treatment of the atrophic maxilla is onlay bone grafting<sup>11, 12</sup>. Soft tissue closure poses a limitation for reconstruction of the severely atrophic maxilla. In a review article, partial loss of the graft because of wound dehiscence/infection occurred in 3.3% of the cases, whereas total loss of the graft occurred in 1.4% of the cases<sup>13</sup>, the majority being related to extensive reconstructions of the atrophic maxilla with iliac grafts<sup>14</sup>. The overall survival rate of implants placed in conjunction with onlay bone graft was 79.5% (range, 60%-100%)<sup>14</sup>. Maxillary bone reconstruction using nasal lift procedure and dental implants is a minimal invasive treatment option in comparison with the Lefort I surgery or the onlay grafting operations.

In our case the patient was affected by severe atrophy of the edentulous maxilla. It could be categorized in class VI according to the Cawood and Howell's classification<sup>15</sup>. Treatment of patient was planned with ball attachment overdentures.

There was approximately 5.5 mm vertical bone height in anterior maxilla which could be suitable for using extra short dental implants such as 4mm implants (Straumann, Peter Merian-Weg 12 CH-4002 Basel Switzerland) or 5mm implants of Bicon dental implant systems (501 Arborway Boston, MA 02130), but there isn't enough literature support for using extra short implants with over denture prosthesis.

## CONCLUSION

Elevation and bone grafting of nasal floor with simultaneously implant placement can be served as a feasible option for treatment of edentulous atrophic premaxilla with dental implants. In this case report, the patient was satisfied with the functional and esthetic results of his treatment.

## REFERENCES

1. Adell R, Lekholm U, Grondahl K, Branemark PI, Lindstrom J, Jacobsson M. Reconstruction of severely resorbed edentulous maxillae using osseointegrated fixtures in immediate autogenous bone grafts. The International journal of oral & maxillofacial implants. 1990;5:233-46.

2. Jaffin RA, Berman CL. The excessive loss of Branemark fixtures in type IV bone: a 5-year analysis. J Periodontol 1991;62:2-4.
3. Çakır M, Karaca İR. Implant uygulamaları için kret koruma teknikleri. Atatürk Üniv Diş Hek Fak Derg 2015; 25-1:107-18.
4. Lorean A, Mazor Z, Barbu H, Mijiritsky E, Levin L. Nasal floor elevation combined with dental implant placement: a long-term report of up to 86 months. Int J Oral & Maxillofac Implants 2014;29:705-8.
5. Jensen J, Sindet-Pedersen S, Oliver AJ. Varying treatment strategies for reconstruction of maxillary atrophy with implants: results in 98 patients. J Oral And Maxillofac Surg: Official J Am Assoc Oral and Maxillofac Surg 1994;52:210-6; discussion 6-8.
6. Jensen J, Simonsen EK, Sindet-Pedersen S. Reconstruction of the severely resorbed maxilla with bone grafting and osseointegrated implants: a preliminary report. J Oral And Maxillofac Surg: official journal of the American Association of Oral and Maxillofac Surg 1990;48:27-32; discussion 3.
7. Rubo de Rezende ML, de Melo LG, Hamata MM, Monteiro-Amado F. Particulate inlay nasal graft with immediate dental implant placement in a patient with repaired alveolar cleft: case report. Implant Dentistry 2008;17:332-8.
8. El-Ghareeb M, Pi-Anfruns J, Khosousi M, Aghaloo T, Moy P. Nasal floor augmentation for the reconstruction of the atrophic maxilla: a case series. J Oral And Maxillofac Surg: Official J Am Assoc Oral and Maxillofac Surg 2012;70:e235-41.
9. Chanavaz M. Maxillary sinus: anatomy, physiology, surgery, and bone grafting related to implantology-eleven years of surgical experience (1979-1990). J Oral Implant 1990;16:199-209.
10. van den Bergh JP, ten Bruggenkate CM, Disch FJ, Tuinzing DB. Anatomical aspects of sinus floor elevations. Clin Oral Implant Res 2000;11:256-65.
11. Donovan MG, Dickerson NC, Hanson LJ, Gustafson RB. Maxillary and mandibular reconstruction using calvarial bone grafts and Branemark implants: a preliminary report. J Oral And Maxillofac Surg: Official J Am Assoc Oral and Maxillofac Surg 1994;52:588-94.
12. Astrand P, Nord PG, Branemark PI. Titanium implants and onlay bone graft to the atrophic edentulous maxilla: a 3-year longitudinal study. Int J Oral Maxillofac Surg 1996;25:25-9.
13. Triplett RG, Schow SR. Autologous bone grafts and endosseous implants: complementary techniques. J Oral And Maxillofac Surg: Official J Am Assoc Oral and Maxillofac Surg 1996;54:486-94.
14. Chiapasco M, Casentini P, Zaniboni M. Bone augmentation procedures in implant dentistry. Inter J Oral & Maxillofac Implant. 2009;24 Suppl: 237-59.
15. Cawood JI, Howell RA. A classification of the edentulous jaws. Int J Oral Maxillofac Surg 1988;17:232-6.

#### **Yazışma Adresi**

Yrd. Doç. Dr. Sercan KÜÇÜKKURT,  
İstanbul Aydın Üniversitesi  
Diş Hekimliği Fakültesi  
Ağız, Diş ve Çene Cerrahisi ABD,  
İstanbul  
İSTANBUL – TÜRKİYE,  
Tlf: 0532 620 55 90,  
e-mail: skucukkurt@gmail.com

