

OSTEOID OSTEOMA AND MULTIPLE LYMPH NODES: A CASE REPORT[#]

OSTEOİD OSTEOMA AND MULTİPLE LENF NODÜLLERİ: BİR OLGU SUNUMU[#]

Doç. Dr. Binali ÇAKUR*
Doç. Dr. Fatma ÇAĞLAYAN*

Prof.Dr. Hayati Murat AKGÜL*
Arş. Gör. Dt. İsmail GÜMÜŞSOY*

Makale Kodu/Article code: 1171
Makale Gönderilme tarihi: 06.05.2013
Kabul Tarihi: 22.08.2013

ABSTRACT

A case of osteoid osteoma in the mandible of a 19-year-old female around the right preauricular area was presented. Panoramic radiograph showed a mixed appearance, well-circumscribed mass near the right mandibular condylar neck and also showed radiopaque masses on the lateral side of the mandible near apexes of the mandibular molar teeth. For obtaining more definitively location and definition of these lesions, detailed radiological examination was performed by using cone beam computed tomography (CBCT). CBCT provides three-dimensional images and has proved to be a useful diagnosis of osteoid osteoma and multiple lymph nodes.

Keywords: Calcification, dental volumetric tomography, osteoid osteoma , panoramic radiograph

ÖZET

19 yaşında ki kadın hastanın sağ kulak ön bölgesi civarında alt çenesinde oluşan bir osteoid osteoma vakası sunuldu. Panoramik radyografide sağ mandibular kondil boynu civarında iyi sınırlı ve miks görünümlü kitle ve mandibular molar dişlerin kökleri civarında mandibular kemiğin dış yüzeyinde radyopak kitle görüldü. Bu lezyonların daha ayrıntılı tanımı ve konumu için detaylı radyolojik inceleme konik ışınli bilgisayarlı tomografi (KİBT) kullanılarak yapıldı. KİBT üç boyutlu görüntüleri ile osteid osteoma ve multiple lenf nodüllerinin teşhisinde faydalı bilgiler sağlar.

Anahtar kelimeler: Kalsifikasyon, dental volümetrik tomografi , osteid osteoma, panoramik radyografi

INTRODUCTION

Several different calcifications such as an elongated styloid process, a large maxillary tuberosity, calcification of arteries, calcified lymph nodes, calculi within the salivary glands, phleboliths, a prominent hamulus of the pterygoid, foreign bodies, an odontome, sclerosing osteitis, Garre's osteomyelitis, fibrous dysplasia, idiopathic osteosclerosis, osteoma and abnormalities of the mandibular rami can be found in the head and neck region.¹ Osteoid osteoma is a benign skeletal neoplasm. Osteomas are characterised by the proliferation of compact and/or cancellous bone. Osteoid osteoma can occur in any bone but the lingual surface and lower border of the body are the most common locations of these lesions

with a male to female ratio of 2 to 1 and rarely occurs in the jaw.²⁻⁴ Imaging plays a major role in detecting of these lesions. The presence of these calcifications can be showed either non-invasive techniques or invasive techniques¹⁻³ However, in dentistry, these calcifications can be detected on the panoramic radiography and cone beam computed tomography (CBCT).¹ CBCT is relatively a new imaging modality and uses generally in dental implantology. In our study, it is aimed to present detailed the imaging of multiple lymph nodes and osteoid osteoma that were detected by CBCT.

* Atatürk Üniversitesi, Diş Hekimliği Fakültesi, Ağız, Diş ve Çene Radyolojisi Anabilim Dalı

[#]Bu çalışma oral Diş ve Çene Radyolojisi Derneği V. Bilimsel Sempozyumunda (33 pp., Erzurum, Türkiye, 2013) poster olarak sunulmuştur.



CASE REPORT

A 19-year-old female was admitted to our clinic due to spontaneous pain around the right preauricular area. Pain would worsen by function and at night, which frequently awoke the patient. Nonsteroidal anti-inflammatory drugs relieved the pain substantially. The patient had no history of trauma or infection in the right temporomandibular joint. The patient was healthy and had no history of systemic disease. There was no sign of temporomandibular joint disorder such as click or crepitation. On panoramic radiograph, a small, well-defined circular lucent lesion was evident on the subcondylar region (Figure 1). For obtaining more definitively location and definition of the lesion, detailed radiological examination was performed by using CBCT. We used flat panel detector-based CBCT in our department (NewTom FP, Quantitative Radiology, Verona, Italy). The CBCT scans with 0.5 mm axial slices, 1 mm coronal slices, 1 mm sagittal slices and three-dimensional (3D) images were obtained. The maximum intensity profile and 3D reconstructions revealed a well-defined round hypodense lesion in the right subcondylar portion of the infero-medial aspect of the mandible (Figures 2-4). When the results of multiplanar reformatting and 3D images view of CBCT scans, the patient's age, spontaneous pain at night and relieved with nonsteroidal anti-inflammatory drugs were considered together, the lesion was thought to be the osteoid osteoma.




Figure 1. On panoramic radiograph, a small, well-defined circular lucent lesion on the subcondylar region and radiopaque masses on the lateral side of the mandible near apices of the mandibular molar teeth (white arrows).

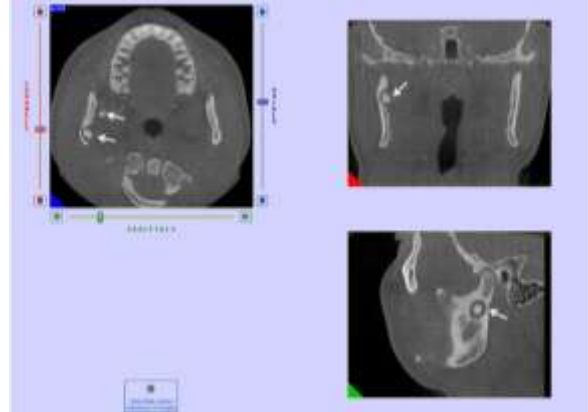


Figure 2. The maximum intensity profile revealed a well-defined round hypodense lesion in the right subcondylar portion of the infero-medial aspect of the mandible (white arrows).

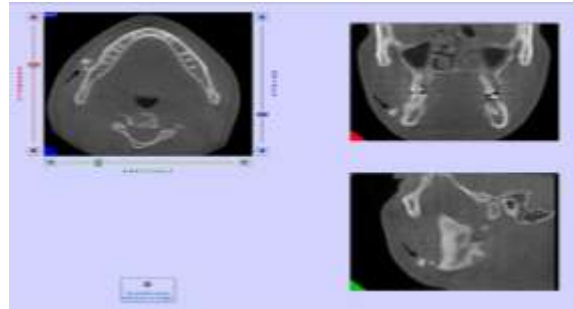


Figure 3. The maximum intensity profile revealed radiopaque masses on the lateral side of the mandible near apices of the mandibular molar teeth (black arrows).

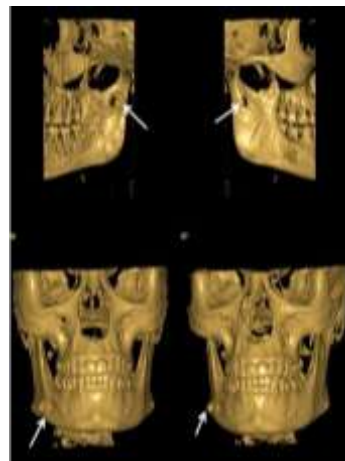


Figure 4. 3D reconstructions revealed a small, well-defined circular lucent lesion on the subcondylar region and radiopaque masses on the lateral side of the mandible near apices of the mandibular molar teeth (white arrows).

DISCUSSION

Several different calcifications can be projected to the head and neck region in panoramic radiography. Dental panoramic radiography is a useful imaging technique by which the dentist can evaluate the whole dentition as well as the jaw bones and is widely used for routine examinations.¹ Unfortunately, dental panoramic radiography is not as useful as Doppler ultrasonography and three dimensional computed tomography for detecting these lesions, because panoramic radiography is essentially a 2D representation of 3D anatomy.¹ Over the past decade, CBCT has been designed for imaging hard tissue of the maxillofacial region and uses commonly in dental implantology.¹ In this study, we used a CBCT for imaging of osteoid osteoma and multiple lymph nodes . CBCT can produce images with high diagnostic quality, high resolution (sub-millimeter resolution), short scanning time and radiation dose an order of magnitude lower than those of conventional CT scans.¹ CBCT provides accurate 3D localization of various soft tissue calcifications in the head and neck region making precision in interpretation more likely than with 2D images such as those provided by standard dental panoramic radiography.¹ CBCT provides 3D images and has proved to be a useful diagnosis of osteoid osteoma and multiple lymph nodes. CT is used for precise localization of the nidus and may be used for guiding percutaneous ablation.⁴ Magnetic resonance imaging is a useful imaging technique, but CT appears superior for precise localization. The roles of conventional and Doppler ultrasonography have not been established. Angiography may be useful in differentiating the tumor from a Brodie abscess. Single-photon emission computed tomography scanning is useful in the localization of the tumor when the spinal arch or spinous process is involved. CT has the disadvantage of ionizing radiation. On magnetic resonance imaging, tumors are not as conspicuous as they are on CT scans. Angiography is an invasive procedure, and a minor overlap of angiographic features occurs with a Brodie abscess. The specificity of radionuclide bone scanning is low.⁴⁻¹⁰

CBCT provides three-dimensional images and has proved to be a useful diagnosis of osteoid osteoma and multiple lymph nodes.

REFERENCES

1. Çakur B, Sümbüllü MA, Yılmaz AB. Dental volumetric tomography in the radiological detection of carotid artery calcification. *Anatol J Cardiol* 2011;11:652-4.
2. Ida M, Kurabayashi T, Takahashi Y, Takagi M, Sasaki T. Osteoid osteoma in the mandible. *Dentomaxillofac Radiol* 2002 ;31:385-7.
3. Karandikar S, Thakur G, Tijare M, Shreenivas K, Agrawal K. Osteoid osteoma of mandible. *BMJ Case Rep* 2011; doi: 10.1136/bcr.10.2011.4886.
4. Shukla S, Clarke AW, Saifuddin A. Imaging features of foot osteoid osteoma. *Skeletal Radiol* 2009;39:683-9.
5. Adam G, Neuerburg J, Vorwerk D, et al. Percutaneous Treatment of Osteoid Osteomas: Combination of Drill Biopsy and Subsequent Ethanol Injection. *Semin Musculoskelet Radiol* 1997;:281-4.
6. Donkol RH, Al-Nammi A, Moghazi K. Efficacy of percutaneous radiofrequency ablation of osteoid osteoma in children. *Pediatr Radiol* 2008;38:180-5.
7. Murphy K, Baez JC, Cooney B, Kabaish K. CT Fluoroscopy-guided Postmyelographic Transthecal Radiofrequency Ablation of a Posterior Vertebral Body Osteoid Osteoma. *J Vasc Interv Radiol* 2008;19:291-3.
8. Davies AM, Wellings RM. Imaging of bone tumors. *Curr Opin Radiol* 1992;4:32-8.
9. Ebrahim FS, Jacobson JA, Lin J, et al. Intraarticular osteoid osteoma: sonographic findings in three patients with radiographic, CT, and MR imaging correlation. *AJR Am J Roentgenol* 2001;177:1391-5.
10. Perkins AC, Hardy JG. Intra-operative nuclear medicine in surgical practice. *Nucl Med Commun* 1996;17:1006-15.

Yazışma Adresi

Binali ÇAKUR
Atatürk Üniversitesi, Diş Hekimliği Fakültesi
Ağız, Diş ve Çene Radyolojisi
25240, Erzurum, Türkiye.
Fax no: +90 442 236 09 45
Telephone : +90 442 231 17 65
E-mail: bcakur@atauni.edu.tr

