



## ROOT MORPHOLOGY AND C-SHAPED CANAL SYSTEM IN MANDIBULAR SECOND MOLARS ON CONE BEAM COMPUTED TOMOGRAPHY IMAGES

### DENTAL VOLUMETRİK TOMOGRAFİ GÖRÜNTÜLERİ ÜZERİNDE ALT İKİNCİ MOLARLARDAKİ C ŞEKLİ KANAL SİSTEMİ VE KÖK MORFOLOJİSİ

Yrd. Doç. Dr. Özkan MİLOĞLU\*  
Dt.İbrahim ERSOY\*\*\*

Dt. Eren YILDIRIM\*\*  
Dt. Ömer DEMİRTAŞ \*\*

Prof. Dr. Hayati Murat AKGÜL\*

**Makale Kodu/Article code:** 853  
**Makale Gönderilme tarihi:** 21.05.2012  
**Kabul Tarihi:** 08.10.2012

#### ABSTRACT

**Background:** The objective of this cone beam computed tomography study (CBCT) is to evaluate the frequency of C-shaped canals in mandibular second molars (MSMs) in a Turkish population with respect to gender, age and tooth position (unilateral (left versus right) and bilateral) in addition to root morphology.

**Material and Methods:** A total of 243 patients (112 females and 131 males) who presented to the Oral and Maxillofacial Radiology service at the Atatürk University Faculty of Dentistry and required radiographic examination by CBCT as part of their dental treatment were analyzed.

**Results:** The samples include 400 CBCT images of MSMs; 86 subjects had unilateral molars and 157 subjects had bilateral molars. Of 243 patients, 34 (14.0%) had C-shaped MSMs. This frequency did not differ with gender and age. C-shaped canal system were determined in 36 (9.0%) of the teeth. Thirty-two cases (94.1%) were unilateral and 2 (5.9%) were bilateral. Of the 32 unilateral cases, 15 (46.9%) were on the left and 17 (53.1%) were on the right side. Single roots were present in 47.3% (30.6% several canals and 16.7% one canal) of MSMs with C-shaped canal. In contrast, this rate was only 1.6% in MSMs without C-shaped canal.

**Conclusion:** C-shaped MSMs occurred relatively low frequency in this Turkish population. CBCT is an effective tool for the detection of C-shaped roots/canals, and it is a valuable aid for dentists providing root canal treatment.

**Key words:** Mandibular second molar · C-shaped canal · Cone beam computed tomography · Root morphology

#### ÖZET

**Amaç:** Bu dental volümetrik tomografi (DVT) çalışmasının amacı Türk popülasyonuna ait bir çalışma grubunda alt ikinci molarlardaki (AİM) C şekilli kanalların sıklığını kök morfolojisinin yanında cinsiyet, yaş ve diş pozisyonu (tek taraflı (sağ/sol) ve çift taraflı) açısından değerlendirmektir.

**Gereç ve Yöntem:** Atatürk Üniversitesi, Diş Hekimliği Fakültesi, Oral ve Maksillofasial Radyoloji Servisine müracaat eden ve dental tedavilerinin bir parçası olarak DVT radyografik incelemesine tabii tutulan 112 kadın ve 131 erkek toplam 243 hasta incelendi.

**Bulgular:** Örnekler 86 hastada tek taraflı, 157 hastada çift taraflı toplam 400 AİM'nin DVT imajını içerdi. 243 hastanın 34'ü (%14.0) C şekilli AİM'ye sahipti. Bu sıklık yaş ve cinsiyet ile farklılaşmadı. C şekilli kanal sistemi 36 dişte (%9.0) tespit edildi. 32 vaka (%94.1) tek taraflı ve 2 vaka (%5.9) çift taraflıydı. 32 tek taraflı vakanın, 15'i (%46.9) sol ve 17'si (%53.1) sağ taraftaydı. Tek kökler C şekilli AİM'nin %47.3'ünde (%30.6 birkaç kanal ve %16.7 tek kanal) mevcuttu. Aksine, bu oran C şekilli olmayan AİM'nin sadece %1.6'sıydı.

**Sonuç:** C şekilli AİM Türk popülasyonunda nispeten düşük sıklıkta ortaya çıktı. DVT C şekilli kök/kanalların belirlenmesinde etkili bir araçtır ve kök kanal tedavisinde diş hekimleri için değerli bir yardımcıdır.

**Anahtar Kelimeler:** Alt ikinci molar · C-şekilli kanal · Dental volumetrik tomografi · Kök morfolojisi

\* Atatürk Üniversitesi, Diş Hekimliği Fakültesi, Oral Diagnoz ve Radyoloji Bölümü, Erzurum, Türkiye

\*\* Atatürk Üniversitesi, Diş Hekimliği Fakültesi, Oral Diagnoz ve Radyoloji Bölümü, Erzurum, Türkiye

\*\*\* Atatürk Üniversitesi, Diş Hekimliği Fakültesi, Endodonti Bölümü, Erzurum, Türkiye

\*\*\*\* Atatürk Üniversitesi, Diş Hekimliği Fakültesi, Oral Diagnoz ve Radyoloji Bölümü, Erzurum, Türkiye



## INTRODUCTION

Knowledge of root canal anatomy and variations between ethnic groups is important for clinicians to facilitate effective root canal treatment.<sup>1</sup> The C-shaped canal is an anatomical variation as well the failure of the Hertwig's epithelial root sheath to fuse on the lingual or buccal root surface was the main cause of a C-shaped root and canal.<sup>2</sup> The term of 'C-shaped canal' is first used by Cooke and Cox<sup>3</sup> in 1979 nevertheless the main feature of this variation is the presence of form a letter 'C' shape at the root canal orifice.

Mandibular second molars (MSMs) are more often more variable in shape as well the C-shaped canal is most frequently found in MSMs. Radiography has an essential place in dentist and some radiographic methods used in analyzing root canal morphology as well the cone beam computed tomography (CBCT) is one of these methods.<sup>4</sup> Most of the investigations concerning the anatomic characteristics of C-shaped canals were conducted with extracted teeth and were invasive however as a noninvasive three-dimensional (3D) imaging technique,<sup>5</sup> CBCT was reported to be adequately precise for morphological analysis.<sup>6</sup> Compared with conventional medical computed tomography, CBCT studies have adequately lower effective dose and shorter working time.<sup>7</sup>

Dental anatomists and anthropologists identified morphological variations and commented on their relative frequencies in different ethnic groups separately.<sup>8</sup> There is a significant ethnic variation in the incidence of C-shaped molars, with a presence of loud prevalence in Asians.<sup>9,10</sup> Reported prevalence have included 2.7-8.0% for American,<sup>3, 11, 12</sup> 31.9% and 39.0% for Chinese,<sup>5,9</sup> 10.6% for Saudi Arabian,<sup>13</sup> 19.1% for Lebanese,<sup>14</sup> 32.7% and 44.5 for Korean,<sup>15,16</sup> 7.2% for Iranian,<sup>8</sup> and 8.1% for Caucasian Turkish populations.<sup>17</sup> The objective of this CBCT study is to evaluate the frequency of C-shaped canals in MSMs in a Turkish population with respect to gender, sex and tooth position (unilateral (left versus right) and bilateral) in addition to root morphology.

## MATERIAL AND METHODS

In this retrospective study, we examined the C-shaped canal configuration in MSMs using CBCT images (New Tom FP QR-DVT 9000, 110 kVp, 15 mA,

36 s scan time, 5.4 s typical X-ray emission time, 17 cm diameter–13 cm height scan volume, Verona, Italy). A total of 243 patients (112 females and 131 males) who presented to the Oral and Maxillofacial Radiology service at the Ataturk University Faculty of Dentistry and required radiographic examination by CBCT as part of their dental treatment were analyzed between February 2010 and April 2011. Axial, coronal and sagittal views were examined by three investigators (one professor and two postgraduate dentomaxillofacial radiologist) at the same time. The thickness of the image slices was 1 mm and the distance between slices was 1 mm. Views were performed with the patient's palatal plane parallel to the beam. The following observations were made (i) frequency and root morphology and (ii) frequency of C-shaped canals by gender, age and localization (left versus right). The investigators classified the root morphology on CBCT images as presented in figure 1.<sup>18</sup>

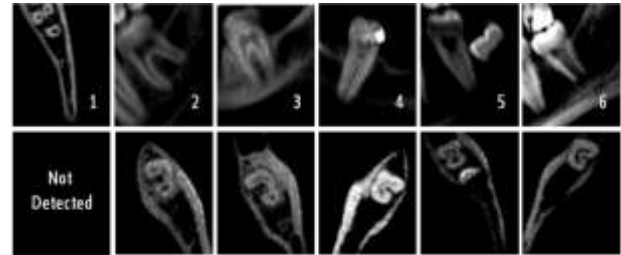


Figure 1. Root morphology

1. Three separate roots
2. Two separate roots are divergent or parallel from the furcation
3. Two separate roots are conical: trabecula patterns are apparent between roots
4. Two separate roots are conical: trabecula patterns rarely appear between roots
5. One root and several canals
6. One root and one canal

The relative frequencies of 6 groups of root morphologies were calculated and compared among MSMs with and without C-shaped canals. The variables were analyzed using the Statistical Package for Social Sciences (SPSS 11.5; Chicago, IL) program. The chi square test was used to determine potential differences in the range of lesions when stratified by gender and age. P value of <0.05 was considered as statistically significant.

## RESULTS

The samples include 400 CBCT images of MSMs; 86 subjects had unilateral molars and 157 subjects had bilateral molars. Of 243 patients, 34 (14.0%) had C-shaped MSMs. This frequency did not differ with gender and age. C-shaped canal system were determined in 36 (9.0%) of the teeth. Thirty-two cases (94.1%) were unilateral and 2 (5.9%) were bilateral. Of the 32 unilateral cases, 15 (46.9%) were on the left and 17 (53.1%) were on the right side. (Table I). Single roots (Group 5 and 6) were present in 47.3% (30.6% several canals and 16.7% one canal) of MSMs with C-shaped canal. In contrast, this rate was only 1.6% in MSMs without C-shaped canal. The most common root morphology was group 4 (2 separate conical roots and trabecular pattern are apparent between roots) among MSMs with C-shaped canals and group 2 (2 separate roots that were either divergent or parallel from furcation) among molars without C-shaped canals (Table II).

Table I. Details of detected C-shaped canals cases in present study

		n	C-shaped canals	Frequency (%)	X <sup>2</sup>	P value
<b>Gender</b>	female	112	14	12.5	0.42	0.50
	male	131	20	15.3		
<b>Age</b>	15-40	109	15	13.8	0.92	0.99
	40-65	134	19	14.2		
<b>Laterality</b>	unilateral		32	94.1		
	bilateral		2	5.9		
<b>Localization</b>	left		15	46.9		
	right		17	53.1		

Table II. The relationship between root morphology and C-shaped canal in second molars

	ROOT MORPHOLOGY						Total
	Group 1	Group 2	Group 3	Group 4	Group 5	Group 6	
<b>Molars with C-shaped canal, n (%)</b>	0 (0.0)	5 (13.9)	2 (5.5)	12 (33.3)	11 (30.6)	6 (16.7)	36 (100.0)
<b>Molars without C-shaped canal, n (%)</b>	4 (1.1)	185 (50.8)	37 (10.2)	132 (36.3)	6 (1.6)	0 (0.0)	364 (100.0)

## DISCUSSION

It is important to identified morphological variations and commented on their relative frequencies in different ethnic groups. This study evaluates the frequency and root morphology of C-shaped MSMs in 243 Turkish individuals using CBCT. The population is selected from a purely ethnic East Anatolian Turkish population, and the CBCT images were collected only from indigenous eastern Turkish individuals in this study. Moreover, the present study is the first study evaluating C-shaped canals with CBCT in East Anatolian Turkish population in the literature.

Most previous studies have been performed using ground up samples of extracted teeth. However, the extracted teeth could be pathologic teeth and could have varied root shapes compared with normal teeth because of calcification. Although the investigations conducted with extracted teeth were invasive, CBCT is a noninvasive three-dimensional (3D) imaging technique. Hence, in our study, presences of C-shaped canals were examined in normal teeth using CBCT.

The canal shape was significantly connected with race,<sup>2</sup> with a presence of loud prevalence of C-shaped canals in Asians.<sup>9,10</sup> The current study revealed that 9% of the MSMs had C-shaped canal configuration in Turkish population, which was less than the 44.5% reported by Jin et al.,<sup>16</sup> 39.0% reported by Zheng et al.,<sup>5</sup> 32.7% reported Seo and Park,<sup>10</sup> 31.5% reported by Yang et al.,<sup>9</sup> 29.0% reported by Jung et al.,<sup>18</sup> and 19.4% reported by Haddad et al.<sup>14</sup> Conversely, this is higher than the 8.1% reported by Cimilli et al.,<sup>17</sup> 8.0% reported by

Cooke and Cox,<sup>3</sup> 7.6% reported by Weine,<sup>11</sup> 7.2% reported by Rahimi et al.,<sup>8</sup> and 2.7% reported by Weine.<sup>12</sup> In appearance of the consequential differences among the results of studies on the prevalence of C-shaped canals in MSMs in different ethnic populations, following studies may reveal interesting data about the prevalence and canal configuration of C-shaped canals in MSMs in the different parts of the world.

Çalışkan et al.<sup>19</sup> did not find single rooted MSMs in 100 teeth in Turkish population. Whereas Cimilli et al.<sup>17</sup> conducted that single rooted MSMs were found 112 (22.8%) in 491 teeth. 40 (8.1% in 491 teeth and 35.7% in 112 single rooted teeth) of these teeth had C-shaped canals with spiral computed tomography in Caucasian Turkish population. However, single rooted MSMs were found to be 23 (5.7%) in 400 teeth and 17 (4.25% in 400 teeth and 73.9% in 23 single rooted teeth) of these teeth had C-shaped canal with CBCT in eastern Turkish population in our study. This situation can be explained by the differences in sample source, different definitions of C-shaped canals and the study methods between studies.

The anatomy of C-shaped canals and the pertinence of this to endodontic treatment are enormously important to evaluate.<sup>18</sup> Although Tamse and Kaffe<sup>20</sup> did not evaluate the relationship between the conical root and the presence of a C-shaped canal, they reported that 9% of 1049 MSMs had a conical form.

The current study of 36 MSMs with C-shaped canal, the group 4 in which 2 separate roots fused at the apex to form a conical shape was the most common. This findings were similar to reported by Jung et al.<sup>18</sup> (did not find the group 1 and 6 in 311 teeth?) estimated the C-shaped canal configuration from panoramic radiographs. (Furthermore, they did not find the group 1 and 6 in 311 teeth with panoramic radiographs?). However, group 1 and 6 were found to be 1.1% and 16.7% in 400 teeth in our study. It may be that the sample source and the study methods were responsible for the differences.

Because of the two-dimensional nature of conventional radiographs they do not consistently reveal the act number of canals present in teeth. The main advantages of CBCT images are that it is nondestructive and allows 3D reconstruction and

visualization of the external and internal anatomy of the teeth. Clinicians should be considered the potential value of CBCT when more information is needed for diagnosis or treatment planning beyond that obtained from conventional radiographs.<sup>21</sup>

## CONCLUSION

This is the first study evaluating C-shaped canals with CBCT in East Anatolian Turkish population. The great differences clear among studies and the prevalence of C-shaped canals may be traceless to racial differences and study methods. The C-shaped canal system tends to vary considerably in their anatomical configuration and thus leads to difficulties in debridement, filling and restoration. The CBCT could be suggested as the effective diagnostic modality for root and canal configuration.

## ACKNOWLEDGMENT

This study was submitted as poster presentation in the 5th biennial meeting of the European Federation of Conservative Dentistry (EFCD) held in association with the 6th international congress of the Society of Restorative Dentistry, Turkey (RDD), 13-15 October 2011, Istanbul, Turkey.

## REFERENCES

1. Vertucci FJ. Root canal anatomy of the human permanent tooth. *Oral Surg Oral Med Oral Pathol.* 1984;58:589-99.
2. Manning SA. Root canal anatomy of mandibular second molars. Part II. C-shaped canals. *Int Endod J.* 1990;23:40-5.
3. Cooke HG, Cox FL. C-shaped canal configuration in mandibular molars. *J Am Dent Assoc.* 1979;99:836-9.
4. Kaya S, Adiguzel O, Yavuz I, Tumen EC, Akkus Z. Cone beam dental computerize tomography for evaluating changes of aging in dimensions central superior incisor root canals. *Med Oral Patol Oral Cir Bucal.* 2011;16:463-6.
5. Zheng Q, Zhang L, Zhou X, Wang Q, Wang Y, Tang L, Song F, Huang D. C-shaped root canal system in mandibular second molars in a Chinese population evaluated by cone-beam computed tomography. *Int Endod J.* 2011;44:990-9.
6. Neelakantan P, Subbarao C, Subbarao CV. Comparative evaluation of modified canal staining



- and clearing technique, cone-beam computed tomography, peripheral quantitative computed tomography, spiral computed tomography, and plain and contrast medium-enhanced digital radiography in studying root canal morphology. J Endod. 2010;36:1547-51.
7. Patel S, Dawood A, Ford TP, Whaites E. The potential applications of cone beam computed tomography in the management of endodontic problems. Int Endod J. 2007;40:818-30.
  8. Rahimi S, Shahi S, Lotfi M, Zand V, Abdolrahimi M, Es'haghi R. Root canal configuration and the prevalence of C-shaped canals in mandibular second molars in an Iranian population. J Oral Sci. 2008;50:9-13.
  9. Yang ZP, Yang SF, Lin YC, Shay JC, Chi CY. C-shaped root canals in mandibular second molars in a Chinese population. Endod Dent Travmatol. 1988;4:160-3.
  10. Seo MS, Park DS. C-shaped root canals of mandibular second molars in a Korean population. Int Endod J. 2004;37:139-44.
  11. Weine FS. The C-shaped mandibular second molar: incidence and other consideration. J Endod. 1998;24:372-5.
  12. Weine FS, Pasiewicz RA, Rice RT. Canal configuration of the mandibular second molar using a clinically oriented in vitro method. J Endod. 1988;14:207-13.
  13. Al-Fouzan KS. C-shaped root canals in mandibular second molars in a Saudi Arabian population. Int Endod J. 2002;35:499-504.
  14. Haddad GY, Nehma WB, Ounsi HF. Diagnosis, classification, and frequency of C-shaped canals in mandibular second molars in the Lebanese population. J Endod. 1999;25:268-71.
  15. Pineda F, Kuttler Y. Mesiodistal and buccolingual roengenographic investigation of 7,275 root canals. Oral Surg Oral Med Oral Pathol. 1972;33:101-10.
  16. Jin GC, Lee SJ, Roh BD. Anatomical study of C-shaped canals in mandibular second molars by analysis of computed tomography. J Endod. 2006;32:10-3.
  17. Cimilli H, Cimilli T, Mumcu G, Kartal N, Wesselink P. Spiral computed tomographic demonstration of C-shaped canals in mandibular second molars. Dentomaxillofac Radiol. 2005;34:164-7.
  18. Jung HJ, Lee SS, Huh KH, Yi WJ, Heo MS, Choi SC. Predicting the configuration of a C- shaped canal system from panoramic radiographs. Oral Surg Oral Med Oral Pathol Oral Radiol Endod. 2010;109:37-41.
  19. Çalışkan MK, Pehlivan Y, Sepetçioğlu F, Türkün M, Tuncer SS. Root canal morphology of human permanent teeth in a Turkish population. J Endod. 1995;21:200-4.
  20. Tamse A, Kaffe I. Radiographic survey of the prevalence of conical lower second molar. Int Endod J. 1981;14:188-90.
  21. Miloglu O, Caglayan F, Ezmeci T, Dagistan S, Demirtas O. Multiple cases of submandibular sialolithiasis detected by cone beam computed tomography. Ataturk Univ. Dis Hek. Fak. Derg. 2010;20:189-193.

#### Yazışma Adresi:

Yrd. Doc. Dr. Ozkan MILOGLU  
Oral Diagnoz ve Radyoloji Bölümü,  
Atatürk Üniversitesi,  
Diş Hekimliği Fakültesi, Erzurum, Türkiye  
İş Telefon Numarası: +90 442 2311778  
Faks Numarası: +90 442 2360945  
E-mail adresi: omiloglu@hotmail.com

