

# Idiopathic coronal resorption in impacted permanent teeth and its relationship with age: radiologic study\*

## Purpose

The purpose of this study was to evaluate the relationship between idiopathic coronal resorption and age in adult patients.

## Materials and Methods

3405 digital panoramic radiographs present in the archive of the radiology department belonging to 1584 males and 1821 females aged 25 and over were assessed by two oral and maxillofacial radiologists. The patients' age, gender, number of impacted teeth, number and position of teeth with idiopathic coronal resorption and the extent of coronal resorption were recorded on standard forms.

## Results

A thousand and nine impacted teeth were observed in 622 patients (304 males and 318 females) with a mean age of 36,92 ( $\pm 10,85$ ). Idiopathic coronal resorption was present in 26 of the 622 patients with a frequency of 4.2%. One patient had two teeth with idiopathic coronal resorption; resulting in as 27 teeth and a frequency of 2.7% according to tooth number. There were 13 (50%) females and 13 (50%) males having idiopathic coronal resorption. There was no significant difference between genders ( $p > 0.05$ ). The presence of idiopathic coronal resorption increased with advanced age ( $v: 0,193, p < 0.05$ ). There was no statistically significant difference between the extent of the coronal resorption and age ( $p > 0.05$ ).

## Conclusion





The presence of idiopathic coronal resorption increases with advancing age. Idiopathic coronal resorption is detected incidentally during radiographic examination. Thus, dentists should consider this situation and should perform periodically radiographic examination of impacted teeth.

**Keywords:** Impacted teeth, Coronal, Resorption, Idiopathic, Panoramic radiography

## Introduction

Intracoronary resorption has been described as a well-circumscribed radiolucent area, occurring within the coronal tooth tissue of unerupted teeth (1-3). Formerly, it was thought to be dental caries or caries-like lesion and it was named as 'intra-follicular caries', 'lesions resembling caries', 'pre-eruptive caries' (4-6). In the light of histologic findings, case reports have suggested that these conditions are likely to be resorptive in nature (1-3, 7, 8). The etiology of intracoronary resorption in unerupted teeth is not fully understood (6, 9) and the inducing factor of resorption remains unknown (9). For the last 20 years, these findings have been called as 'idiopathic external resorption, pre-eruptive intracoronary resorption and idiopathic coronal resorption' (1, 2, 7, 10-12). In this article the term 'idiopathic coronal resorption' was used because teeth which completed their pre-eruptive period were included.

Teeth having idiopathic coronal resorption are detected incidentally during radiographic examination (13, 14). The radiographic image of

Fatma Nur Yıldız<sup>1</sup> ,  
Umut Pamukçu<sup>2</sup> ,  
Bülent Altunkaynak<sup>3</sup> ,  
İlkay Peker<sup>1</sup> ,  
Zühre Zafersoy Akarslan<sup>1</sup> 

ORCID IDs of the authors: F.N.Y. 0000-0002-9467-5572;  
U.P. 0000-0001-8356-8344; B.A. 0000-0002-7571-2155;  
İ.P. 0000-0002-2888-2979; Z.Z.A. 0000-0001-9237-412X

\*This study has been presented as an oral presentation in the 23rd Congress of the BaSS in Romania in 2018.

<sup>1</sup>Gazi University, Faculty of Dentistry, Department of Oral and Maxillofacial Radiology, Ankara, Turkey

<sup>2</sup>Ministry of health, Kırıkkale Community Health Center, Kırıkkale, Turkey

<sup>3</sup>Gazi University, Faculty of Sciences, Department of Statistics, Ankara, Turkey

Corresponding Author: Fatma Nur Yıldız

E-mail: fn.yildiz89@gmail.com

Received: 15 November 2019

Revised: 21 April 2020

Accepted: 16 September 2020

DOI: 10.26650/eor.20210130

the pathology is a ghost-like crown and replacement of resorbed tooth by bone (1). In literature, this issue has been investigated in many studies including case reports and research articles. Most of the case reports were pediatric patients (2, 9, 11, 15-17), and the original studies were conducted among either pediatric or adults (6, 9, 10, 18). The previous research articles have been mostly focused on the prevalence and characteristics of the teeth with idiopathic coronal resorption. Although Mensah et al. (19) reported that the presence of resorption could not be correlated to age or gender, according to best of our knowledge, the relationship between the prevalence of coronal resorption and age were not evaluated. There is the need for studies regarding the effect of advancing age on the occurrence of idiopathic coronal resorption.

In this study, we included individuals who were older than twenty-five years old by considering the eruption duration of third molars. We hypothesized that the likelihood of idiopathic coronal resorption increase with advancing age and the extent of idiopathic coronal resorption is not correlated with advancing age.

## Materials and Methods

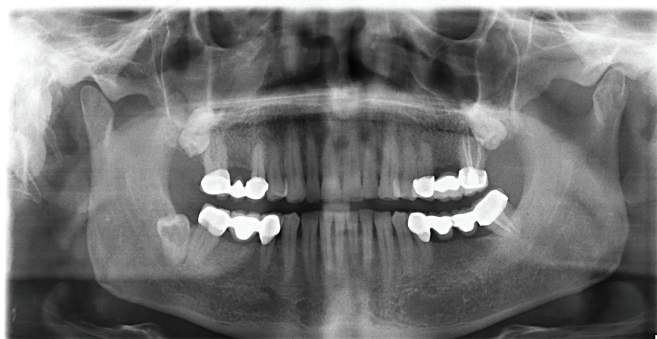
Before the study, ethical approval was obtained from Gazi University Clinical Research Ethics Committee (Research code no: 2018-63). This study was done in accordance with the principles defined in the Declaration of Helsinki, including all revisions.

Digital panoramic radiographs were taken with the Sirona Orthophos XG (Sirona, Bensheim, Germany) and were performed following technical parameters; 66-73 kVp, 8-15 mA and 14.1 second exposure time. The panoramic radiographs with artifact, bony pathology in the regions of interest were excluded from the study. The panoramic radiographs of patients having at least one impacted tooth were examined in this study. An impacted tooth was defined as completely covered by bone and/or mucosa and under the occlusal plane.

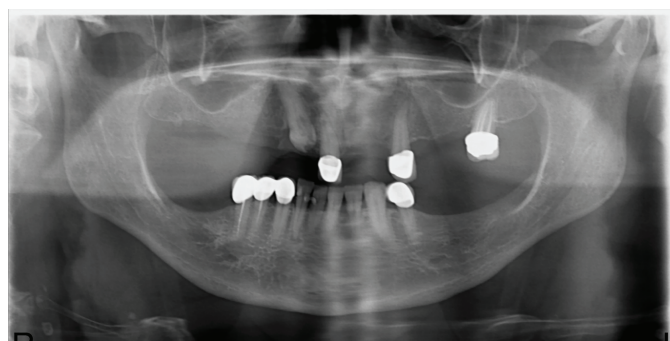
Images of 3405 patients aged between 25 and 89 (mean age  $44,16 \pm 13,034$ ) were retrospectively examined by two oral and maxillofacial radiologists (F.N.Y., U.P.). The examiners were calibrated by at least 17 years of experienced two dentomaxillofacial radiologists (Z.A., İ.P.) to recognize and agree on coronal resorption for permanent teeth as well as to identify the tooth and its surrounding structures. Radiolucencies having a linear appearance resembling buccal grooves on molars were not evaluated as idiopathic coronal resorption. 'An impacted tooth with coronal resorption that deviated from the normal eruption pathway was accepted as ectopically positioned' (6) and it were categorized into the following groups according to tooth angle: horizontal, vertical, mesioangular, distoangular and semivertical (20, 21). The extent of resorptions were determined according to the classification in the study by Seow et al. (9) 'The size of each defect relative to coronal dentin thickness was also noted as to whether it was within one-third dentin thickness (score 1), or two-thirds dentin thickness (score 2), or extended through the full dentin thickness (score 3) of the crown' (9) (Figures 1-4). The patient's age, gender, number of impacted teeth, number and position of teeth with idiopathic coronal resorption and the extent of each resorption were recorded on standard forms. Cases presenting disagreement was solved with of forced consensus.

## Statistical analysis

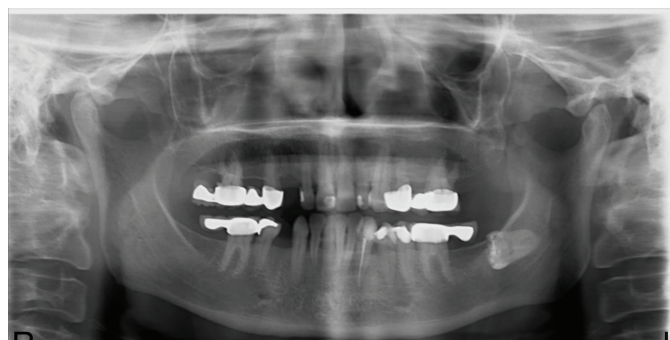Descriptive analysis was calculated for demographic data and impacted teeth. Coronal resorption is nominal (0=Absent and 1=Present) and age is numerical, binary logistic analysis is used in the relationship between coronal resorption and age. The sig-



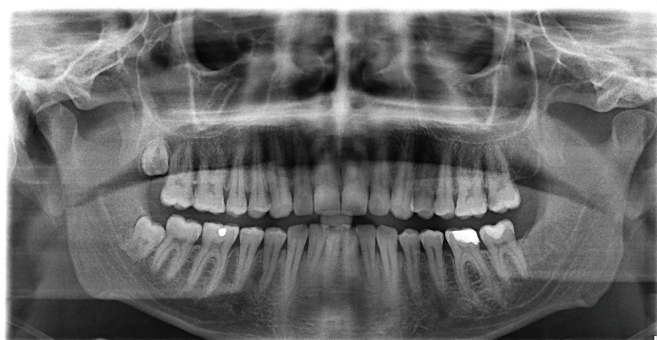**Figure 1.** Coronal resorption in an impacted mandibular right third molar, which was scored as 3.



**Figure 2.** Coronal resorption in an impacted maxillary right canine, which was scored as 1.



**Figure 3.** Coronal resorption in an impacted mandibular left third molar, which was scored as 2.



**Figure 4.** Coronal resorption in an impacted maxillary right third molar, which was scored as 3.

nificance coefficient in the tests was accepted as 0.05. All of the statistical analysis was performed with IBM SPSS v.22 program. (Statistical Package for Social Science, IBM Corporation, NY-USA).

**Results**

Of the 3405 individuals, 622 (304 males, 318 females) had at least one impacted tooth, with a prevalence of 18.3%. A thousand and nine impacted teeth were observed in 622 patients with a mean age of 36.9±10.8 (range: 25-75 years). Idiopathic coronal resorption was identified in 26 of the 622 patients with a frequency of 4.2%. One patient had two teeth with idiopathic coronal resorption; resulting in 27 teeth and a frequency of 2.7% according to tooth number (Table 1).

**Table 1.** Idiopathic coronal resorption in impacted permanent teeth and its relationship with age: radiologic study. Prevalence of patients with impacted teeth and idiopathic coronal resorption

Subjects	Patient with impacted teeth			Teeth with coronal resorption		
	Absent	Present (%)	Total (%)	Absent (%)	Present (%)	Total (%)
Total no.	2783	622 (4.2)	3405 (100)	982 (97.3)	27 (2.7)	1009 (100)
Male	1280	304 (19.1)	1584 (100)	477 (97.35)	13 (2.65)	490 (100)
Female	1503	318 (17.4)	1821 (100)	505 (97.3)	14(2.7)	519 (100)

There were 13 females (50%) and 13 (50%) males with idiopathic coronal resorption. There was no significant difference between genders (p>0.05).

Significant positive correlation was found between the presence of idiopathic coronal resorption and age (B=0.08, p<0.05, Table 2).

**Table 2.** Idiopathic coronal resorption in impacted permanent teeth and its relationship with age: radiologic study. The estimated coefficients of the binary logistic model

Independent Variables	B	SE	P	OR
Constant	-6.45	0.756	0.000	0.002
Age	0.08	0.015	0.000	1.083

SE = standard error, OR = Odds Ratio

**Table 3.** Idiopathic coronal resorption in impacted permanent teeth and its relationship with age: radiologic study. Number of teeth with coronal resorption in relation to the type and position

	Vertical		Horizontal		Mesio-angular		Disto-angular		Semi-vertical		Total
	Right	Left	Right	Left	Right	Left	Right	Left	Right	Left	
Maxillar third molar	2	2			1		1	1			7
Maxillar second premolar	2										2
Maxillar canine	1		1	1					2	4	9
Mandibular third molar			4	1	1	1	1				8
Mandibular canine	1										1
Total	6	2	5	2	2	1	2	1	2	4	27

Idiopathic coronal resorptions were seen in both the maxillae and mandible. Eighteen affected teeth were in the maxillae (66.6%), and 9 were located in the mandible (33.4 %). Seventeen of the 27 teeth were observed on the right side (63%) and 10 of the teeth were observed on the left side of the jaws (37%) (Table 3).

Of the 27 teeth with coronal resorption, 9 were located in maxillary canines, followed by 8 mandibular third molars, 7 maxillary third molars, 2 maxillary second premolars and 1 mandibular canine. Eight of the 27 teeth were positioned as vertical and 19 of the teeth were ectopically (horizontal, distoangular, mesioangular, semivertical) (Table 3).

For the extent of the resorptions scored relative to the width of dentine thickness, scores of 1 and 2 were equally identified on 10 teeth (37%), and a score of 3 was identified on 7 teeth (26%). There was no statistically significant difference between the extent of coronal resorption and age (p>0.05).

**Discussion**

Idiopathic coronal resorptions are seen as incidental findings on radiographs of impacted teeth (9). The radiographic method may affect the diagnosis; thus the prevalence, of coronal resorption (6, 9, 10). The subject prevalence of idiopathic coronal resorption was reported as 3%, and tooth prevalence as 0.5% on panoramic radiographs (9). On the other hand, subject prevalence was reported as 6% and tooth prevalence as 2% on bitewing radiographs (18). Panoramic radiographs do not clearly evaluate the anterior and maxillary premolar and molar regions, and resorptions in these regions may have been missed (6, 9). However, impacted third molars; which are most often impacted in the jaws, can be observed and examined more clearly on panoramic radiographs (9). Therefore, the panoramic radiographs of patients who were 25 years old and over were examined in this study.

The prevalence of idiopathic coronal resorption was found as % 4.2-2.7 according to the subjects and teeth, respectively. In a similar study, idiopathic coronal resorption was identified as 1.55% according to subjects and 0.95% according to teeth (6). In other studies, Seow et al. (9) reported 3% subject prevalence; 0.5% teeth prevalence and Uzun et al. (10) reported 0.7% subject prevalence. The results of our study showed higher values compared to the other studies. This could be related with the age of the patients in our study. Unlike other studies, pediatric or young adult individuals did not included in our study. The age range of the subjects in



our study was 25-89 and it was found that idiopathic coronal resorption increased with advancing age.

According to our results gender did not have an effect on idiopathic coronal resorption, similar to other studies (6, 9, 10). Usually, one tooth was diagnosed as having idiopathic coronal resorption in an individual, however, more than one tooth having idiopathic coronal resorption in the same individual have been reported by other researchers (16, 22-24). In this study, two affected teeth were observed in only one female patient.

All the coronal resorptions were noted adjacent to the amelodentinal junction, and extended from this area to various depths within the tooth. In the present study, the scores of 1 and 2 were equally and most prevalent (37 %), and the prevalence of a score of 3 was 26 %. In the literature, there were studies that reporting a score of 2 (39.3-50 %) (6, 10) or 3 (40 %) (9) was most prevalent. Mensah et al. (19) reported that there were completely resorbed mesiodentes in individuals aged 18-25 years. Similarly, according to our results, advancing age did not have an effect on the extent of idiopathic coronal resorption.

The mechanism behind the resorption of impacted teeth is unclear and several theories have been proposed (6, 9, 25). Ectopic positioning of a tooth may be a local factor in the initiation of coronal resorptions (9). In the present study, the positions apart from the vertical position were recorded as ectopic position and 70.4% of teeth with coronal resorption found to be at ectopic position. Seow et al. (9) found that 28% of teeth with ectopic positioning were related with coronal resorptions on the tooth or an adjacent tooth. It was proposed that prolonged pre-eruptive period increases the probability of coronal resorption (13). The knowledge that idiopathic coronal resorption increased with advancing age supports this hypothesis.

On the other hand, it was suggested that the resorptive cells originating from the surrounding bone probably enter the developing tooth through crossing the dental follicle and enamel (14). When the tooth is impacted, the resorptive process may be progressive (13, 14). This process destroys the tooth structure and it is usually replaced by bone (26). Mensah et al. (19) reported that idiopathic resorption was found in 41% of the impacted mesiodentes and observed that some teeth completely resorpted at long-term follow-up results. It was suggested that impacted teeth may resorb and vanish spontaneously (19). This theory may be true, although we did not encounter any tooth with completely resorption. Only resorption both at the crown and the root of the tooth was detected in a few patients. Clinical reports and long-term follow-up are needed on this issue. Additionally, the progressive process may be due to hypomineralized dentin or the abnormal development of the dental follicle (2). On the other hand, in literature, it was reported two cases report with generalized familial crown resorptions in unerupted teeth in Turkey (27). The authors suggested that the cases may be either autosomal dominant or x-linked dominant (27). However, no additional study and/or case report have not been reported regarding this issue to date. In this study, no familial originate cannot be asked to subject due to this study was designed as retrospective radiologic research. The familial originate of intracoronal resorption should be investigated in further studies.

The clinician must choose a suitable treatment modality for teeth with idiopathic coronal resorption. In the literature, extraction, eruption and radiographic follow-up were recommended as treatment options for children and young adults (2). Periodic follow-up is necessary in cases don't having any complications related with the impacted tooth in adults.

Idiopathic coronal resorption was generally, identified in the third molar and canine teeth in this study. It was not detected in the first molar, second molar and first premolar teeth. This could be due to the very low impaction rate of these teeth. In addition the impacted teeth could be extracted during childhood and young adulthood. Thus, we could not share information about these because we do not have data regarding this issue.

## Conclusion

The presence of idiopathic coronal resorption increases with advancing age. As this situation is detected incidentally during radiographic examination, dentists should periodically perform radiographic examination.

**Ethics Committee Approval:** The ethical approval was obtained from Gazi University Clinical Research Ethics Committee (Research code no: 2018-63).

**Informed Consent:** Participants provided informed consent.

**Peer-review:** Externally peer-reviewed.

**Author contributions:** FNY, BA and IP designed the study. FNY, UP and BA participated in generating the data for the study FNY and UP participated in gathering the data for the study. BA participated in the analysis of the data. FNY wrote the majority of the original draft of the paper. FNY, IP and ZZA participated in writing the paper. All authors approved the final version of this paper.

**Conflict of Interest:** Authors declared no conflict of interest.

**Financial Disclosure:** The authors declared that they have received no financial support.

**Türkçe Özet:** Gömülü Daimi Dişlerde İdiyopatik Koronal Rezorpsiyon Ve Yaşla İlişkisi: Radyolojik Çalışma. Amaç: Bu çalışmanın amacı yetişkin hastalarda idiyopatik koronal rezorpsiyon ve yaş arasındaki ilişkiyi değerlendirmektir. Gereç ve Yöntem: Radyoloji departmanının arşivinde bulunan 25 yaş ve üstü 1584 erkek ve 1821 kadına ait 3405 dijital panoramik radyograf iki ağız, diş ve çene radyoloji uzmanı tarafından değerlendirildi. Hastaların yaşı, cinsiyeti, gömülü diş sayısı, idiyopatik koronal rezorpsiyon görülen diş sayısı ve pozisyonları ile koronal rezorpsiyonun genişliği standart formlara kaydedildi. Bulgular: Yaş ortalaması 36.92 (±10.85) olan 622 hastada (304 erkek and 318 kadın) 1009 adet gömülü diş saptandı. Altı yüz yirmi iki hastanın 26'sında (%4.2) idiyopatik koronal rezorpsiyon belirlendi. İdiyopatik koronal rezorpsiyon, bir hastanın iki dişinde olduğundan dolayı 27 dişte görüldü ve diş sayısına göre idiyopatik rezorpsiyon görülme sıklığı 2.7% olarak bulundu. 13 kadın (50%) ve 13 erkekte (50%) idiyopatik koronal rezorpsiyon vardı. Cinsiyetler arasında anlamlı bir farklılık bulunmadı ( $p>0.05$ ). İlerleyen yaşla birlikte idiyopatik koronal rezorpsiyonun arttığı belirlendi ( $v: 0.193, p<0.05$ ). Koronal rezorpsiyonun genişliği ve yaş arasında istatistiksel olarak anlamlı bir farklılık bulunmadı ( $p>0.05$ ). Sonuç: Yaşın ilerlemesiyle birlikte gömülü dişlerde idiyopatik koronal rezorpsiyon oluşumu artmaktadır. İdiyopatik koronal rezorpsiyon radyografik muayene esnasında tesadüfen tespit edilmektedir. Bu nedenle, diş hekimleri bu durumu göz önünde bulundurmalı ve gömülü dişlerin periyodik olarak radyografik muayenesini yapmalıdır. Anahtar Kelimeler: Gömülü diş, Koronal, Rezorpsiyon, İdiyopatik, Panoramik radyografi

## References

1. Klambani M, Lussi A, Ruf S. Radiolucent lesion of an unerupted mandibular molar. *American journal of orthodontics and dentofacial orthopedics* 2005;127: 67-71. [\[CrossRef\]](#)
2. Wong L, Khan S. Occult caries or pre-eruptive intracoronal resorption? A chance finding on a radiograph. *Pediatric dentistry* 2014;36: 429-32.
3. McNamara C, Foley T, O'Sullivan V, Crowley N, McConnell R. External resorption presenting as an intracoronal radiolucent lesion in a pre-eruptive tooth. *Oral diseases* 1997;3:199-201. [\[CrossRef\]](#)
4. Skillen W. So-called intra-follicular caries. *Ill Dent J* 1941; 10: 307-8.
5. Skaff DM, Dilzell WW. Lesions resembling caries in unerupted teeth. *Oral Surgery, Oral Medicine, Oral Pathology and Oral Radiology* 1978;45:643-6. [\[CrossRef\]](#)
6. Özden B, Acikgoz A. Prevalence and characteristics of intracoronal resorption in unerupted teeth in the permanent dentition: a retrospective study. *Oral Radiology* 2009;25:6. [\[CrossRef\]](#)
7. Manan N, Mallineni S, King N. Idiopathic pre-eruptive coronal resorption of a maxillary permanent canine. *European Archives of Paediatric Dentistry* 2012;13:98-101. [\[CrossRef\]](#)
8. Owens P, Wangrangsimakul K, O'Brien F. Idiopathic external resorption of teeth. *Journal of Oral Pathology & Medicine* 1988;17:404-8. [\[CrossRef\]](#)
9. Seow WK, Lu P, McAllan L. Prevalence of pre-eruptive intracoronal dentin defects from panoramic radiographs. *Pediatric dentistry* 1999;21:332-9.
10. Uzun I, Gunduz K, Canitezer G, Avsever H, Orhan K: A retrospective analysis of prevalence and characteristics of pre-eruptive intracoronal resorption in unerupted teeth of the permanent dentition: a multicentre study. *International endodontic journal* 2015;48:1069-76. [\[CrossRef\]](#)
11. Davidovich E, Kreiner B, Peretz B. Treatment of severe pre-eruptive intracoronal resorption of a permanent second molar. *Pediatric dentistry* 2005;27:74-7.
12. Seow WK: Pre-eruptive intracoronal resorption as an entity of occult caries. *Pediatric dentistry* 2000;22:370-6.
13. Holan G, Eidelman E, Mass E: Pre-eruptive coronal resorption of permanent teeth: report of three cases and their treatments. *Pediatric dentistry* 1994;16:373.
14. Seow WK, Hackley FD. Pre-eruptive resorption of dentin in the primary and permanent dentitions: case reports and literature review. *Pediatric dentistry* 1996;18.
15. Rankow H, Croll TP, Miller AS. Preeruptive idiopathic coronal resorption of permanent teeth in children. *Journal of endodontics* 1986;12:36-9. [\[CrossRef\]](#)
16. Hata H, Abe M, Mayanagi H. Multiple lesions of intracoronal resorption of permanent teeth in the developing dentition: a case report. *Pediatric dentistry* 2007;29:420-5.
17. O'Neal KM, Gound TG, Cohen DM: Preeruptive idiopathic coronal resorption: A case report. *Journal of endodontics* 1997;23: 58-9. [\[CrossRef\]](#)
18. Seow WK, Wan A, McAllan LH. The prevalence of pre-eruptive dentin radiolucencies in the permanent dentition. *Pediatric dentistry* 1999;21:26-33.
19. Mensah T, Garvald H, Grindefjord M, Robertson A, Koch G, Ullbro C: Idiopathic resorption of impacted mesiodentes: a radiographic study. *European Archives of Paediatric Dentistry* 2015;16:291-6. [\[CrossRef\]](#)
20. Pell GJ: Impacted mandibular third molars: classification and modified techniques for removal. *Dent Digest* 1933;39:330-8.
21. Archer WH. *Oral and maxillofacial surgery*. WB Saunders 1975;1045-87.
22. Seow WK: Multiple pre-eruptive intracoronal radiolucent lesions in the permanent dentition: case report. *Pediatr Dent* 1998;20:195-8.
23. Walton J: Dentin radiolucencies in unerupted teeth: report of two cases. *ASDC journal of dentistry for children* 1980;47:183.
24. Wood P, Crozier DS: Radiolucent lesions resembling caries in the dentine of permanent teeth. A report of sixteen cases. *Australian dental journal* 1985;30:169-73. [\[CrossRef\]](#)
25. Blackwood H. Resorption of enamel and dentine in the unerupted tooth. *Oral Surgery, Oral Medicine, Oral Pathology* 1958;11:79-85. [\[CrossRef\]](#)
26. Brooks JK. Detection of intracoronal resorption in an unerupted developing premolar: report of case. *The Journal of the American Dental Association* 1988;116:857-9. [\[CrossRef\]](#)
27. Miloglu O, Goregen M, Akgul HM, Harorli A: Generalized familial crown resorptions in unerupted teeth. *European journal of dentistry* 2011;5:206. [\[CrossRef\]](#)