

# Pctx1 venom in the treatment of vasospasm due to experimental subarachnoidal hemorrhage

✉ Mehmet Yiğit Akgün<sup>1</sup>, ✉ Mehmet Hüseyin Akgül<sup>2</sup>

<sup>1</sup>Department of Neurosurgery, Koç University Hospital, İstanbul, Turkey

<sup>2</sup>Department of Neurosurgery, Yüksek İhtisas State Hospital, Kırikkale, Turkey

**Cite this article as:** Akgün MY, Akgül MH. Pctx1 venom in the treatment of vasospasm due to experimental subarachnoidal hemorrhage. *J Health Sci Med.* 2023;6(6):1230-1236.

Received: 17.08.2023

Accepted: 01.10.2023

Published: 29.10.2023

## ABSTRACT

**Aims:** We aimed to investigate the role of neuron damage in experimental animals following vasospasm, by increasing perfusion of neuronal tissue through vasodilation using the venom of PcTx1, and to determine its effectiveness in reducing neuron damage after vasospasm.

**Methods:** Thirty adult male Wistar albino rats weighing between 300 and 400 grams were used and divided into three groups: the Sham group (Group 1, n=10), to which no application was made; the SAH (control) group (Group 2, n=10), in which a double SAH model was created and 1 cc of saline was administered intraperitoneally; and the SAH+PcTx1 group (Group 3, n=10), in which a double SAH model was created and 1 cc/kg of PcTx1 venom was administered intraperitoneally daily. Basilar artery diameter and immunochemical measurements were performed histopathologically, and neurohistopathological findings were scored semiquantitatively in terms of vascular changes, neuron degeneration, gliosis, and bleeding criteria using a scale of 0 (none), 1 (mild), 2 (moderate), or 3 (severe). eNOS immunopositivity was also evaluated. The detection of apoptosis in the brain was performed by evaluating the effector enzyme caspase-3 immunoreactivity of the exogenous apoptosis pathway.

**Results:** The most severe vascular spasm and degeneration-necrosis of brain tissue gray matter neurons were seen in Group 2, whereas the vascular narrowing was less severe in Group 3. Brain parenchyma and neuron and neuroglial reactions were milder in Group 3. eNOS expression was detected at a higher level in Group 1, Group 2, and Group 3, respectively. For apoptosis and caspase-3 immunoreactivity of the exogenous apoptosis pathway, no immunopositive reactions were observed in Group 1.

**Conclusion:** For the occurrence and formation mechanisms of vasospasm after subarachnoid hemorrhage, this pathological condition is thought to result from multifactorial and various biochemical reactions. In our study, it was found that psalmotoxin effectively prevented vasospasm and significantly reduced tissue damage after vasospasm.

**Keywords:** Experimental subarachnoidal hemorrhage, psalmotoxin, venom, vasospasm

## INTRODUCTION

Subarachnoid hemorrhage (SAH) is a condition in which blood spreads to the subarachnoidal space due to various pathologies. The first condition of vasospasm-related mortality and morbidity reduction is to take preventive measures in the patient who has had aneurysmal SAH and whose aneurysm has been successfully clipped with surgical intervention, to monitor the patient very closely on the most risky days in terms of vasospasm and to intervene with the least suspicious energetic treatment.<sup>1-8</sup>

Cerebral vasospasm is the main cause of focal cerebral ischemia after subarachnoid hemorrhage. The vasospasm is most risky complication for subarachnoid hemorrhage in terms of mortality and morbidity.<sup>9-11</sup>

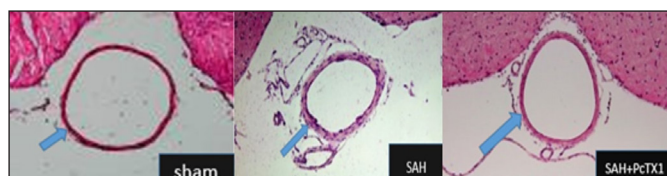
Although the physiopathology of cerebral vasospasm is not conclusive, there is no doubt that blood reaching subarachnoid distance causes the development of cerebral vasospasm. Experimental studies have shown that blood injected to subarachnoid distance causes vasospasm.

Vasoactive substances are released as a result of hemolysis of erythrocytes reaching subarachnoid distance. In vitro and in vivo studies have shown that oxyhemoglobin is the main culprit in the development of vasospasm among these substances. Oxyhemoglobin causes the secretion of vasoconstrictor prostaglandins from endothelial cells. It has been shown in various experimental models that vasoactive prostaglandins of PGF<sub>2</sub>-alpha, PGD<sub>2</sub>, PGE<sub>2</sub> and thromboxane A<sub>2</sub> increase in vasospasm, which are products of arachidonic acid metabolism.<sup>12-17</sup>

**Corresponding Author:** Mehmet Yigit Akgün, myigitakgun@gmail.com

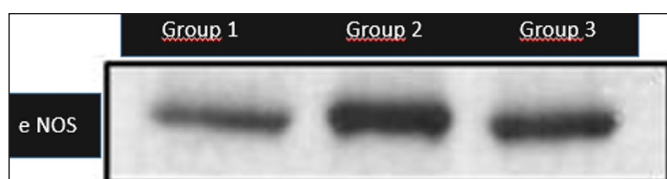

The effect of free radicals in the etiology of cerebral vasospasm has also been investigated in experimental and clinical studies. Superoxide anion radical emerges during methemoglobine autoxidation of oxyhemoglobin.<sup>18</sup> In addition, iron compounds emitted into the environment during the destruction of hemoglobin catalyze the Haber-Weiss reaction, resulting in the emergence of hydroxyl radical (OH) from the most reactive radicals. Many drugs are still being tried in the treatment of symptomatic vasospasm, which is defined as a syndrome caused by ischemic signs and symptoms associated with progressive narrowing of cerebral vessels. Acid detection ion channel 1a (ASIC1a) is the basic acid sensor in the mammalian brain and plays an important role in neuronal damage after cerebral ischemia. Evidence of neuroprotective effect of ASIC1a inhibition was obtained by using "PcTx1 venom" from tarantula *Psalmopoeus cambridgei* before. The observed neuron protective effect of this ASIC1a selective inhibitor PcTx1 has been shown in the literature that PcTx1 is due to hundreds of ASIC1a ion channel blockades or blocking of other ion channels and receptors.<sup>19-23</sup> (Figure 1).



**Figure 1.** Induced vasospasm after experimental SAH. The hematoxylin-eosin-stained sectional pictures of the basilar artery indicated by the blue arrow group 1, group 2 and group 3 are shown. In rats with SAH treated with PcTx1 venom, the basilar artery lumen area appears to be dilated. (Scale bars=200 µm).

For this reason, it was thought that PcTx1 venom may be effective in vasospasm through direct inhibition of ASIC1a. Severe oxygen depletion that occurs during ischemic stroke causes acidosis through increased lactate levels in order. Anaerobic glycolysis oxidative phosphorylation causes brain damage. pH drops and this severe ischemia occurs.<sup>13-15</sup> In vivo studies show that acidosis increases ischemic brain injury and has been shown to have a direct correlation between brain acidosis and infarct size. Acidosis caused by decrease in cerebral pH can be activated by acid-sensing ion channels (ASIC) and this activation has been suggested to play a critical role in stroke caused by neuronal damage.<sup>24</sup> (Figure 2).



**Figure 2:** The picture shows a representative Western blots investigating endothelial nitric oxide synthase levels (eNOS) in brain tissue.

ASIC has been observed to be depolarized with sensory neurons in response to a sudden drop in pH for almost 20 years. 13 Although ASICs are belong to the sodium canal of the epithelial tissue, it is also associated with a decrease in extracellular pH and calcium channels. 5 PcTx1, the most powerful and selective inhibitor of ASIC1a, is a 40-residue peptide isolated from the tarantula *psalmopoeus cambridgei* venom.<sup>20</sup> In studies in ischemic stroke models, PcTx1 has been proven to be neuroprotective.<sup>21-23</sup> In a rat model with transient focal ischemia (middle cerebral artery occlusion), 30 minutes ago and after ischemia induction, PcTx1 venom injection alleviates infarction by 60% and PcTx1 venom has an effect via ASIC1a.<sup>14</sup> These observations have improved our understanding of stroke pathophysiology and made it a therapeutic candidate for the development of neuron preservatives for stroke treatment. We wanted to investigate this activity by vasodilating through ASIC1a inhibition in the treatment of vasospasm after experimental cerebral subarachnoidal hemorrhage. For the occurrence and formation mechanisms of vasospasm after subarachnoid hemorrhage, this pathological condition is thought to result from multifactorial and various biochemical reactions.

In the present study, investigated the role of neuron damage in experimental animals after vasospasm in preventing neuron damage by increasing the perfusion of neuronal tissue by vasodilatation with venom of PcTx1 and its effectiveness in reducing neuron damage after vasospasm.

## METHODS

This study was carried out between 2016-2019 in Kırıkkale University Faculty of Medicine Laboratory of Experimental Animals after the approval of Kırıkkale University Animal Experiments Local Ethics Committee (Date: 02.02.2016, Decision No:16/01-16/18). The materials were evaluated in the Laboratory. All animals received humane care in compliance with the principles of laboratory animal care developed by the National Academy of Sciences.

### In Vivo Rat Model

In our study, apart from the neuron protective effect, the effect of PcTx1 venom on vasospasm was investigated by applying an experimental subarachnoidal hemorrhage model in Wistar albino rats weighing 300-400 g. Rats were housed in ad libitum environment at least 1 week and after that the experiment began.

Thirty adult male Wistar albino rats weighing between 300 and 400 grams were used and were divided into three groups:

Sham group (Group 1, n: 10): No application was made to the control-sham group.

Experimental SAH control group (Group 2, n: 10): Experimental SAH (autologous blood injection into cisterna magna of rats in this study) was created in the control group. After the first hemorrhage, a double SAH model was used at 48<sup>th</sup> hour and 1 cc normal saline was administered intraperitoneally.<sup>23</sup>

Experimental SAH+PcTx1 group (Group 3, n: 10): Experimental group underwent a double SAH model repeated at 48 hours after the creation of experimental SAH and first bleeding. Then, 1 cc / kg PcTx1 venoma (Tarantula D6, Richter Pharma AG, Austria) was administered intraperitoneally daily.<sup>23</sup>

On the 14<sup>th</sup> day, all groups were sacrificed. The brain of the rats was excised and basilar artery diameter and immunochemical measurements were performed histopathologically. Neurohistopathological findings were scored semiquantitatively in terms of vascular changes, neuron degeneration, gliosis and bleeding criteria and 0=None; 1=Mild, 2=Moderate and 3=Severe.

### Double Sah Model

Ketamine Hydrochloride (Ketalar flacon, Pfizer) 60 mg/kg and Xylazine (Rhompun 2% injectable flacon, Bayer) 12 mg /kg intraperitoneal (i.p.) were applied to all rats after twelve hours of starvation to provide general anesthesia. The prone position was detected and operation site cleaning was performed with 10% povidone iodine solution (Batticon 10%, Adeka Pharmaceutical Industry). Subarachnoid space was reached by puncture with 23G cannula from occipito-atlantal distance by bringing head flexion. Autologous blood injection was performed to Cisterna magna and experimental subarachnoid hemorrhage (SAH) was created. 48-hour after the first bleeding, the dual SAH model was used by repeating the same procedure.<sup>23</sup> On the 14<sup>th</sup> day, high dose ketamine hydrochloride (Ketalar flacon, Pfizer) 100 mg/kg and Xylazine (Rhompun 2% injectable flacon, Bayer) were administered as 12 mg/kg i.p. The rats underwent bilateral fronto-parieto-occipital craniectomy. The cerebrum, cerebellum and brainstem remaining on the foramen magnum have been removed to preserve their total anatomical integrity. Then the rats were sacrificed.

### Histopathological Examination

After euthanasia, each rat's brain was removed and detected for 48 hours in 4% buffered paraformaldehyde. After 24 hours of washing under running water, the fixed tissues were treated for routine follow-up after being treated with alcohol (50%, 60%, 70% ,90% and absolute alcohol) and xylol, and paraffin burial was

performed. Sections with a thickness of 5 µm were obtained from each block. The sections taken were stained with hematoxylin-eosin and analyzed by immunohistochemical staining for eNOS and apoptosis (eNOS and apoptosis) procedures.

### Immunoperoxidase Examination

In order to determine the presence of the relevant antigen in the tissues under examination, a streptavidin-biotin immunoperoxidase kit was used in accordance with the kit's procedure. The sections were deparaffinized in xylene and then kept in distilled water for 5 minutes before being rehydrated in a graded alcohol series. The tissues' hydrogen peroxidase activity was eliminated by holding them in 3% peroxide for 15 minutes. After a 20-minute boiling in sodium citrate (pH 6.0), the antigen retrieval process was performed. The tissues were then held in protein blocking serum for 7 minutes and incubated in 1/200 dilution prepared eNOs and Caspase-3 antigen-specific monoclonal antibodies at room temperature for 1 hour. After 15 minutes of secondary antiserum labeled with biotin, the tissues were exposed to the enzyme streptavidin peroxidase for 15 minutes. The Aminoethyl Carbazole (AEC) chromogen was dripped for the color process, and Mayer's hematoxylin was used for 1-2 minutes for counter-staining. After this process, the painted tissues were covered with water-based adhesive.

### Basillary Artery Diameter Measurement

The sections obtained from each rat were evaluated by light microscope. Among the series sections taken for the measurement, the section with the most appropriate viewing was selected. By examining the preparations, the basillary artery diameters were evaluated in the BAB Bs200pro program using the Olympus BX 51 (Japanese) computer-aided microscope system and photographed. In the basillary artery images, image-processing and system analysis measured by an impartial observer who did not know the groups. 10 measurements extending from four sections of each subjects to the vascular lumen were made and their standard deviations and averages were calculated ([Figure 1](#)).

### Statistical Analysis

SPSS 20 (IBM SPSS Incorporated, Chicago, IL, USA) were used for the analysis. Kruskal-Wallis variance analysis and Mann Whitney U test with Bonferroni adjustment were used. A p value <0.05 was considered for significance. When Bonferroni adjustment was performed, padjusted<0.0175 was considered for significance.

## RESULTS

Neurohistopathological findings, vascular changes, neuron degeneration, gliosis and bleeding criteria were scored semicantatively and accordingly 0=None; 1=Mild, 2=Moderate and 3=Severe.

eNOS,apopitosis, vascular changes, neuronal degeneration, gliosis scores and basillar artery diameter measurement results were shown on **Table 1**. The difference between groups were statistically significant (p<0.05). To find the values which caused difference, Pairwise comparisons by Mann Whitney U Test with Bonferroni Adjustment were performed and p adjusted <0.0175 is considered as statistically significant.

- eNOS values of the Group 1 was statistically higher than those in Group 2; and Group 3 (padjusted<0.0175) (**Table 2**).
- Apopitosis values of Group 3 was significantly lower than those in Group 1 and Group 2 (padjusted<0.0175) (**Table 2**).
- Vascular changes, neuronal degeneration, gliosis scores were found as group 2>group 3 (Experimental PcTx1 group) >group 1 (padjusted<0.0175) (**Table 2**).
- Basillar artery diameter values of Group 3 was significantly higher than those in Group 1 and Group 2 (padjusted<0.0175) (**Table 1**). Basillar artery diameter of Group 2 was also lower than group 1 (padjusted<0.0175) (**Table 1**).

### Histopathological Findings

According to histopathological findings obtained in the study, the most advanced vascular spasm and degeneration-necrosis in brain tissue gray matter neurons are seen in the experimental SAH group 2. Whereas in the brains of the

group 3, vascular contraction is milder and consequently neuron and neuroglial reactions appear to be slightly shaped. The group 1 had minimal pathological changes among all groups, and histological findings are limited to bleeding only in the meningeal tissues surrounding the brain root.

**Group 1 (Sham):** In brain tissues of healthy rats, in addition to minimal hyperemia in the meningeal tissues surrounding cudex cerebri, cerebellum, pons and medulla oblongata, hemorrhage areas were observed in 3 cases, limited to the meningeal region. Neuron and neuroglial tissues had a normal histological appearance. These histopathological changes were interpreted as changes after meningeal damage during the extraction of brain tissue (**Figure 1**).

**Group 2 (SAH-control):** The common finding of the brain tissues examined was characterized by free erythrocyte piles compatible with bilateral hematoma, partly around the cerebellum meninx tissues with pons and medulla oblongata. In the brain gray substance close to these areas; advanced vasospasm (contraction), neuronal degeneration, necrosis, multifocal gliosis and focal hemorrhages were observed in the capillaries. It was found that the lumen narrowed as unselectable and the lumen structures were not selected in the capillaries contained in the gray matter and in other veins; and in partially healthy ones, there was a significant contraction. In neurons, in mildly degenerated neuron groups, while central chromatolysis and satellitosis were common, some neurons were found to shrink and take spindle shape and their cytoplasm was homogeneous and dark eosinophilic. In this group of rats' brain tissues, common findings were hematoma pressing on the meninx and brain gray matter in the region where the operation is performed and degenerative changes (**Figure 1**).

**Table 1.** Neurohistopathological findings and Basillar artery diameter measurement results of the group

	Group 1 (n=10)			Group 2 (n=10)			Group3 (n=10)			P*
	Median	Min	Max	Median	Min	Max	Median	Min	Max	
eNOS	15.50	11.00	21.00	17.00	8.00	23.00	20.00	16.00	24.00	0.000
Apopitosis	21.00	16.00	27.00	84.50	68.00	102.00	13.50	8.00	20.00	0.000
Vascular changes	0.00	0.00	1.00	3.00	2.00	3.00	1.00	1.00	2.00	0.000
Neuronal degeneration	0.00	0.00	1.00	3.00	2.00	3.00	1.00	1.00	2.00	0.000
Gliosis	0.00	0.00	0.00	2.50	1.00	3.00	1.00	1.00	2.00	0.000
Basillar artery diameter	87.00	76.85	92.38	74.37	65.34	80.29	83.40	74.78	89.38	0.000

\*p value shows the results of Kruskal Wallis Test

**Table 2.** Pairwise comparisons by Mann Whitney U Test with Bonferroni Adjustment

	Group 1-Group 2		Group 1-Group 3		Group 2-Group 3	
	z	padjusted*	z	padjusted*	z	padjusted*
eNOS	-3.565	0.000	-3.195	0.001	-1.878	0.060
Apopitosis	-3.784	0.000	-3.408	0.001	-3.782	0.000
Vascular changes	-3.963	0.000	-3.342	0.001	-3.527	0.000
Neuronal degeneration	-4.038	0.000	-3.827	0.000	-3.527	0.000
Gliosis	-4.091	0.000	-4.147	0.000	-3.022	0.003
Basillar artery diameter	-3.628	0.000	-3.780	0.000	-3.780	0.000

\*padjusted<0.0175 is considered as statistically significant

**Group 3 (SAH + PcTx1):** In this group of rat brains, unlike the histological changes described in the previous study group (Group 2), much milder meningeal hematoma, vasodilatation in vascular structures and adjacent degenerative changes in gray matter were recorded. However, the capillary lumens are open and the inside of them, smaller amounts of erythrocytes were present. Some medium-sized vessels have a normal lumen appearance and appearance of vascularisation were detected. In neurons, degenerative changes were moderate in the form of satellitosis, chromatolysis and cytoplasmic contraction in two cases, while in other cases mild chromatolysis was characterized (**Figure 1**).

### Immunohistochemistry Findings

In immunopathological examinations; eNOS immunoreactivities was observed in rat brains, especially in the capillaries contained in the gray substance of the brain root and in the medium-sized muscular vessels in the meninx. In general, immunoreactivities were selectively limited to endothelial cells, whereas in some cases eNOS showed homogeneous pattern in vascular lumens. Group 3 had the highest eNOS immunopositivity, followed by group 2 and then group 1.

For the purpose of detecting apoptosis in the brain; caspase-3 immunoreactivity (the effector enzyme of the external apoptosis pathway) were examined in the groups. There were no immunopositive reactions in the group 1, whereas apoptotic activity was generally low in group 3. Apoptotic cells were slightly higher in group 2 (**Figure 2**).

## DISCUSSION

Vasospasm is a complex pathophysiological process that can occur following subarachnoid hemorrhage (SAH), potentially leading to severe neuronal damage and neurological deficits. In this study, we investigated the role of PcTx1 venom in the treatment of vasospasm induced by experimental SAH in Wistar albino rats. Our objective was to determine whether PcTx1 venom administration could mitigate vasospasm and reduce neuronal damage, shedding light on potential therapeutic avenues for this challenging condition.

Clinical symptoms typically manifest around the 7<sup>th</sup> day, while radiological findings are usually identified around the 9<sup>th</sup> day on average. CT plays a crucial role in identifying ischemic areas and ruling out other potential causes, such as intracranial hematoma and hydrocephalus, particularly in patients experiencing clinical deterioration. Among a series of 135 cases studied following SAH, angiographic vasospasm was observed in 68% of cases, while 21% exhibited CT evidence of infarction.<sup>20</sup> Preliminary studies suggest that

positron emission tomography (PET), single photon emission CT (SPECT), and perfusion-weighted CT and MRI examinations may be beneficial for early diagnosis in the evaluation of vasospasm-induced hypoperfusion and ischemia.<sup>21</sup>

Preventing the development of vasospasm is crucial in patients who have undergone successful closure of aneurysmal subarachnoid hemorrhage (SAH) in order to minimize mortality and morbidity associated with this condition. In the SAH (control) group, we observed the most severe vascular spasm and degeneration-necrosis of gray matter neurons. These findings are consistent with the well-established notion that vasospasm can result in reduced cerebral blood flow, ischemia, and subsequent neuronal damage. The narrowing of cerebral vessels and associated hemodynamic changes play a pivotal role in the pathogenesis of SAH-induced neuronal injury.<sup>25</sup>

In contrast, in the SAH+PcTx1 group, we noted significantly less severe vascular narrowing and milder brain parenchyma and neuron reactions. This suggests a potential neuroprotective effect of PcTx1 venom in preventing vasospasm-induced neuronal damage. The mechanism underlying this protective effect may involve the venom's ability to induce vasodilation, thereby increasing perfusion to neuronal tissue. Previous studies have highlighted the vasodilatory properties of certain venom components, supporting our observations.<sup>26,27</sup>

Our analysis of endothelial nitric oxide synthase (eNOS) expression revealed interesting findings. eNOS is an enzyme responsible for the production of nitric oxide (NO), which is a potent vasodilator.<sup>28</sup> We observed that eNOS expression was higher in both the SAH (control) group and the SAH+PcTx1 group compared to the sham group. This suggests a compensatory response to the vascular changes induced by SAH, where the endothelium attempts to counteract vasospasm by increasing NO production. However, in the SAH+PcTx1 group, the increase in eNOS expression was more pronounced, possibly reflecting the venom's direct influence on endothelial function and NO release.

Origitano et al.<sup>22</sup> identified three H treatments consisting of hypertension, hypervolemia, and hemodilution. In the following years, this treatment was routinely applied after surgery in many centers where aneurysm surgery was performed, but the suggestion of phlebotomy for hemodilution mentioned in the original article was not widely adopted. Complications of this treatment, which is used to restore symptomatic vasospasm in addition to prophylaxis, include pulmonary edema, myocardial infarction, delusional hyponatremia due to fluid loading, cerebral edema, hemorrhagic cerebral infarction, and cardiac arrhythmias. Due to these complications,

which can be considered quite severe, there has been an increasing argument in recent years that this application should be reserved for vasospasm cases that require treatment rather than prophylaxis.

To take measures to prevent the development of vasospasm in the patient who has suffered aneurysmal subarachnoid hemorrhage and whose aneurysm has been successfully clipped surgically, especially during the most risky days for vasospasm, to monitor the patient very closely and to interfering with an energetic treatment is the first condition for reducing vasospasm-induced mortality and morbidity.

In a study conducted by Farabi et al.<sup>29</sup> it was observed that ASIC channels are abundantly expressed in various brain regions, including neuronal structures, and they can cause major changes in arteriolar diameter by affecting the microvascular wall structures. Therefore, it was suggested that the inhibition of ASIC1A channel could theoretically be effective in preventing vasospasm after subarachnoid hemorrhage. These findings support the idea that ASIC1A channel could be targeted to prevent vasospasm after subarachnoid hemorrhage. However, they also provide information about the potential effects of ASIC channels on cerebral circulation.

In the study conducted by Koehn et al.<sup>30</sup> it was shown that PcTx1, used as an ASIC1A inhibitor, had neuroprotective effects within the first 24 hours on mice with spinal cord injuries (both mechanical and hemorrhagic). Additionally, histological examinations performed at 24 hours and 6 weeks after the injury showed that the dorsolateral white matter of mice treated with PcTx1 was better preserved. These results indicate the potential use of PcTx1 as a therapeutic agent against spinal cord injuries.

Furthermore, we investigated apoptosis using caspase-3 immunoreactivity. In the sham group, no immunopositive reactions for apoptosis were observed, indicating the absence of apoptotic cell death in normal conditions. However, in the SAH (control) group, where vasospasm was severe, it is plausible that ischemia-induced cell death pathways, including apoptosis, were activated, contributing to neuronal damage.<sup>31</sup> Importantly, the SAH+PcTx1 group exhibited reduced neuronal apoptosis, suggesting a potential anti-apoptotic effect of PcTx1 venom.

The underlying mechanism by which psalmotoxin exerts its vasospasm-preventive effects is thought to involve its ability to modulate specific cellular pathways involved in vascular tone regulation. By targeting these pathways, psalmotoxin may effectively inhibit the constriction of cerebral blood vessels and subsequent development of vasospasm.<sup>32</sup> Moreover, the observed reduction in tissue damage suggests that psalmotoxin may also have neuroprotective properties, which could further

contribute to its therapeutic potential in preventing vasospasm-induced neuronal injury.

Our findings have significant clinical implications. Vasospasm remains a challenging and often devastating complication of SAH, with limited treatment options. The neuroprotective effects of PcTx1 venom demonstrated in this study warrant further investigation as a potential therapeutic intervention for vasospasm management. However, it is essential to acknowledge that translating these findings from an animal model to clinical practice will require extensive research and safety evaluations.

To fully establish the clinical utility of psalmotoxin in the treatment of vasospasm and its associated neuronal damage, additional experimental studies are required. These studies should focus on elucidating the optimal dosage, administration route, and treatment duration of psalmotoxin. Furthermore, investigations into potential adverse effects and drug interactions should be conducted to ensure the safety and tolerability of psalmotoxin in clinical settings.

### Limitations

We conducted experiments on a rat model, and the translation of these findings to human patients may differ due to species-specific variations. Additionally, the mechanisms underlying PcTx1 venom's effects on vasospasm and neuronal damage require further elucidation. Future research should focus on in-depth molecular and cellular investigations to understand the precise mechanisms involved.

### CONCLUSION

As a result of clinical and laboratory studies on the occurrence and formation mechanisms of vasospasm after subarachnoid hemorrhage, this pathological condition occurs as a result of many multifactorial and intercomposed biochemical reactions. In our study, it was observed that psalmotoxin effectively prevented vasospasm and significantly reduced tissue damage after vasospasm. Therefore, the efficacy of psalmotoxin in the treatment of vasospasm and neuronal damage improvement is needed to be investigated in other experimental studies. Additionally clinical trials are also needed to evaluate new treatment methods to prevent vasospasm and to help neurological recovery.

### ETHICAL DECLARATIONS

**Ethics Committee Approval:** This study was approved by the Kırıkkale University Animal Experiments Local Ethics Committee (Date: 02.02.2016, Decision No:16/01-16/18).

**Referee Evaluation Process:** Externally peer reviewed.

**Conflict of Interest Statement:** The authors have no conflicts of interest to declare.

**Financial Disclosure:** This article was supported by University as a Scientific research project. (Project no: 2016/112).

**Author Contributions:** All the authors declare that they have all participated in the design, execution, and analysis of the paper, and that they have approved the final version.

## REFERENCES

- Rinkel GJ, Djibuti M, Algra A, van Gijn J. Prevalence and risk of rupture of intracranial aneurysms: a systematic review. *Stroke*. 1998;29(1):251-256.
- Chalouhi N, Hoh BL, Hasan D. Review of cerebral aneurysm formation, growth, and rupture. *Stroke*. 2013;44(12):3613-3622.
- Etminan N, Rinkel GJ. Unruptured intracranial aneurysms: development, rupture and preventive management. *Nat Rev Neurol*. 2016;12(12):699-713.
- de Oliveira Manoel AL, Goffi A, Marotta TR, Schweizer TA, Abrahamson S, Macdonald RL. The critical care management of poor-grade subarachnoid haemorrhage. *Crit Care*. 2016;20:21.
- Mayberg MR, Batjer HH, Dacey R, et al. Guidelines for the management to aneurysmal subarachnoid hemorrhage. *Stroke*. 1994;25:2315-2328.
- Mocco J, Zacharia BE, Komotar RJ, Connolly ES Jr. A review of current and future medical therapies for cerebral vasospasm following aneurysmal subarachnoid hemorrhage. *Neurosurg Focus*. 2006;21(3):E9.
- Ingall T, Asplund K, Mahonen M, Bonita R. A multinational comparison of subarachnoid hemorrhage epidemiology in the WHO MONICA stroke study. *Stroke*. 2000;31:1054-1061.
- Behrouz R, Birnbaum LA, Jones PM, Topel CH, Misra V, Rabinstein AA. Focal neurological deficit at onset of aneurysmal subarachnoid hemorrhage: frequency and causes. *J Stroke Cerebrovasc Dis*. 2016; 25(11):2644-2647.
- Broderick JP, Brott TG, Duldner JE, Tomsick T, Leach A. Initial and recurrent bleeding are the major causes of death following subarachnoid hemorrhage. *Stroke*. 1994;25:1342-1347.
- Salary M, Quigley MR, Wilberger JE Jr. Relation among aneurysm size, amount of subarachnoid blood, and clinical outcome. *J Neurosurg*. 2007;107(1):13-7.
- Isaev NK, Stelmashook EV, Plotnikov EY, Khryapenkova TG, Lozier ER, Doludin YV. Role of acidosis, NMDA receptors, and acid-sensitive ion channel 1a (ASIC1a) in neuronal death induced by ischemia. *Biochem (Mosc)*. 2008;73(11):1171-1175.
- Xiong ZG, Chu XP, Simon RP. Acid sensing ion channels: novel therapeutic targets for ischemic brain injury. *Front Biosci*. 2007;12:1376-1386.
- Allen NJ, Attwell D. Modulation of ASIC channels in rat cerebellar Purkinje neurons by ischaemia-related signals. *J Physiol*. 2002;543(2):521-529.
- Krishtal O. The ASICs. signaling molecules? modulators? *Trends Neurosci*. 2003;26(9):477-83.
- Grunder S, Chen X. Structure, function, and pharmacology of acid-sensing ion channels (ASICs): focus on ASIC1a. *Int J Physiol Pathophysiol Pharmacol*. 2010;2(2):73-94.
- Papalampropoulou-Tsiridou M, Labrecque S, Godin AG, De Koninck Y, Wang F. Differential expression of acid - sensing ion channels in mouse primary afferents in native and injured conditions. *Front Cell Neurosci*. 2020;14:103.
- Wemmie JA, Price MP, Welsh MJ. Acid-sensing ion channels: advances, questions and therapeutic opportunities. *Trends Neurosci*. 2006;29(10):578-586.
- Escoubas P, De Weille JR, Lecoq A, et al. Isolation of a tarantula toxin specific for a class of proton-gated Na<sup>+</sup> channels. *J Biol Chem*. 2000;275(33):25116-25121.
- Xiong ZG, Zhu XM, Chu XP, Minami M, Hey J, Wei WL. Neuroprotection in ischemia: blocking calcium-permeable acid-sensing ion channels. *Cell*. 2004;118(6):687-698.
- Pignataro G, Simon RP, Xiong Z. Prolonged activation of ASIC1a and the time window for neuroprotection in cerebral ischemia. *Brain*. 2007;130(Pt 1):151-158.
- Li M, Inoue K, Branigan D, et al. Acid sensing ion channels in acidosis-induced injury of human brain neurons. *J Cereb Blood Flow Metab*. 2010;30(6):1247-1260.
- Origitano TC, Wascher TM, Reichman OH, Anderson DE. Sustained increased cerebral blood flow with prophylactic hypertensive hypervolemic hemodilution ("triple-H" therapy) after subarachnoid hemorrhage. *Neurosurgery*. 1990;27(5):729-739.
- Wemmie JA, Taugher RJ, Kreple CJ. Acid-sensing ion channels in pain and disease. *Nat Rev Neurosci*. 2013;14(7):461-471
- Annunziato L. Sodium calcium exchange: A growing spectrum of pathophysiological implications. *Advances in Experimental Medicine and Biology*. 2013:961.
- Muñoz-Guillén NM, León-López R, Túnez-Fiñana I, Cano-Sánchez A. From vasospasm to early brain injury: new frontiers in subarachnoid haemorrhage research. *Neurologia*. 2013;28(5):309-316.
- Kakumanu R, Hodgson WC, Ravi R, et al. Vampire venom: vasodilatory mechanisms of vampire bat (*Desmodus rotundus*) blood feeding. *Toxins (Basel)*. 2019;11(1):26.
- de Jesus-López E, Cuéllar-Balleza L, Díaz-Peña LF, Luna-Vázquez FJ, Ibarra-Alvarado C, García-Arredondo JA. Vasodilator activity of *Poecilotheria ornata* venom involves activation of the NO/cGMP pathway and inhibition of calcium influx to vascular smooth muscle cells. *Toxicol X*. 2023;19:100159.
- Konar SK, Ramesh S, Christopher R, et al. The correlation of endothelial nitric oxide synthase (eNOS) polymorphism and other risk factors with aneurysmal subarachnoid hemorrhage: a case-control study. *Neurol India*. 2019;67(4):1006-1012.
- Faraci FM, Taugher RJ, Lynch C, Fan R, Gupta S, Wemmie JA. Acid-sensing ion channels: novel mediators of cerebral vascular responses. *Circ Res*. 2019;125(10):907-920.
- Koehn LM, Noor NM, Dong Q, et al. Selective inhibition of ASIC1a confers functional and morphological neuroprotection following traumatic spinal cord injury. *F1000Res*. 2016;5:1822.
- Wang J, Wang JF, Hu XM. Caspase-3 in serum predicts outcome after aneurysmal subarachnoid hemorrhage. *Clin Chim Acta*. 2016;460:196-202.
- Garcia SM, Naik JS, Resta TC, Jernigan NL. Acid-sensing ion channel 1a activates IKCa/SKCa channels and contributes to endothelium-dependent dilation. *J Gen Physiol*. 2023;155(2):e202213173.