

Comparison of labral repair and biceps tenodesis concomitant with arthroscopic rotator cuff repair in patients between the age of 40 and 60

 Bertan Cengiz¹,  Sinan Oğuzkaya²

¹Acıbadem Hospital, Department of Orthopedics and Traumatology, Kayseri, Turkey

²Şarkışla State Hospital, Department of Orthopedics and Traumatology, Sivas, Turkey

Cite this article as: Cengiz B, Oğuzkaya S. Comparison of labral repair and biceps tenodesis concomitant with arthroscopic rotator cuff repair in patients between the age of 40 and 60. J Health Sci Med 2022; 5(2): 379-384.

ABSTRACT

Aim: Superior labrum anterior to posterior (SLAP) lesions are frequently accompanied by rotator cuff tear (RCT). The optimal treatment for type 2 and 4 SLAP lesions with RCT were not established. We aimed to compare the clinical results of SLAP repair and biceps tenodesis (BT) concomitant with arthroscopic rotator cuff repair (ARCR) in patients between 40 and 60 years old.

Material and Method: Forty three patients (16 male, 27 females) who received ARCR concomitant with SLAP repair or BT for full-thickness rotator cuff tear were evaluated retrospectively. The patients were divided into the two groups based on treatment methods (SLAP repair, Group 1, 20 patients), (BT, Group 2, 23 patients). American Shoulder and Elbow Surgeons (ASES) score, University of California Los Angeles (UCLA) shoulder score, visual analogue scale scores (VASs), and range of motion (ROM) values were used as outcome tools.

Results: The mean age of the patients was 48.8±5.03 years. There was no difference in preoperative shoulder and pain scores ($P<0.05$). Postoperative 12th month and last follow-up ASES and UCLA scores and ROM measures were significantly higher in Group 2, but the minimally clinical important difference (MCID) was not reached in any of the shoulder scores.

Conclusion: In the patients between 40 and 60 years old, BT is associated with higher shoulder scores and ROM values than SLAP repair when performed with RCR, but the difference was clinically insignificant. We concluded that both BT and SLAP repair is suitable options with concomitant RCR.

Keywords: SLAP repair, biceps tenodesis, middle age, rotator cuff repair

INTRODUCTION

Rotator cuff tear (RCT) is one of the most common cause of shoulder pain and disability in the adult population (1). Arthroscopic repair is the treatment of choice when conservative methods fail (2). The long head of the biceps tendon (LHBT) pathologies are frequently accompanied by RCTs (3). Biceps tenotomy provides earlier relief of pain with similar satisfaction rates with biceps tenodesis (BT) (4-6), however, it may cause bicipital tenderness, cramps, and loss of supination strength and deformity. Therefore tenotomy is mainly served for elderly patients (7-9). For more demanding younger patients with type 2 or 4 superior labrum anterior to posterior (SLAP) lesions, BT or SLAP repair is widely used (10).

SLAP repair preserves normal shoulder kinematics (11), but it is related to high rates of failure and stiffness (10);

therefore, the popularity of SLAP repair among shoulder surgeons decreased (12). BT is another reliable option for the management of concomitant LHBT pathologies with RCT. BT preserves normal tension of the LHBT with restoring biceps function, but complications such as anterior shoulder pain, failure, and relatively long rehabilitation period are major disadvantages of BT.

There is no consensus for the management of LHBT pathologies with RCT in the middle-aged population. Most of the recent studies favour tenotomy or BT for concomitant SLAP lesions with RCT (9, 13). However, Lim et al. compared (14) the outcomes of BT and SLAP repair with concomitant rotator cuff repair (RCR), and they reported similar functional results and complication rates. There is no guideline for the management of

concomitant superior labrum anterior to posterior (SLAP) lesions with RCT in middle age patients (10). Therefore, the purpose of the present study was to compare clinical and functional outcomes and complication rates of labral repair and biceps tenotomy concomitant with arthroscopic rotator cuff repair (ARCR) in patients between 40 and 60 years old.

MATERIAL AND METHOD

Patients, Inclusion and Exclusion Criteria

After obtaining Institutional Ethics Review Board approval (Date: 11.02.2021, Decision No: 2021-03/14), the prospectively collected data from single-center evaluated retrospectively. All procedures were carried out in accordance with the ethical rules and the principles of the Declaration of Helsinki. The patients who received ARCR with type 2 or 4 SLAP tears between January 2014 and January 2019 were included in the study. The inclusion criteria were (1) being between 40-60 years old at the time of surgery, (2) received transosseous equivalent ARCR because of full-thickness RCT, (3) symptomatic (+ O'Brien's test) type 2 or 4 SLAP lesion confirmed by magnetic resonance imaging (MRI) preoperatively and intraoperatively, (4) received SLAP repair or BT, (5) with minimum 24 months follow up period,

The exclusion criteria were (1) partially thickness RCT, (2) receiving tenotomy, (3) other labral lesions than type 2 or 4 SLAP, (4) Grade 3 or 4 fatty degeneration according to Goutallier classification (15), (5) isolated subscapularis tear, (6) acute traumatic rotator cuff tear or SLAP injury (7) history of previous shoulder surgery or fracture from the affected side, (8) osteoarthritis in the affected shoulder, (9) preoperative frozen shoulder, (10) history of intra-articular corticosteroid injection three months before surgery, (11) incomplete medical records or (12) lost to follow-up.

After inclusion and exclusion criteria were applied, a total of 43 patients were included. The patients who received labral repair were called Group 1 (n=20), and the patients who received BT were called Group 2 (n=23).

Demographic data including age, sex, etiology, body mass index (BMI) were obtained from the patient files. Tear size was classified according to DeOrio and Cofield classification (16) based on arthroscopic examination. The number of involved tendons and the type of SLAP lesions were recorded according to arthroscopic findings as well.

Surgical Technique

All patients were operated on by two surgeons. The first surgeon performed BT, and the second performed the labral repair. The operations were performed under general anesthesia combining with interscalane block in

the lateral decubitus position with longitudinal traction with 4 kilograms. A standard posterior portal was used to examine the glenohumeral joint, and then the anterior portal was established. The LHBT was examined with a probe, and the SLAP lesion was confirmed.

For the patients in Group 1, an anterosuperior portal was created, a cannula was placed, and the superior glenoid was prepared with a shaver. One or two Smith & Nephew (London, UK) TWINFIX® double-loaded suture anchor was inserted into the footprint, and the suture limbs were passed anterior and posterior to biceps anchor and tied respectively (**Figure 1**).

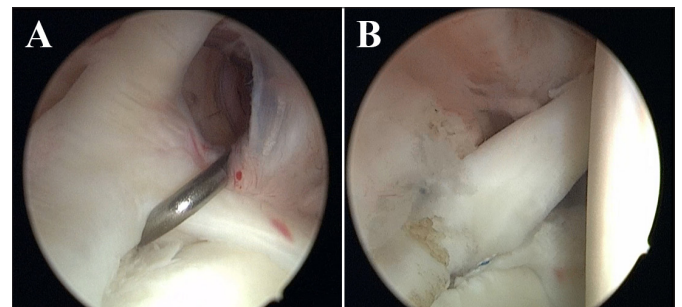


Figure 1 (a) Arthroscopic view of the SLAP 2 lesion from the posterior portal, (b) the view of LHBT-labrum complex after the repair was carried out.

For the patients in Group 2, free sutures were passed from the proximal portion of the LHBT, and the tendon was tenotomized just proximal to the sutures. Then, the sutures were loaded to the FOOTPRINT PK® suture anchor, and the anchor was inserted into the bicipital groove from the anterolateral portal without tension (**Figure 2**).

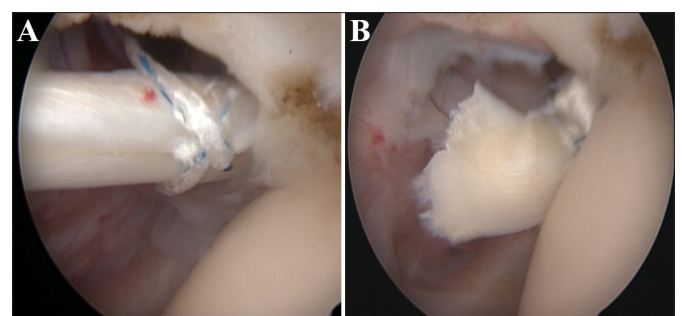


Figure 2. (a) Preparation of the LHBT for tenodesis, (b) Biceps tenodesis to the bicipital groove

Then, all rotator cuff repairs were performed using transosseous equivalent technique as previously described. (17). Subacromial decompression, bursectomy, and acromioplasty were performed before repair. The footprint was debrided and prepared with a shaver. According to the tear size, one or two Smith & Nephew (London, UK) TWINFIX® double-loaded suture anchor was inserted just lateral to the articular cartilage. A lateral FOOTPRINT PK® suture anchor was placed 1 cm lateral to the footprint to compress the rotator cuff.

Postoperative Rehabilitation

The shoulder was protected at the neutral position with a shoulder sling for four weeks. Passive mobilization and pendulum exercises were started immediately. After the first four weeks, progressive active mobilization was initiated. Strengthening exercises were contraindicated for postoperative three months. The rehabilitation program was supervised and guided by an experienced physiotherapist.

Outcome Assessment

The American Shoulder and Elbow Surgeons (ASES) score (18), University of California Los Angeles (UCLA) shoulder score (19), and Visual Analogue Scale (VAS) score were used for clinical and functional assessment. Shoulder range of motion (ROM) was measured by a universal goniometer. The complications and reoperations were recorded. Shoulder stiffness was also evaluated as described previously(20). Pseudoparalysis is defined as the restriction of active shoulder abduction to 90° without limitation in passive motions (18). All assessments were completed preoperative, at postoperative 12th month, and at the last follow-up. The complications and reoperations were recorded as well. The patients who had persistent pain and limitation of motion despite physiotherapy for three months were sent to MRI, and re-tears were recorded.

Statistical Analysis

The mean, median, minimum, maximum, and standard deviation (SD) values were used to describe data. Shapiro-Wilk normality test was used to analyse the distribution of data. Independent samples t- test and Mann Whitney U tests were used in the comparison of quantitative independent data. Pre- to postoperative changes were evaluated using paired samples t-test and Wilcoxon-signed rank test. Chi-square or test was used in the comparison of qualitative data. A P-value < 0.05 was considered statistically significant. All statistical analysis was performed using IBM SPSS for Windows, version 22 (IBM Corp., Armonk, NY).

RESULTS

The study included 43 patients. The mean age of the patients was 48.8±5.03 (Range 40-59). Patients were followed mean 51.09±16.37 months (Range 24-80). Demographic and intraoperative variables of the patients were presented in **Table 1**. There was a significant difference between preoperative and postoperative 12th month ASES and UCLA scores and all the ROM values in both groups (p<0.001) and also, ASES and UCLA scores at the last follow up were higher than the postoperative 12th-month scores in both groups (p<0.01). Comparison of preoperative and postoperative shoulder scores and

ROM measures between the two groups was presented in **Table 2**. In 5 patients, shoulder stiffness was observed during the follow-up period (Group 1 3/20, Group 2 2/23, p=0.520). Two patients in each group have pseudoparalysis (p=0.883). Symptomatic re-rupture was detected in the two patients in each group. One of them refused to receive another surgery in group 1, and the remaining three patients were received repair and tenotomy. There was no difference between the groups in terms of re-rupture rates (p=0.883). Three patients in each group reoperated during the follow-up period (p=0.853), etiologies were as follows, 1 re-rupture, 1 stiffness, and 1 anterior shoulder pain in group 1; 2 re-rupture and 1 anterior shoulder pain in group 2. Popeye deformity was observed in one patient from each group which was statistically not significant (Group1 5% vs. Group 2 4.34%, p=0.72).

Table 1. Demographic details and intraoperative findings of the patients

Variables	Group 1 (n=20) (Mean±SD) / n (%)	Group 2 (n=23) (Mean±SD) / n (%)	P Value
Age (Years)	48.6±6.05	49.13±4.07	0.678
Sex			0.780
Male	7 (35%)	9 (39.1%)	
Female	13 (56%)	16 (60.9%)	
Effected side			0.780
Dominant	13 (65%)	14 (60.9%)	
Nondominant	7 (35%)	9 (39.1%)	
Follow up (Months)	53.35± 15.43	49.13±17.24	0.386
BMI (kg/m2)	28.55±5.83	27.47±4.20	0.788
Etiology			0.919
Acute	1 (5%)	1 (4.3%)	
Chronic	19 (95%)	22 (95.7%)	
Tear Size			0.586
Small	7 (35%)	9 (39.1%)	
Medium	11 (55%)	11 (47.8%)	
Large	1 (5%)	3 (13.0%)	
Massive	1 (5%)	0 (0%)	
Number of involved tendons	1.55±0.68	1.30±0.55	0.191
SLAP lesion			0.756
Type 2	18 (90%)	20 (87%)	
Type 4	2 (10%)	3 (13%)	

DISCUSSION

The main finding of the study was, the patients who received ARCR with SLAP repair or BT benefit from surgery; however, the patients who received BT have higher ASES and UCLA shoulder scores postoperatively. On the other hand, internal and external rotation capacity were higher in patients who received BT at postoperative 12th month and the last follow-up. On the other hand, complication and reoperation rates were similar between the two groups.

Table 2. Comparison of clinical scores and ROM values between the two groups

Variables	Preoperative			Postoperative 12 th month			Last follow-up			P Value† (Pre-Postop 12 th month dif.)	P Value† (Postop 12 th month-Last FU dif.)
	Group 1 (n=20) (Mean±SD)	Group 2 (n=23) (Mean±SD)	p value*	Group 1 (n=20) (Mean±SD)	Group 2 (n=23) (Mean±SD)	p value*	Group 1 (n=20) (Mean±SD)	Group 2 (n=23) (Mean±SD)	p value*		
ASES score	40.40±5.64	42.78±4.70	0.093	83.30±5.66	87.39±2.58	0.015	87.20±5.66	89.56±1.90	0.020	<0.001	<0.001
UCLA shoulder score	18.00±2.15	16.69±2.28	0.065	26.80±1.19	29.13±1.79	<0.001	29.45±2.08	32.60±1.40	<0.001	<0.001	<0.001
VAS pain score	5.50 ±1.35	5.30 ±1.10	0.659	2.20 ±0.83	2.08 ±0.79	0.726	1.80 ±0.83	1.43 ±0.58	0.128	<0.001	0.004
FF (°)	142.75±6.75	137.17±9.63	0.080	162.25±4.99	165.21±6.11	0.054	169.00±3.83	172.82±3.93	0.03	<0.001	<0.001
ABD (°)	132.50±8.95	128.47±8.03	0.103	154.00±6.40	155.65±6.27	0.424	160.75±6.34	165.43±4.24	0.016	<0.001	<0.001
ER (°)	57.20±3.27	53.56±7.31	0.560	77.40±2.25	81.34±2.72	<0.001	83.20±1.85	87.21±2.06	<0.001	<0.001	<0.001
IR (°)	49.85±3.42	47.95±3.98	0.104	72.10±2.55	74.13±2.37	0.050	76.60±2.30	79.30±3.62	0.010	<0.001	<0.001

ASES: American Shoulder and Elbow Surgeons, UCLA: University of California Los Angeles, VAS: Visual Analogue Scale FF: Forward flexion, ABD: Abduction, ER: External rotation, IR: Internal rotation, *: Mann Whitney U test, †: Paired samples t-test, dif: Difference)

In their randomised controlled study, Franceschi et al. (9) compared to repair and biceps tenotomy in RCT with SLAP 2 lesion in patients over 50 years old, and they reported that the tenotomy group has a higher UCLA shoulder score. Also, Kim et al. (13) compared BT and labral repair concomitant with large to massive RCTs, and they reported that BT is associated with higher ASES and Simple Shoulder Test scores and ROM. Forsythe et al. (21) analysed the outcomes of the simultaneous rotator cuff and SLAP repair and compared them with isolated RCR, and they reported similar postoperative functional scores and ROM capacities, although the RCR+SLAP repair group had lower preoperative shoulder scores and ROM capacities than isolated RCR. In a recent study, Lim et al. compared SLAP repair and BT concomitant with RCR in patients over 45 years old, and they reported similar Constant, ASES, and VAS scores and ROM capacities in both groups. In contrast to Lim et al. (14), we found statistically significant difference in terms of ASES and UCLA shoulder scores and ROM measures at the postoperative 12th month and last follow-up. Although the inter-group differences were statistically significant, minimally clinical important difference (MCID) (22) was not detected neither in ASES nor UCLA shoulder scores. However, MCID values were reached in the both groups in terms of pre-postoperative differences.

Limitation of shoulder motion is a major concern after labral repair (23). Franceschi et al. (9) reported higher ROM in patients who received tenotomy and RCR compared to the simultaneous rotator cuff and SLAP repair. In another study (14), authors compared BT and SLAP repair concomitant with ARCR, and they reported similar ROM values. In their prospective study, Kanatli et al. (24) compared the clinical results of patients over the age of 45 who received repair for SLAP 2 lesion with or without RCR, and they reported similar overall UCLA scores and ROM values at an average 2.5 years follow-up. Based on their systematic review, the authors concluded that surgeons should be cautious about

repairing SLAP lesions, and they suggest performing BT or tenotomy concomitant with RCR. According to our findings, patients who received BT had higher internal and external rotation capacity at the postoperative 12th month and at the last follow-up, but those difference did not cause a clinically significant difference. The rate of postoperative stiffness was also similar between the two groups.

Popeye deformity may cause dissatisfaction apart from functional outcomes (25). Although Popeye deformity is mainly associated with biceps tenotomy, it may develop after BT as well (26). Oh et al. (5) reported similar Popeye sign rates between BT and biceps tenotomy with concomitant RCTs. We did not observe any Popeye sign in the BT group; however, one of the theoretical advantage of SLAP repair over BT may be preserving normal anatomy of the LGHT-labrum complex with a lower risk of Popeye sign which may be a concern in younger male patients.

The strengths of the study were as follows. In contrast to many similar studies (14, 24, 27), we analysed the narrow age group to increase the homogeneity of the study population and included the patients between 40-60 years old. We believe that the management of SLAP lesions in the older population should be analysed separately because healing capacity may be lower, and analysing middle age and geriatric population together may cause bias. We performed standardised transosseous equivalent double-row repair for all patients; therefore, confounding factors that may affect outcomes were minimum in this study, also baseline characteristics and preoperative measures were similar between the two groups.

The study has some limitations. First, the retrospective design of the study increases the risk of selection bias. We did not obtain MRI postoperatively from asymptomatic patients; therefore, we may miss some of the asymptomatic re-tears. Second, the study population

is relatively low. Third, two surgeons performed the operations, the surgical ability of the surgeons may influence the outcomes; however, both surgeons were trained in arthroscopic shoulder surgery. Also follow-up period was relatively short to observe long-term complications such as cuff tear arthropathy. Lastly, we did not measure the quality of life scores which may be more representative of the effect of disease on the general health status of the patients.

CONCLUSION

The patients who received biceps tenodesis and labral repair for SLAP 2 and 4 lesions concomitant with rotator cuff repair significantly improved clinical scores and shoulder ROM measures. We found that biceps tenodesis is associated with better ROM but similar clinical results with SLAP repair. Therefore, we concluded that both BT and SLAP repair is suitable options with concomitant RCR in middle-aged patients. New studies are needed to create evidence-based treatment algorithms for SLAP lesions with RCT.

ETHICAL DECLARATIONS

Ethics Committee Approval: The study was carried out with the permission of Acibadem University Ethics Committee (Date: 11.02.2021, Decision No: 2021-03/14).

Informed Consent: All patients signed the free and informed consent form.

Referee Evaluation Process: Externally peer-reviewed.

Conflict of Interest Statement: The authors have no conflicts of interest to declare.

Financial Disclosure: The authors declared that this study has received no financial support.

Author Contributions: All of the authors declare that they have all participated in the design, execution, and analysis of the paper, and that they have approved the final version.

REFERENCES

1. Minagawa H, Yamamoto N, Abe H, et al. Prevalence of symptomatic and asymptomatic rotator cuff tears in the general population: From mass-screening in one village. *J Orthop* 2013; 10: 8-12.
2. Plachel F, Siegert P, Rüttershoff K, et al. Long-term results of arthroscopic rotator cuff repair: a follow-up study comparing single-row versus double-row fixation techniques. *Am J Sports Med* 2020; 48: 1568-74.
3. Hawi N, Liodakis E, Garving C, Habermeyer P, Tauber M. Pulley lesions in rotator cuff tears: prevalence, etiology, and concomitant pathologies. *Arch Orthop Trauma Surg* 2017; 137: 1097-105.
4. De Carli A, Vadalà A, Zanzotto E, et al. Reparable rotator cuff tears with concomitant long-head biceps lesions: tenotomy or tenotomy/tenodesis? *Knee Surg Sports Traumatol Arthrosc* 2012; 20: 2553-8.
5. Oh JH, Lee YH, Kim SH, et al. Comparison of treatments for superior labrum-biceps complex lesions with concomitant rotator cuff repair: a prospective, randomized, comparative analysis of debridement, biceps tenotomy, and biceps tenodesis. *Arthroscopy* 2016; 32: 958-67.
6. Belay ES, Wittstein JR, Garrigues GE, et al. Biceps tenotomy has earlier pain relief compared to biceps tenodesis: a randomized prospective study. *Knee Surg Sports Traumatol Arthrosc* 2019; 27: 4032-37.
7. MacDonald P, Verhulst F, McRae S, et al. Biceps tenodesis versus tenotomy in the treatment of lesions of the long head of the biceps tendon in patients undergoing arthroscopic shoulder surgery: a prospective double-blinded randomized controlled trial. *Am J Sports Med* 2020; 48: 1439-49.
8. Godenèche A, Kempf JE, Nové-Josserand L, et al. Tenodesis renders better results than tenotomy in repairs of isolated supraspinatus tears with pathologic biceps. *J Shoulder Elbow Surg* 2018; 27: 1939-45.
9. Franceschi F, Longo UG, Ruzzini L, Rizzello G, Maffulli N, Denaro V. No advantages in repairing a type II superior labrum anterior and posterior (SLAP) lesion when associated with rotator cuff repair in patients over age 50: a randomized controlled trial. *Am J Sports Med* 2008; 36: 247-53.
10. Brockmeyer M, Tompkins M, Kohn DM, Lorbach O. SLAP lesions: a treatment algorithm. *Knee Surg Sports Traumatol Arthrosc* 2016; 24: 447-55.
11. Panossian VR, Mihata T, Tibone JE, Fitzpatrick MJ, McGarry MH, Lee TQ. Biomechanical analysis of isolated type II SLAP lesions and repair. *J Shoulder Elbow Surg* 2005; 14: 529-34.
12. Erickson BJ, Jain A, Abrams GD, et al. SLAP lesions: trends in treatment. *Arthroscopy* 2016; 32: 976-81.
13. Kim SJ, Lee IS, Kim SH, Woo CM, Chun YM. Arthroscopic repair of concomitant type II SLAP lesions in large to massive rotator cuff tears: comparison with biceps tenotomy. *Am J Sports Med* 2012; 40: 2786-93.
14. Lim S, Kim SK, Kim YS. Comparison between SLAP repair and biceps tenodesis with concomitant rotator cuff repair in patients older than 45 years: minimum 2-year clinical and imaging outcomes. *Clin Orthop Surg* 2020; 12: 364-370.
15. Gilbert F, Böhm D, Eden L, et al. Comparing the MRI-based Goutallier classification to an experimental quantitative MR spectroscopic fat measurement of the supraspinatus muscle. *BMC Musculoskelet Disord* 2016; 17: 355.
16. DeOrto JK, Cofield RH. Results of a second attempt at surgical repair of a failed initial rotator-cuff repair. *J Bone Joint Surg Am* 1984; 66: 563-7.
17. Park MC, Elattrache NS, Ahmad CS, Tibone JE. "Transosseous-equivalent" rotator cuff repair technique. *Arthroscopy* 2006; 22: 1360.e1-5.
18. Tokish JM, Alexander TC, Kissenberth MJ, Hawkins RJ. Pseudoparalysis: a systematic review of term definitions, treatment approaches, and outcomes of management techniques. *J Shoulder Elbow Surg* 2017; 26: 177-87.
19. Büyükodoğan K, Koyuncu Ö, Aslan L, Çelik D, Demirhan M. Translation, cross-cultural adaptation, reliability, and validity of Turkish version of the university of California Los Angeles (UCLA) shoulder scale into Turkish. *Disabil Rehabil* 2021: 1-8.
20. Armstrong A. Diagnosis and clinical assessment of a stiff shoulder. *Shoulder Elbow* 2015; 7: 128-34.
21. Forsythe B, Guss D, Anthony SG, Martin SD. Concomitant arthroscopic SLAP and rotator cuff repair. *J Bone Joint Surg Am* 2010; 92: 1362-9.
22. Malavolta E, Yamamoto G, Bussius G, et al. Establishing minimal clinically important difference for the UCLA and ASES scores after rotator cuff repair. *Orthop Traumatol Surg Res* 2021: 102894.

23. Civan O, Bilsel K, Kapicioglu M, Ozenci AM. Repair versus biceps tenodesis for the slap tears: A systematic review. *J Orthop Surg (Hong Kong)* 2021; 29: 23094990211004794.
24. Kanatli U, Ozturk BY, Bolukbasi S. Arthroscopic repair of type II superior labrum anterior posterior (SLAP) lesions in patients over the age of 45 years: a prospective study. *Arch Orthop Trauma Surg* 2011; 131: 1107-13.
25. van Deurzen DFP, Garssen FL, Wessel RN, Kerkhoffs GMMJ, van den Bekerom MPJ, van Wier MF. The Popeye sign: a doctor's and not a patient's problem. *J Shoulder Elbow Surg* 2021; 30: 969-76.
26. Lee HJ, Jeong JY, Kim CK, Kim YS. Surgical treatment of lesions of the long head of the biceps brachii tendon with rotator cuff tear: a prospective randomized clinical trial comparing the clinical results of tenotomy and tenodesis. *J Shoulder Elbow Surg* 2016; 25: 1107-14.
27. Erickson J, Lavery K, Monica J, Gatt C, Dhawan A. Surgical treatment of symptomatic superior labrum anterior-posterior tears in patients older than 40 years: a systematic review. *Am J Sports Med* 2015; 43: 1274-82.