



## RESEARCH

# Prevalence and distribution of sesamoid bones and accessory ossicles in the hand region in patients presenting to the emergency department: a radiographic study

Acil servise başvuran hastalarda el bölgesindeki sesamoid kemiklerin ve aksesuar kemikçiklerin prevalansı ve dağılımı: radyografik bir çalışma

Emre Atay<sup>1</sup>, Abdülkadir Bilir<sup>1</sup>, Ayşe Ertekin<sup>2</sup>, Tolga Ertekin<sup>1</sup>

<sup>1</sup>Afyonkarahisar Health Sciences University, Faculty of Medicine, Department of Anatomy, Afyonkarahisar, Türkiye

<sup>2</sup>Afyonkarahisar Health Sciences University, Faculty of Medicine, Department of Emergency Medicine, Afyonkarahisar, Türkiye

### Abstract

**Purpose:** This study aimed to retrospectively examine the accessory ossicles and sesamoid bones of the patients who applied to the emergency department with any hand and wrist complaints, on radiological images according to gender, frequency of incidence and extremity side.

**Materials and Methods:** This retrospective study was performed on radiological images (digital x-ray) of 500 patients (297 men, 203 women). Presence, prevalence, coexistence and distribution of accessory ossicles and sesamoids in the hand of patients without hand skeletal deformities were retrospectively analyzed.

**Results:** Accessory ossicles were detected in 8 (1.6%) of 500 cases. In our study, all of the accessory ossicles seen in the wrist and the hand region were ulnar styloid ossicles. Sesamoid bone was detected in 500 cases (100%) in metacarpophalangeal I (MCP I), in 192 cases (38.4%) in metacarpophalangeal II (MCP II), in 17 cases (3.4%) in metacarpophalangeal III (MCP III), in 2 cases (0.4%) in metacarpophalangeal IV (MCP IV), and in 34 cases (6.8%) in metacarpophalangeal V (MCP V).

**Conclusion:** This study will contribute to the literature in terms of Turkish population incidence by using digital x-ray images for hand sesamoid bones and accessory ossicles.

**Keywords:** Accessory ossicles, hand, incidence, radiography, sesamoid bones

### Öz

**Amaç:** Bu çalışmada acil servise herhangi bir el ve el bileği şikayeti ile başvuran hastaların radyolojik görüntülerinde aksesuar kemikçiklerin ve sesamoid kemiklerin cinsiyet, görülme sıklığı ve ekstremité tarafına göre retrospektif olarak incelenmesi amaçlanmıştır.

**Gereç ve Yöntem:** Bu retrospektif çalışma 500 hastanın (297 erkek, 203 kadın) radyolojik görüntüleri (dijital x-ray) üzerinde yapıldı. El iskelet deformitesi olmayan hastaların ellerinde aksesuar kemikçiklerin ve sesamoidlerin varlığı, prevalansı, birlikteliği ve dağılımı retrospektif olarak analiz edildi.

**Bulgular:** Aksesuar kemikçikler 500 olgunun 8'inde (%1.6) saptandı. Çalışmamızda el bileği ve el bölgesinde görülen aksesuar kemikçiklerin tamamı ulnar stiloid kemikçiklerdi. Sesamoid kemik 500 olguda (%100) metakarpofalangeal I (MCP I), 192 olguda (%38.4) metakarpofalangeal II (MCP II), 17 olguda (%3.4) metakarpofalangeal III (MCP III), 2 olguda (%0.4) metakarpofalangeal IV (MCP IV) ve 34 olguda (%6.8) metakarpofalangeal V'te (MCP V) tespit edildi.

**Sonuç:** Bu çalışma el sesamoid kemikleri ve aksesuar kemikçiklerin dijital röntgen görüntüleri kullanılarak Türk toplumunda görülme sıklığı açısından literatüre katkı sağlayacaktır.

**Anahtar kelimeler:** Aksesuar kemikçikler, el, insidans, radyografi, sesamoid kemikler

Address for Correspondence: Emre Atay, Department of Anatomy, Faculty of Medicine Afyonkarahisar Health Sciences University, Afyonkarahisar, Türkiye. E-mail: eemreatay@gmail.com

Received: 30.08.2023 Accepted: 15.11.2023

## INTRODUCTION

Galen introduced the term "sesamoid bone" to the literature, likening the small bones in the hands and feet to *Sesamum Indicum* seeds<sup>1,2</sup>. However, Pancoast and Ogden discovered that sesamoid bones have independent ossification centers and develop from there<sup>3,4</sup>. Sesamoid bones are small, round or oval-shaped bones with a diameter of a few millimetres. They arise from their own ossification centres and are located within tendons on the palmar and plantar joint surfaces, where tendons are in close proximity to bones and joints<sup>5-7</sup>. Cartilage nodules lead to the development of the majority of sesamoid bones in humans. Endochondral ossification occurs during early and late childhood, typically between the ages of 10 to 13 years in females and 11 to 14 years in males<sup>4,8</sup>.

The purpose of sesamoid bones in the body is yet to be fully understood. There are two main hypotheses in the literature about the function and development of the sesamoid bones. Some authors posit that sesamoid bones are remnants of evolution from regression during development, while others argue that they formed as a result of phylogenetic arrangements<sup>2,5,9-12</sup>. As a common belief, it is thought that sesamoid bones reduce friction, change the direction of muscle force, protect tendons, and thus function as a part of the sliding mechanism during movement<sup>6,13</sup>. In a study conducted by Yamine in 2018, a new hypothesis was proposed regarding the sesamoid bones in the fingers. The sesamoid frequency of the fingers was calculated with a simple three-variable equation. According to the data obtained, it was concluded that the more mobile the finger, the more sesamoids it carries. It has been found that this logic also applies to the toe sesamoids of the human foot. It was suggested that the hyperextension hypothesis could account for the frequency and distribution of sesamoids in human fingers. The hypothesis proposes that these tiny bones develop due to mechanical stress on the joint over time<sup>14</sup>.

When the presence of sesamoid bone in the hand is evaluated in a clinical context, it can be associated with several pathological conditions. While pathological conditions related to trauma and degenerative disorders are more common in the literature<sup>1,15,16</sup>, tumors and avascular necrosis of the sesamoid bones are less common pathological<sup>17,18</sup>.

According to the information supported by the literature, there are various clinical pictures related to the sesamoid bones of the hand. In this respect, our study was designed to determine the frequency and distribution of hand sesamoid bones, which exhibit significant distribution differences between populations, according to gender in a specific sample and to provide data that will contribute to the evaluation of clinical pictures. In addition to all these, determining the characteristics of sesamoid bones in the hand, performing prevalence studies and revealing pathological conditions are of great importance in terms of contributing to both the literature and the clinic. In this study, we aimed to retrospectively examine the accessory ossicles and sesamoid bones of the patients who applied to the emergency department with any hand and wrist complaints, on radiological images according to gender, frequency of incidence, and extremity side.

## MATERIALS AND METHODS

### Sample

This retrospective study was conducted on radiological images (digital radiographs) of 500 patients (297 males and 203 females) who applied to Afyonkarahisar Health Science University Health Application and Research Center Department of Emergency with hand and wrist complaints between January 2018 and December 2021, to determine the incidence of accessory ossicles and sesamoids.

Patients with the following exclusion criteria were not included in the study. Those with abnormal bone structure (tumor, cyst, bleeding, osteolysis, severe arthritis, fracture and calcification, etc.), those with impaired bone structure due to trauma or degenerative disorder, those with unclear radiological images (digital x-ray), and those who underwent amputation were not included in the study. Within the scope of the study, x-ray images of 750 patients were analyzed. Considering the exclusion criteria stated above, x-ray images of 500 patients were evaluated within the scope of the study. The presence, prevalence, coexistence, and distribution of accessory ossicles and sesamoid bones in the hands of patients who did not have any deformities in the hand skeleton were retrospectively analyzed. An experienced radiology specialist assisted in all stages of the evaluation of digital x-ray images. At the same time, the data obtained by considering the previous

literature [17–20] information were recorded for statistical analyses.

### Procedure

This study was performed in line with the principles of the Declaration of Helsinki. Ethics committee approval obtained from Afyonkarahisar Health Science University Clinical Research Ethics Committee dated April 30, 2021 and numbered 2021/311.

Digital x-rays of the hands were analyzed using Afyonkarahisar Health Science University Health Application and Research Center the Picture Archiving and Communication System (PACS, InterPACS DICOM Viewer Software, Turkey).

Posteroanterior (PA), oblique, and lateral radiographs (digital x-ray) of 500 patients whose film focus distance was determined as to be 100-110 cm were evaluated. Hand and wrist radiological images were evaluated by at least three independents experienced (EA; Anatomist, AB; Anatomist, TE; Anatomist, AE; Emergency Medicine Specialist) observers. An experienced radiologist was consulted about the radiological images that needed to be re-evaluated. The final decision was made unanimously as a result of the evaluation made with at least three observers in the disagreements and controversial conditions.

### Statistical analysis

Statistical analysis of the data was done with the SPSS 25 package program (SPSS, Chicago, Illinois). G-power 3.1.9.4 software program (Heinrich Heine Universität Düsseldorf, Düsseldorf, Germany) was used in the power analysis to determine the sample size of this study. By setting the type 1 error level to be 5%, the power to be 95%, and the effect size to be 0.2043, the sufficient sample size was determined to be minimum 500 people.

Accessory ossicles and sesamoid bones existence (present/absent) according to gender, extremity side, and age groups were analyzed with the Pearson chi-square test. Categorical data were expressed as frequency and percentage. The results were evaluated within the 95% confidence interval, and the data with  $p < 0.05$  were considered statistically significant.

### RESULTS

In our study, hand radiography images of a total of

500 cases, 267 of which were right and 233 were left, were evaluated. While 297 of the cases were male, 203 were female. Accessory ossicles were detected in 8 (1.6%) of 500 cases. In our study, all of the accessory ossicles seen in the wrist and hand regions were ulnar styloid ossicles (Table 1, Figure 1).

Sesamoid bones were present in all 500 cases. The distribution of the detected sesamoid bones was as follows: Sesamoid bone was detected in 500 cases (100%) in metacarpophalangeal I (MCP I), in 192 cases (38.4%) in metacarpophalangeal II (MCP II), in 17 cases (3.4%) in metacarpophalangeal III (MCP III), in 2 cases (0.4%) in metacarpophalangeal IV (MCP IV), and in 34 cases (6.8%) in metacarpophalangeal V (MCP V). Except for MCP I, all sesamoid bones were in one piece. In MCP I, 16 (3.2%) of 500 cases had bipartite sesamoid bones. In addition, while sesamoid bone was seen in the first proximal interphalangeal (IP) joints in 64 (12.8%) cases, no sesamoid bone was observed in the proximal and distal IP joints of the second, third, fourth, and fifth fingers in any of the radiographs (Table 1, Figure 1).

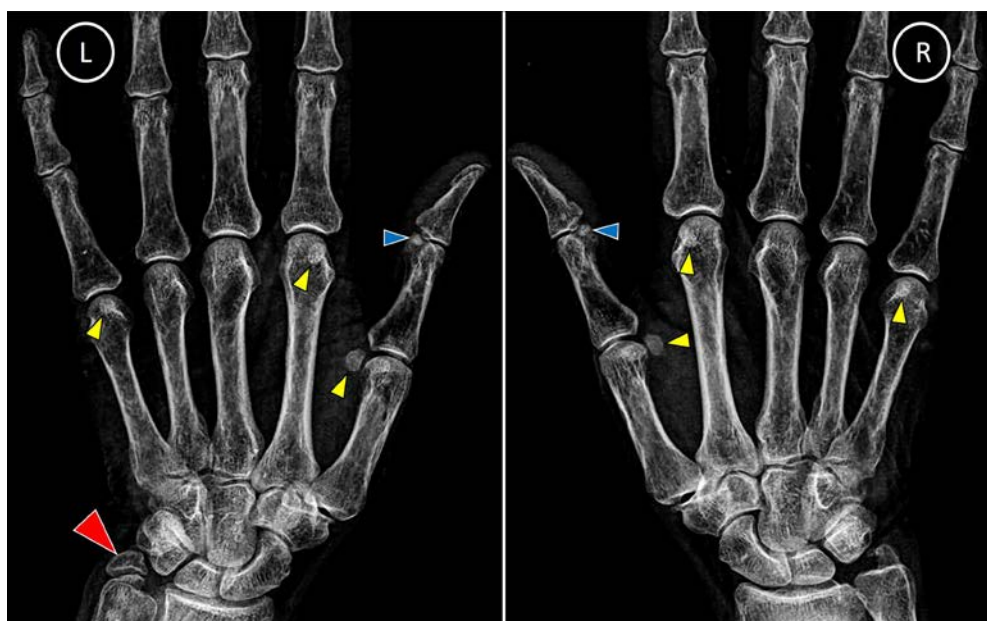
Differences between the presence of accessory ossicles and sesamoid bones according to extremity side, gender, and age groups were analyzed statistically. According to the extremity side (right and left), there was no significant difference in the incidence of accessory ossicles and sesamoid bones between the joints except for MCP II. In MCP II, the incidence of sesamoid bones was statistically significantly higher in the right extremity ( $p < 0.001$ ).

While the prevalence of accessory ossicles and sesamoid bones in male and female cases was generally similar according to gender, sesamoid bones in MCP II, MCP IV, and the first IP joints were statistically more common in women than in men ( $p < 0.001$ ). When the incidence of accessory ossicles and sesamoid bones is evaluated according to age groups, in the 41-50 age group, MCP II, MCP V in the sesamoid bones, and ulnar styloid ossicles, it was found that the presence of sesamoid bones in MCP III and the first IP joint sesamoid bones in the 61-70 age group was statistically significantly higher than in other age groups ( $p < 0.001$ ). There was no statistical difference between age groups in the presence of sesamoid bone in MCP IV ( $p = 0.207$ ). The distribution of sesamoid bones and accessory ossicles of the hand region according to the evaluation parameters were detailed in Table 1.

**Table 1. Distribution of Accessory Ossicles and Sesamoid Bones by gender, extremity side and age groups**

Accessory Ossicles and Sesamoid Bones	All Cases n=500 100%	Gender			Extremity Side			Age Groups							
		Male n=297 (59.4%)	Female n=203 (40.6%)	p	Right	Left	p	11-20 n=125 (25%)	21-30 n=94 (18.8%)	31-40 n=64 (12.8%)	41-50 n=71 (14.2%)	51-60 n=70 (14%)	61-70 n=46 (9.2%)	71-80 n=28 (5.6%)	p
MCP I	500 100%	297 59.4%	203 40.6%	-	267 53.4	233 46.6	-	125 25%	94 18.8%	64 12.8%	71 14.2%	70 14%	46 9.2%	28 5.6%	-
MCP II	192 100%	92 47.9%	<b>100</b> <b>52.1%</b>	<b>&lt;0.001</b>	<b>122</b> <b>63.5%</b>	70 36.5	<b>&lt;0.001</b>	10 5.2	41 21.4%	20 10.4	<b>42</b> <b>21.9%</b>	40 20.8%	22 11.5%	178.9 5.6%	<b>&lt;0.001</b>
MCP III	17 100%	8 47%	9 53%	0.29	7 41.2%	10 58.8	0.30	-	6 35.3%	-	1 5.9%	2 11.8%	8 47.1%	-	<b>&lt;0.001</b>
MCP IV	2 100%	1 50%	1 50%	0.78	1 50%	1 50	0.92	-	2 100%	-	-	-	-	-	0.207
MCP V	265 100%	123 46.4%	<b>142</b> <b>53.6%</b>	<b>&lt;0.001</b>	150 56.6%	115 43.4	0.15	18 6.8%	44 16.6%	37 14%	<b>65</b> <b>24.5%</b>	52 19.6%	27 10.2%	22 8.3%	<b>&lt;0.001</b>
IP I	64 100%	23 35.9%	<b>41</b> <b>64.1%</b>	<b>&lt;0.001</b>	27 42.2%	37 57.8	0.54	3 4.7%	22 34.4%	7 10.9%	8 12.5%	7 10.9%	<b>13</b> <b>20.3%</b>	4 6.3%	<b>&lt;0.001</b>
Ulnar styloid	8 100%	2 25%	<b>6</b> <b>75%</b>	<b>0.04</b>	<b>6</b> <b>75%</b>	2 25	0.29	-	-	-	5 62.5%	1 12.5%	2 25%	-	<b>0.002</b>

The Pearson chi-square test was used for comparison between groups. Data with statistically significant differences were expressed in bold and italics. Categorical data were expressed as frequency and percentage; MCP I: metacarpophalangeal I; MCP II: metacarpophalangeal II; MCP III: metacarpophalangeal III; MCP IV: metacarpophalangeal IV; MCP V: metacarpophalangeal V; IP I: interphalangeal joint I.



**Figure 1. Sesamoid bones seen on posteroanterior (PA) digital x-ray of right and left hand. Yellow arrowhead indicates sesamoid bones seen at metacarpophalangeal (MCP) joints. Blue arrowhead indicates sesamoid bones seen at interphalangeal (IP) joints. Red arrowhead indicates the ulnar styloid accessory ossicle at the wrist.**

## DISCUSSION

There are many sesamoid bones in the human body, which provide additional strength to the muscles and stability to the tendons. It has been reported in the literature that there are up to 42 sesamoid bones in the human body. Sesamoid bones, which have important functions in the human body in terms of protection against strain and injury, are often found in the hand<sup>1,19-21</sup>.

Gender, location and ethnicity are thought to be effective factors in the distribution of sesamoid bones<sup>22</sup>. However, there are typically five sesamoid bones in each hand: two at the MCP joint of the thumb, one at the IP joint of the thumb, one at the MCP joint of the index finger on the radial side, and one at the MCP joint of the little finger on the ulnar side<sup>1,2</sup>. Many studies in the literature have reported that an adult individual has a sesamoid bone in the MCP joint and it is accepted as a normal part of the skeleton. It has also been noted that the sesamoids of the other fingers are rarely seen and may vary<sup>2,5,20-24</sup>.

It is observed in the literature that the frequency of sesamoid bone reported in the IP joint of the thumb varies between 21.3% and 100%<sup>2,8,19,25</sup>. In studies conducted in the Turkish population, it was determined that two different results were varying at the rate of 21.3% and 21.8%<sup>19,24</sup>. However, in studies conducted in Bahrain, Oman, African, and Caucasian populations, the frequency of sesamoid bone in the IP joint of the thumb was 28.6%, 49.7%, 100%, and 73-100%, respectively<sup>2,8,20,25</sup>. In our study, the presence of sesamoid bone was detected in the IP joint of the thumb in 64 (12.8%) of 500 cases. It is thought that factors such as the size of the study population, the region where the study was conducted, and the difference in the population caused the lower rate in our study compared to the literature.

There is literature information showing the presence of sesamoid bone in the MCP joint<sup>1,2,14</sup>. However, there is much research showing that MCP I has the most sesamoid bone presence in the hand skeleton, including different ethnicities and populations<sup>18,20,23,24</sup>. As a striking result in our study, the presence of sesamoid bone in MCP I was detected in all 500 cases (100%). At the same time, it was determined that 267 of the sesamoid bones were on the right side and 233 on the left side extremity.

In our study, the presence of sesamoid bone was also detected in other MCP joints. The presence of sesamoid bone in MCP II and V joints was greater than the others. However, when the presence of sesamoid bone in both joints was compared according to gender, it was determined that the presence of sesamoid bone was significantly more common in females than in male (Table 1,  $p < 0.001$ ). In the literature review, it is seen that there is no difference in most of the studies investigating the presence of sesamoid bone according to gender<sup>8,20,22</sup>. However, the opposite results were obtained in our study. In addition, it has been determined that there are studies with results similar to the findings of our study. According to the study of Civan et al., it was reported that the presence of sesamoid bone in MCP II and V joints was statistically significantly higher in females<sup>24</sup>. In the study of Lam et al., it was determined that the presence of sesamoid bones in the MCP joints was statistically significantly higher in females, although it was more common in the IP joint of the thumb<sup>18</sup>.

In our study, we also looked at the existence of accessory ossicles in addition to sesamoid bone. Identification of accessory ossicles in the hand region requires extreme caution because it is very difficult to distinguish between ulnar styloid process fractures and accessory ossicles. In addition, it's important to distinguish accessory ossicles because diverse ossifications and calcifications are also located in this area. The existence of clearly defined and regular contours is one of the key features in the differentiation of accessory ossicles. These contours have an erratic structure in fractures<sup>17,26,27</sup>. In our study, the presence of accessory ossicles was investigated, considering this information. As a result of the evaluation made in all cases, ulnar styloid accessory ossicles were detected in 8 cases (1.6%). Of these accessory ossicles, 2 were male and 6 were female. In a recent study by Gürsoy et al., 1146 cases were examined, and a total of 113 accessory ossicles were discovered. 17 of these accessory ossicles (1.48%) were ulnar styloid accessory ossicles, it was discovered<sup>17</sup>. In addition, Aydınlioğlu et al. examined 388 plain radiographs and found the incidence of ulnar styloid accessory ossicles to be 2.5%<sup>27</sup>. In the comparison, it is seen that our results are compatible with the literature. Since the results of our study belong to the Turkish population, we believe that it will contribute significantly to other studies to determine whether there is a difference between ethnic groups in terms of wrist accessory ossicles.

The difference in the prevalence of sesamoid bones according to gender and age factors in our study may be related to genetic and social differences and the differences in the use of hands and fingers. However, the occasional symptoms of sesamoid bones, which are clinically mostly harmless, should be considered to be associated with the development of an anatomical, biomechanical and clinical pathological condition. In this context, we believe that knowing the detailed anatomy of sesamoid bones, including their number and distribution characteristics, will increase the rate of early diagnosis and correct diagnosis of hand diseases related to these bones in clinical and radiological examinations. At the same time, we think that the results of the study will guide clinicians in preventing unnecessary treatment interventions by contributing to a better understanding and more accurate evaluation of accessory bones.

This study had several limitations. The main limitation of our study is its retrospective design. In addition, unilateral standard digital radiographs were used. As the radiographs used in the study were unilateral, the incidence of bilateral sesamoids and accessory ossicles could not be discussed. Another limitation of the study is that the digital radiographs were obtained from patients who presented to the emergency department with a variety of related symptoms. The strengths of our study are that it has a large sample size and provides information on the incidence of many sesamoids in the literature.

In conclusion, this study will contribute to the literature in terms of its incidence in the Turkish population using digital x-ray images of the sesamoid bones and accessory ossicles of the hand. According to our results, the incidence of MCP I and V sesamoid bones is higher than that reported in previous studies in the literature. The results of this study have shown that the ulnar styloid accessory sesamoids in the wrist are increased in individuals over the age of 40 years. We believe that this study is important in providing clinicians with anatomical data that may guide diagnosis and treatment.

**Author Contributions:** Concept/Design : EA, AE; Data acquisition: AE, AB; Data analysis and interpretation: EA, TE; Drafting manuscript: EA, AE, AB, TE; Critical revision of manuscript: EA, TE; Final approval and accountability: EA, AB, AE, TE; Technical or material support: AE; Supervision: EA, TE; Securing funding (if available): n/a.

**Ethical Approval:** This study was performed in line with the principles of the Declaration of Helsinki. Ethics committee approval obtained from Afyonkarahisar Health Science University Clinical Research Ethics Committee dated April 30, 2021 and numbered 2021/311.

**Peer-review:** Externally peer-reviewed.

**Conflict of Interest:** The authors declare that no conflicts of interest are associated with this study.

**Financial Disclosure:** Authors declared no financial support

**Data Availability Statement:** The data that support the findings of this study are available from the corresponding author upon reasonable request.

## REFERENCES

1. Wood VE. The sesamoid bones of the hand and their pathology. *J Hand Surg Br.* 1984;9:261-4.
2. Yammine K. The prevalence of the sesamoid bones of the hand: a systematic review and meta-analysis. *Clin Anat.* 2014;27:1291-303.
3. Pancoast H. Radiographic statistics of the sesamoid in the tendon of the gastrocnemius. *Univ Pa Med Bull.* 1909;22:213-7.
4. Ogden JA. Radiology of postnatal skeletal development. *Skeletal Radiol.* 1984;11:246-57.
5. Bizarro AH. On sesamoid and supernumerary bones of the limbs. *J Anat.* 1921;55:256-68.
6. Goldberg I, Nathan H. Anatomy and pathology of the sesamoid bones. *Int Orthop.* 1987;11:141-7.
7. Amar E, Rozenblat Y, Chechik O. Sesamoid and accessory bones of the hand—An epidemiologic survey in a Mediterranean population. *Clin Anat.* 2011;24:183-7.
8. Dharap AS, Al-Hashimi H, Kassab S, Abu-Hijleh MF. Incidence and ossification of sesamoid bones in the hands and feet: a radiographic study in an Arab population. *Clin Anat.* 2007;20:416-23.
9. Seybold EA, Warhold LG. Impingement of the flexor pollicis longus tendon by an enlarged radial sesamoid causing trigger thumb: a case report. *J Hand Surg Am.* 1996;21:619-20.
10. Abdel-Kader HM. The potential of digital dental radiography in recording the adductor sesamoid and the mp3 stages. *Br J Orthod.* 1999;26:291-4.
11. Sokolowska-Pituchowa J, Miałkiewicz C. Studies on the sesamoid bones of the hands in women. *Folia Morphol.* 1967;26:25-32.
12. Sokolowska-Pituchowa J, Miałkiewicz C. Studies on the sesamoid bones in the hands of men. *Folia Morphol.* 1965;24:141-7.
13. Butt IS, Kim WY. Complex dorsal subluxation of the metacarpo-phalangeal joint of the thumb requiring open reduction: a case report. *Acta Orthop Belg.* 2006;72:93-5.
14. Yammine K. The relationship between digit independence and digital sesamoids in humans and a proposal of a new digital sesamoid evolutionary hypothesis. *Anat Rec.* 2018;301:1046-60.
15. Mohler LR, Trumble TE. Disorders of the thumb sesamoids. *Hand Clin.* 2001;17:291-01.
16. Ozcanli H, Sekerci R, Keles N. Sesamoid disorders of the hand. *J Hand Surg Am.* 2015;40:1231-2.

17. Gursoy M, Coban I, Mete BD, Bulut T. The incidence of accessory ossicles of the wrist: a radiographic study. *J Wrist Surg.* 2021;10:458-64.
18. Ting LGY, San CEC, Ben N, Gerry HCH, Wai CC. Distribution of sesamoid bones in the hand—a study in the Chinese population. *Journal of Orthopaedics, Trauma and Rehabilitation.* 2017;23:45-8.
19. Kose O, Guler F, Turan A, Canbora K, Akalin S. Prevalence and distribution of sesamoid bones of the hand: a radiographic study in Turkish subjects. *Int J Morphol.* 2012;30:1094-9.
20. Al Khabori H, Al Asmi M, Sirasanagandla SR, Rashdi FA, Dhuhli HA, Jaju S et al. Prevalence and distribution of sesamoid bones of the hand in Omani subjects: a radiological study. *Anat Sci Int.* 2021;96:79-86.
21. Chen W, Cheng J, Sun R, Zhang Z, Zhu Y, Ipaktchi K et al. Prevalence and variation of sesamoid bones in the hand: a multi-center radiographic study. *Int J Clin Exp Med.* 2015;8:11721-6.
22. Ergen E, Yılmaz Ö, Arı B, Nacar E, Çimen AÖ, Ertem K et al. Prevalence of metacarpophalangeal sesamoid bones of the hand in Turkish population. *Jt Dis Relat Surg.* 2021;32:391-6.
23. Dąbrowski K, Stankiewicz-Jóźwicka H, Kowalczyk A, Markuszewski M, Ciszek B. Ossa sesamoidea - prevalence of sesamoid bones in human hands. *Folia Morphol.* 2020;79:570-5.
24. Civan O, Şekerci R, Erciği N, Özer Ş, Güvenç İ, Çevik NK et al. Sesamoid bones of the hand: a multicenter study. *Jt Dis Relat Surg.* 2020;31:68-72.
25. Msamati BC, Igbigbi PS. Radiographic appearance of sesamoid bones in the hands and feet of Malawian subjects. *Clin Anat.* 2001;14:248-53.
26. Bogart F. Variations of the bones of the wrist. *Am J Roentgenol.* 1932;28:638-46.
27. Aydınlioğlu A, Rağbetli MÇ, Akpınar F, Tosun N, Doğan A. The accessory ulnar styloid process. *Ulus Travma Acil Cerrahi Derg.* 1998;4:53-7.