




# Aydın Dental Journal

Journal homepage: <http://dergipark.ulakbim.gov.tr/adj>



## RAPID MAXILLARY EXPANSION IN MIXED DENTITION PATIENT WITH MAXILLARY INSUFFICIENT CORRECTION SUBSEQUENTED BY A CORRECTIVE ORTHODONTIC TREATMENT: CASE REPORT

DergiPark  
AKADEMİK

Jamil BAYZED\*<sup>1</sup>, Saadet ÇINARSOY CİĞERİM<sup>2</sup>, Yousef M. K. SAED<sup>3</sup>, Hüseyin Melik BÖYÜK<sup>4</sup>

### ABSTRACT

This case report describes the treatment of a 12-years-old child with an Angle Class II subdivision malocclusion in addition to transverse maxillary insufficiency and unilateral maxillary crossbite and the use of Rapid Maxillary Expansion (RME) followed by a fixed appliance to address it. The treatment objective was to address the posterior and anterior crossbite and restore dentition and occlusion. This case was successfully treated with a single lingual sheath hyrax screw bonded expansion in Phase I, it resolved clinically substantial palatal expansion and improved the maxillary arch width, allowing for fixed appliance therapy in Phase II to be applied.

**Keywords:** *Crossbite, rapid maxillary expansion, class 3.*

<sup>1</sup> DDS, PhD, Department of Orthodontics, Faculty of Dentistry, Van Yuzuncu Yil University, Van, Turkey. E-mail: [drjamilmaher@gmail.com](mailto:drjamilmaher@gmail.com), Orcid: 0000-0003-2102-2017

<sup>2</sup> DDS, MSc, Department of Orthodontics, Faculty of Dentistry, Van Yuzuncu Yil University, Van, Turkey. E-mail: [saadetcinarsoy@live.com](mailto:saadetcinarsoy@live.com), Orcid: 0000-0002-4384-0929

<sup>3</sup> DDS, PhD, Department of Endodontics, Faculty of Dentistry, Van Yuzuncu Yil University, Van, Turkey. E-mail: [yousufsaed@hotmail.com](mailto:yousufsaed@hotmail.com), Orcid: 0000-0001-8361-4734

<sup>4</sup> DDS, PhD, Department of Orthodontics, Faculty of Dentistry, Van Yuzuncu Yil University, Van, Turkey. E-mail: [gshmb003@gmail.com](mailto:gshmb003@gmail.com), Orcid: 0000-0002-5846-317

Makale Geliş Tarihi: 19.01.2022 - Makale Kabul Tarihi: 12.02.2022

Doi: 10.17932/IAU.DENTAL.2015.009/dental\_v08i1007

## **MAKSİLLER YETERSİZLİĞİ OLAN KARIŞIK DIŞLENME DÖNEMİNDEKİ HASTADA HIZLI MAKSİLLER GENİŞLETME VE SONRASINDA SABİT ORTODONTİK TEDAVİ: OLGU SUNUMU**

### **ÖZ**

Bu vaka raporu, transversal maksiller yetersizlik ve tek taraflı maksiller çapraz kapanışla beraber Angle Class II subdivision maloklüzyonu olan 12 yaşındaki bir çocuk hastanın tedavisi için Hızlı Maksiller Genişleme (RME) ve ardından sabit ortodontik tedavi uygulamasını anlatmaktadır. Tedavinin amacı anterior ve posterior çapraz kapanışı değerlendirmek ve diş yapısı ile oklüzyonu düzeltmektir. Bu vaka, Faz I'de lingual sheath hyrax vidalı ekspansiyon ile başarılı bir şekilde tedavi edildi, klinik olarak maksiller genişletme yapılarak Faz II'de sabit ortodontik tedavi uygulandı.

**Anahtar Kelimeler:** *Çapraz kapanış, hızlı maksiller genişletme, sınıf 3.*

### **INTRODUCTION**

Early treatment techniques for maxillary transverse deficiency were used in orthodontics. The method was discredited in the 1860s, but it is now widely accepted as a predictable and straightforward orthodontic procedure. Rapid maxillary expansion (RME), slow maxillary

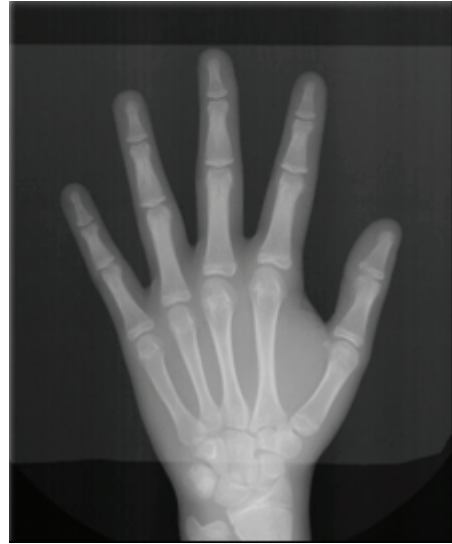expansion (SME), and surgically maxillary expansions are the most common therapeutic techniques utilized to achieve maxillary expansion.<sup>1,2</sup> The first description of (RME) was by Emerson Angell in 1860, and has repopularized it subsequently.<sup>3</sup> RME's primary goal is to widen the transverse deficiency of the maxillary arch, although its effects extend beyond the maxilla because it is joined to ten bones in the face and head. This treatment can be used to rectify transverse and sagittal crossbite, as well as to generate space in the upper jaw and, as a result, to solve situations of crowding.<sup>4</sup> The RME is highly beneficial in treating Class III cases, along with those of approximate maxillary deficits.<sup>5</sup> As a result of the therapeutic effects that are not confined to the correction of a crossbite or the expansion in arch width, occlusal acrylic splints are regarded as the most appropriate devices for RME in young adults.<sup>4,6</sup> RME proponents claim that it causes the least amount of dental movement (Tipping) and the most amount of skeletal movement; it is a controversial topic.<sup>7</sup> Growth

is generally complete by the age of 17 years, with an average transverse growth of 6.9 mm between the ages of 4 and adulthood. Because only a tiny amount of change occurs in the transverse dimension of the maxilla throughout life, a crossbite that develops in the permanent dentition is unlikely to repair itself.<sup>8</sup>

### CASE REPORT

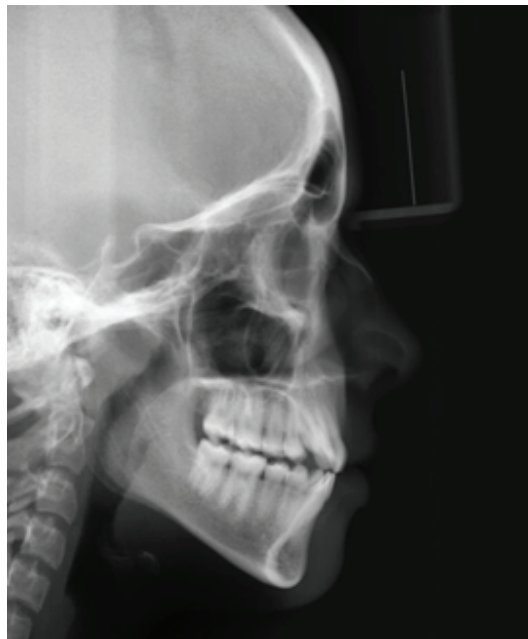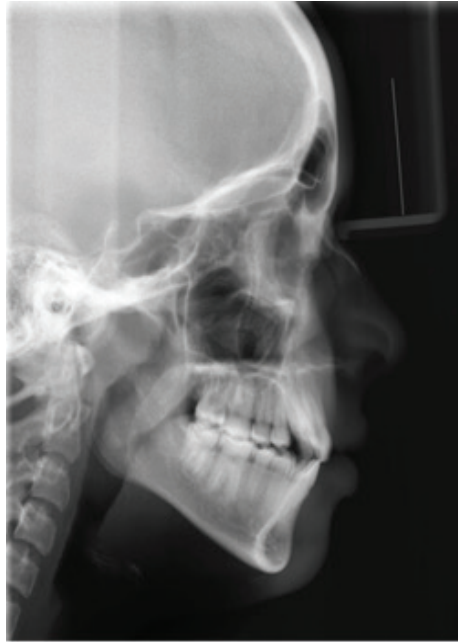A female patient with a chronological age of 12 years has Angle class III malocclusion. In clinical examination, the patient was found to have an edge-to-edge bite and a convex profile, with decreased overjet (0.5 mm) and overbite (0 mm). There was a Stenosis on the right side of the maxilla. Cephalometric analysis demonstrated a skeletal class 3 (ANB:-2°) malocclusion and SNA (77°) SNB (79°) angles. The aim of phase one is to rectify the crossbite and indirectly expand the maxillary arch perimeter. An x-ray of the hand

and wrist revealed the optimal age to begin Phase I treatment. In the MP3cap stage, the patient's skeletal age was 13 years (Figure 1). According to the cephalometric measures (Table 1) and the genetic feature, the patient and parents were informed that an undesired development pattern could emerge (Figure 2).



**Figure 1.** MP3cap stage.

*Rapid Maxillary Expansion in Mixed Dentition Patient with Maxillary Insufficient Correction Subsequented by A Corrective Orthodontic Treatment: Case Report*



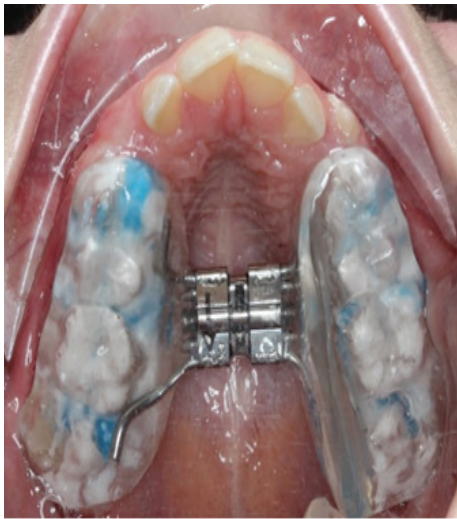**Figure 2.** (A) Pre-treatment lateral cephalometric, (B) Post-treatment lateral cephalometric

**Table 1.** Cephalometric measurements in phase I treatment

		Normal Values			Pre-treatment Values	Post-Treatment Values
Dim.	S-N (mm)	76,9	±	2,8	66,4	68,9
	S-Ar (mm)	46	±	4,2	29	30
Vertical Plane Values	N-S-Ar (°)	123	±	5	126	127
	S-Ar-Go (°)	143	±	6	146	146,1
	Ar-Go-Me (°)	124	±	4,2	128	128,4
	Sum Of Posterior Angles (°)	396	±	3	399,3	402,1
	SN/Go-Gn (°)	32,1	±	5,5	37	37,2
	Y-axis (°)	58	±	3,4	70	71
	N-ANS (mm)	55,3	±	3,2	52,4	53,3
	ANS-Me (mm)	69,5	±	5,3	61,8	65,2
	S-Go (mm)	78,2	±	5,1	72,6	75,7
	Jarabak Ratio	59-63	±		58	59,2
	Max.	SNA (°)	81,8	±	3,5	77
SN/PNS-ANS (°)		7,8	±	2,4	5	6
FH/NA (°)		89,9	±	3,6	83	84
Mand.	SNB (°)	78,9	±	3,9	79	80
	Pg-NB (mm)	1,7	±	1,6	2,1	2,2
	FH/NPg (°)	87,2	±	3	87	86
	Ar-Go (mm)	48,1	±	5,1	43,6	45,8
Max / Mand	Co-A (mm)	92,1	±	2,7	79,4	79,9
	Co-Gn (mm)	118,9	±	5	103,2	108,1
	ANB (°)	2,9	±	2,7	-2	1
	SN / Occlusal plane (°)	14	±	4	22	24

Dim: Dimensions, Max:Maxillary, Mand: Mandibular

Because the patient committed to using the expanders and, most significantly, dental hygiene, the patient was instructed to correct complete crossbite as soon as possible in Phase I. The patient and her family were instructed about the Haas, HYRAX, and quad-helix expander designs. Due to an absent crossbite on the left side, the Single Lingual Sheath Hyrax Screw Bonded Expansion was selected. The permanent molars and premolars on both sides of the maxilla had been bonded. The expansion device could then be cemented with glass ionomer cement (Figure 3).

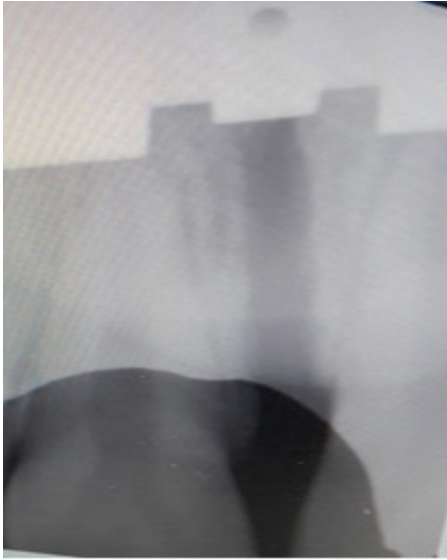

**Figure 3.** Cementing with glass ionomer cement.

After the palatal expander had been cured with a light cure, instructions

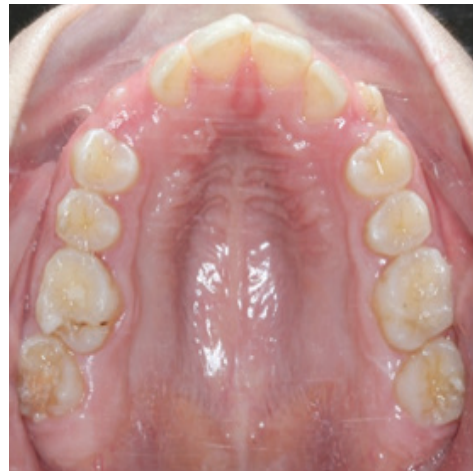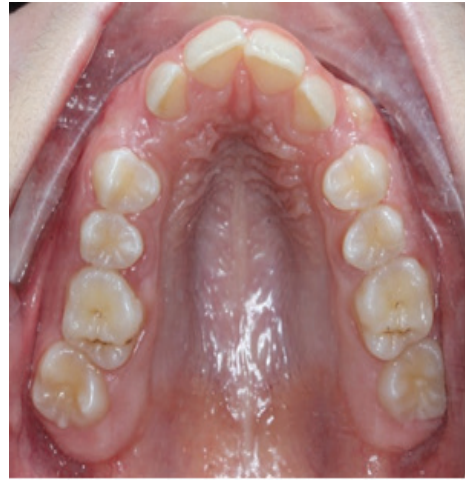for aftercare (eating, hygiene, and activation) were given. The expansion method was performed daily with two-quarters turns (0.5 mm) under clinical observation until the required over-expansion was conducted, as indicated by the observation of diastema expansion and posterior transverse adaptation. An electric pulp tester (EPT) was applied to analyze the vitality of the teeth on the buccal cusp tips of the molars and premolars. Teeth that did not respond to the EPT were thermally tested with Endo Ice. An electric pulp test was applied before starting the orthopedic intervention, after finalizing phase I, and after the orthodontic treatment. Consequently, all of the permanent teeth investigated in this case were vital.

The amount of expansion was observed by increased inter-molar and inter-canine distance (Table 2). The most prominent clinical sign of the expansion is the development of diastema between central incisors. After 33 screw activations, the results were obtained. The periapical radiograph shows true disjunction of the sutures. During the retention period, the diastema recovered to its original size. For a 6-month retention period, the extender was retained as a retainer (Figure 4).



**Figure 4.** Periapical x-ray between teeth no 21 and no 11 shows the mid-palatal suture opening after 33 screw activations

In Phase I, the RME corrected the crossbite through the posterior maxillary teeth tipping. Furthermore, a clinically significant increase in the volume of the maxillary arch allowed the incisors to align with the occlusal line (Figure 5).



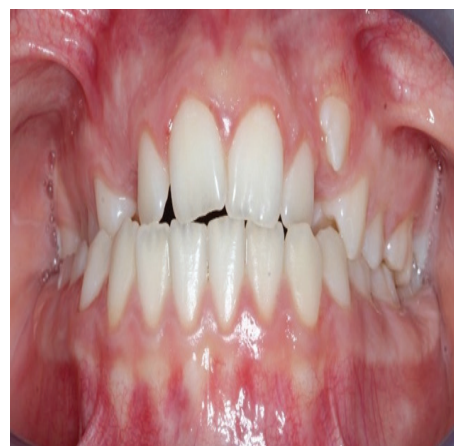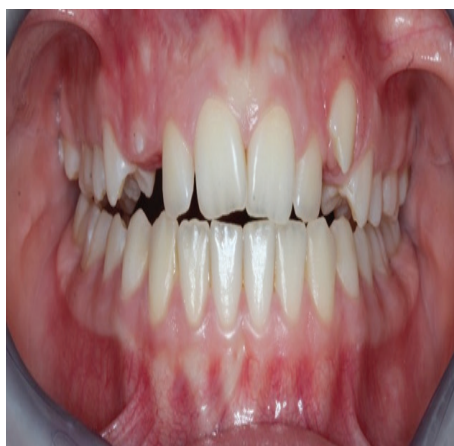**Figure 5.** (A) Pre-treatment intra oral photograph, (B) Post-phase I treatment.

**Table 2.** Model Analysis

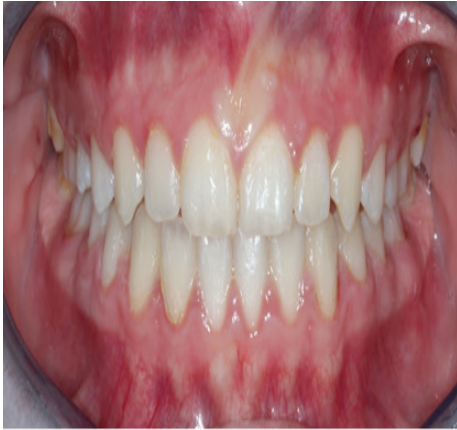	Pre-treatment	Post-Treatment	Difference
<b>Width between lower canines (mm)</b>	25	26	+1
<b>Width between upper canines (mm)</b>	26	35	+9
<b>Width between upper molars (mm)</b>	47	53	+6
<b>Width between lower molars (mm)</b>	47	49	+2

The conventional 0.018-in Roth fixed appliance was applied in the phase II treatment at the age of 13. The classic sequencing of corrective treatment with biomechanical control was used to limit proclination of the lower incisors. To preserve the occlusal plane and avoid its canting throughout the alignment and leveling processes, Class III intermaxillary elastics and vertical elastics in the canine area on the right side were applied. Archwires for retraction and finishing were employed. After the fixed appliance was removed, a removable vacuum-formed retainer (VFR) was placed in the maxillary and mandibular arch. Figure 6 represents the outcomes of alignment, leveling, and intercuspation. The skeletal pattern ( $ANB = 1^\circ$ ) and the proclination of the maxillary incisors with the uprighting of the mandibular

incisors are shown in Table 1.







**Figure 6.** Intra oral photographs (A) Pre-treatment, (B) Post-phase I treatment, (C) Post-phase II treatment

## DISCUSSION

The patient, in this case, exhibited unilateral skeletal posterior crossbite, which necessitated the use of a Single Lingual Sheath Hyrax Screw Bonded type expansion appliance. To avoid insufficient skeletal transverse growth, it is suggested that posterior crossbite be corrected as soon as possible. Treating a posterior crossbite at a young age is recommended to avoid abnormal skeletal growth and ensure stable results. The RME in this clinical instance was conducted in the late mixed dentition and achieved maximal expansion with transverse dimension stability. The RME had valuable skeletal and dental results, correcting transverse

maxillary deficit.

However, as reported by Haas, 1961, it repaired the anterior crossbite on the projection of point “A,” with an increased SNA angle and face convexity angle, causing the anterior crossbite to be corrected even if only momentarily. As observed in this clinical example, one of the stability criteria is maintaining the RME appliance for six months.<sup>9</sup> The EPT test should be done during orthodontic treatment to investigate the pulp health.<sup>10</sup>

The degree of patient participation, motivation, and adaptation during the treatment process, such as the adaptation with the feeling of the presence of the appliances inside the mouth and cleaning the teeth effectively, is critical to the treatment’s effectiveness. They are also equally effective in enhancing the breadth and intermolar angulation while correcting a posterior crossbite.<sup>11</sup> The activation rate in this clinical situation was 2-quarter turns per day. In general, RME exerts a force to the premolars and molars without allowing enough duration for tooth movement, causing the force to be transmitted to the sutures, resulting in a bigger suture opening than the inclination of the teeth.<sup>12</sup> The rapid and slow maxillary expansion

approaches lead to a buccal shift of the first permanent maxillary molars; on the other hand, the slow maxillary expansion group has more significant bodily movement, and the RME group has more inclination movement. Both groups have lateral and vertical bone resorption; however, the slow expansion group encountered substantial bone loss.<sup>13</sup> Due to a combination of factors, including the large arch length perimeter, E-space optimization, vertical and sagittal proportionate growth, and patient acceptance, the functional and cosmetic results were fully achieved.

### CONCLUSION

The appropriate implementation of the modified Single Lingual Sheath Hyrax Screw Bonded expander, promotes beneficial skeletal (orthopedic) and dental (orthodontic) results, allowing for the adjusting of a maxillary crossbite in primary teeth. And for the orthodontic treatment in the permanent teeth, full brackets were applied to achieve the aesthetic appearance and the durability of the outcomes, therefor desirable characteristics have been attained.

### Conflicts of Interest

The authors have no conflicts of interest in the article.

### Acknowledgments

None.

### REFERENCES

1. Ficarelli JP. A brief review of maxillary expansion. *J Pedod* 1978 Fall;3(1):29-35.
2. Bell RA. A review of maxillary expansion in relation to rate of expansion and patient's age. *Am J Orthod* 1982 Jan;81(1):32-37.
3. Angell EH. Treatment of irregularities of the permanent or adult teeth. *Dent Cosmos* 1: 540–544, 1860.
4. J.A.McNamara Jr., “Early intervention in the transverse dimension: is it worth the effort?” *American Journal of Orthodontics and Dentofacial Orthopedics*, vol. 121, no. 6, pp. 572–574, 2002.
5. O. Tanaka, B. Orellana, and G. Ribeiro, “Singular aspects to operate rapid palatal expansion procedures,” *Revista Dental Press de Ortodontia e Ortopedia Facial*, vol. 9, pp. 98–107, 2004.
6. C. J. Vogel, “An interview with James A. McNamara Jr.,” *Dental Press Journal of Orthodontics*, vol. 16, no. 3, pp. 32–53, 2011.
7. Bell RA. A review of maxillary expansion in relation to rate of expansion and patient's age. *Am J Orthod* 1982 Jan;81(1):32-37
8. Bjork A, Skieller V. Growth in the width of the maxilla studied by the implant method. *Scand J Plast*

- Reconstr Surg* 1974;8(1-2): 26–33.
9. A. J. Haas, “Rapid expansion of the maxillary dental arch and nasal cavity by opening the midpalatal suture,” *The Angle Orthodontist*, vol. 31, no. 2, pp. 72–90, 1961.
10. Cho, J. J., Efstratiadis, S., & Hasselgren, G. (2010). Pulp vitality after rapid palatal expansion. *American Journal of Orthodontics and Dentofacial Orthopedics*, 137(2), 254–258. doi:10.1016/j.ajodo.2008.04.023.
11. T. Huynh, D. B. Kennedy, D. R. Joondeph, and A.-M. Bollen, “Treatment response and stability of slow maxillary expansion using Haas, hyrax, and quad-helix appliances: a retrospective study,” *American Journal of Orthodontics and Dentofacial Orthopedics*, vol. 136, no. 3, pp. 331–339, 2009.
12. A. J. Haas, “Long-term posttreatment evaluation of rapid palatal expansion,” *Angle Orthodontist*, vol. 50, no. 3, pp. 189–217, 1980.
13. M. Brunetto, J. Da Silva Pereira Andriani, G. L. U. Ribeiro, A. Locks, M. Correa, and L. R. Correa, “Three-dimensional assessment of buccal alveolar bone after rapid and slow maxillary expansion: a clinical trial study,” *American Journal of Orthodontics and Dentofacial Orthopedics*, vol. 143, no. 5, pp. 633–644, 2013.