




Aydın Dental Journal

Journal homepage: <http://dergipark.ulakbim.gov.tr/adj>



Orthodontic and Surgical Approach: Accelerated Osteogenic Orthodontics

DergiPark
AKADEMİK

Orhan AKSOY¹, Fatma YILDIRIM², M. İrfan KARADEDE³

ABSTRACT

The development of surgically-assisted orthodontic treatment offers solutions to many limitations in orthodontic treatment. This new method has several advantages including reduced treatment time, increased limits of tooth movements, increased amount of alveolar bone, reduced need of extraction, rapid eruption of impacted teeth, and further enhanced post-orthodontic stability. The aim of this article is to present a review of the literature, including historical background, contemporary clinical techniques, advantages, and indications and contraindications of accelerated osteogenic orthodontics.

Keywords: Accelerated orthodontics, surgically-assisted orthodontic tooth movement

ÖZET

Cerrahi destekli ortodontik tedavilerin gelişimi, ortodontik tedavilerdeki bazı sınırlamalara çözüm sunmaktadır. Bu yeni yöntem, azalmış tedavi süreleri, diş hareket limitlerinde ve alveolar kemik miktarında artma, çekim ihtiyacını azaltma, gömülü dişlerin hızlı bir şekilde sürdürülmesi ve son olarak tedavi sonrası stabilitenin geliştirilmesini içeren birçok avantaj sunmaktadır. Bu makalenin amacı, hızlandırılmış ortodontik tedavinin tarihsel arka planı modern klinik teknikleri, avantaj dezavantajları, endikasyon ve kontrendikasyonlarından oluşan literatür derlemesini sunmaktır.

Anahtar Kelimeler: Hızlandırılmış ortodonti, cerrahi destekli ortodontik diş hareketi

¹ Istanbul Aydın University, Faculty of Dentistry, Department of Orthodontics

² Istanbul Aydın University, Faculty of Dentistry, Department of Orthodontics

³ İzmir Katip Celebi University, Faculty of Dentistry, Department of Orthodontics

INTRODUCTION

Aesthetics and duration of treatment are two important issues that patients are concerned with. Aesthetic problems have been overcome with the use of porcelain or lingual braces. In addition, new technologies on wires and braces have focused on reducing the treatment time. Still, some patients wish their duration of treatment to be even shorter. Accelerated orthodontic treatment (or accelerated osteogenic orthodontics [AOO]) is a new method that reduces the duration of treatment. Besides, the AOO technique provides more efficient orthodontic tooth movements and stable results.

Historical background

The studies conducted over the last 50 years have revealed that the tooth movements are accelerated after corticotomy procedures. First, in 1892, L. C. Bryan mentioned about the use of corticotomy for the correction of malocclusions.¹ In 1959, Heinrich Köle corrected the malocclusions with corticotomy by weakening the medullary bone along the apex and the root of tooth.² In subsequent periods, many authors corrected the malocclusions with decortication of alveolar bone and reported that the rapid tooth movements were obtained by en bloc displacement of bone.¹

In 2001, two brothers, William M. Wilcko who is orthodontist and Thomas Wilcko who is periodontist, introduced the Wilckodontics® System. In this method, the cortical areas creating resistance to tooth movements are removed by using corticotomy and the tooth movements are accelerated.³ They mentioned some bone activations during the tooth movements and they achieved it by using a resorbable bone graft substitute. In this way, performing the orthodontic treatment with

bone augmentation helps in the formation of a new bone in that region; otherwise, no new bone formation is likely to occur. On this topic, Wilcko brothers hypothesized that rapid tooth movements result from the remineralization-demineralization mechanism of the bone, not from the en bloc displacement of the bone. Moreover, they substantiated their hypothesis through a computed tomography (CT) analysis both before and after the treatment. This technique is endorsed by the American Association of Periodontology and called as “Accelerated Osteogenic Orthodontics”.¹ (Fig. 1)

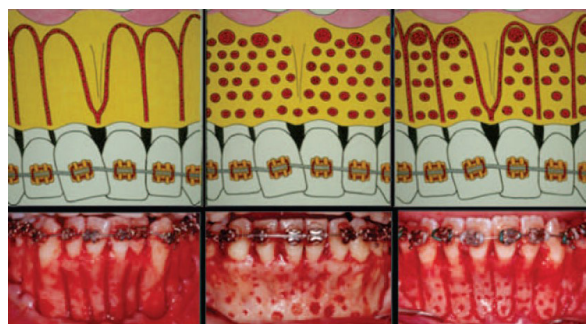


Figure 1. Corticotomy and bone perforations¹

Indications and Contraindications

Indications of AOO are as follows:

- 1) To increase the limits of tooth movements and reduce the need of extraction
- 2) To shorten the duration of orthodontic treatment.
- 3) To increase the amount of alveolar bone and obtain more robust periodontium.
- 4) To replace the lost bone volume in cases of dehiscence by reshaping the alveolar bone.
- 5) To accelerate the eruption of the deeply impacted teeth^{1,2,3} (Fig. 2).

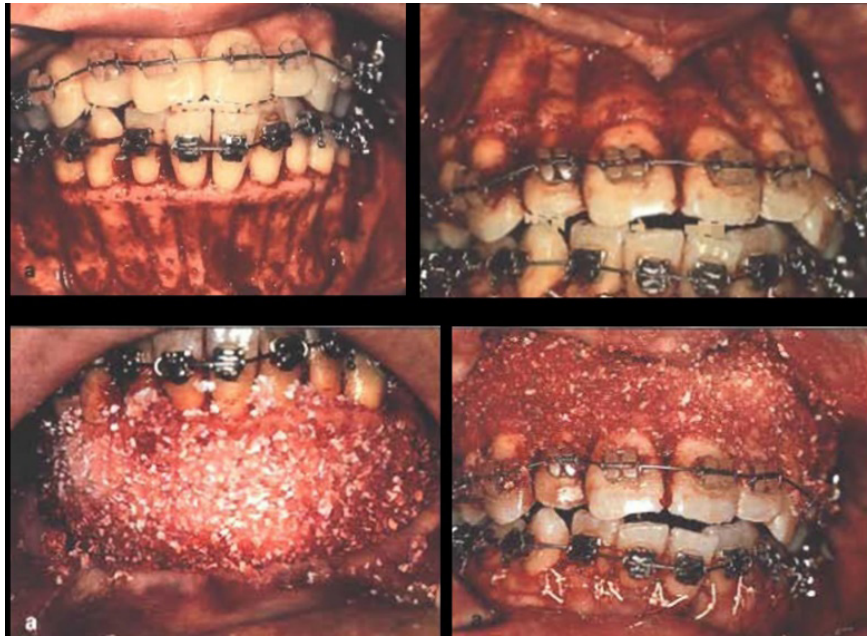

Figure 2. Rapid orthodontic decrowding with alveolar augmentation ²

Wilcko brothers claimed that this technique could be applied to any patient in whom fixed orthodontic treatment can be performed. However, there are some contraindications:

- 1) Active periodontitis
- 2) Uncontrolled osteoporosis or other kinds of bone diseases
- 3) Any disease that requires the use of long-term anti-inflammatory or immunosuppressive drugs, or steroids
- 4) Patients with any disease that leads to delayed healing process
- 5) Use of nonsteroidal anti-inflammatory drugs (because the active agent is an inhibitor of prostaglandin and thus osteoclastic activity is reduced). ^{1, 2, 3}

Clinical Procedures of AOO

This treatment is a multidisciplinary procedure, requiring successful operation of the surgeon and a well-planned treatment by an orthodontist. As this method requires a major surgical procedure, the patient is required to maximize the oral hygiene.⁵

The procedure begins with orthodontic treatment. The bands and braces are placed and if the second molars are present, they are banded in order to enhance the anchorage. The reason for this is to avoid losing control of tooth movements due to the weakening of the cortical bone in the surgical site. A light Ni-Ti wire is ligated to the braces within several weeks prior to the surgery.²

Preoperatively, the IV sedation is given to the patient and the surgical procedure is initiated under local anesthesia. The crevicular incision is made buccally and lingually extending a minimum of two or three teeth beyond the area to be treated. A full-thickness flap is reflected on both buccal and lingual aspects from the both sides of the premolars. The surgeon must avoid vertical incisions as much as possible for the purpose of maintaining the nutrition of tissues. A full-thickness flap is raised up to the root levels except for the papillary region of the maxillary central incisors because the nasopalatine foramen plays a very important role for the tissue nutrition in that region. Care

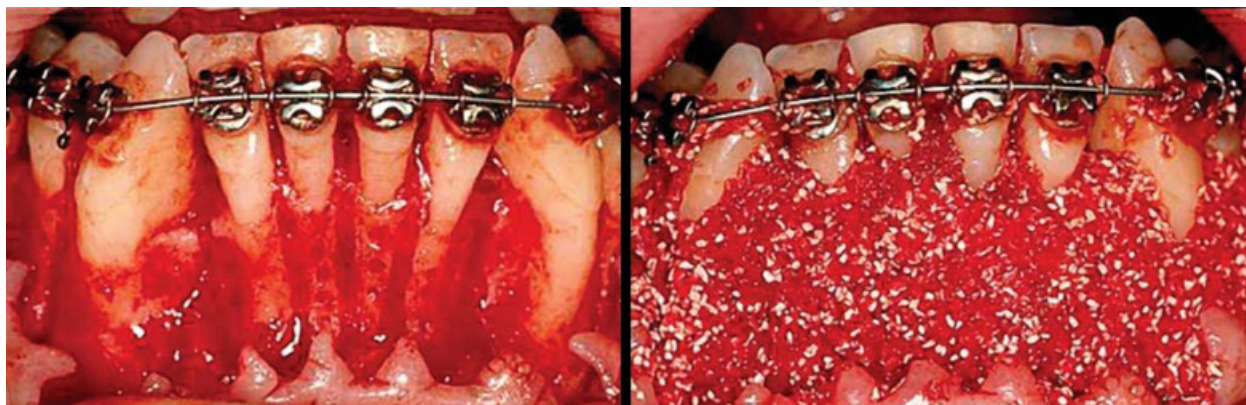


Figure 3. Bone decortication and placement of bone grafts⁹

should be taken not to damage any of the anatomical structures in both arches.²

After the flap is lifted, a high-revolution speed physiodispenser with a long-neck, sharp, steel round bur is used for the weakening of the bone after forming small circular-shaped perforations along with corticotomy cuts between 2-3 mm below the alveolar crest and 2-3 mm below the root apex. The bone is weakened with the cortical perforations to increase blood supply. If the corticotomy is made only from the labial region, an ideal bone demineralization would not occur, mainly due to asymmetrical bone weakening. If the bleeding is not sufficient for the tissue nutrition, additional corticotomy can be performed. Following the corticotomy cuts, there should be no bone luxation in that region.²

Allograft material (demineralized frozen-dried bone allograft) and calf bone graft material (Bio-Oss) are dry mixed to obtain resorbable bone graft material in order to ensure the bone augmentation, which are then placed over the decorticated areas mixed with clindamycin phosphate solution. The grafts with 2 or 3 mm thickness are spread under the flap and the flap is sutured with 4/0 Gore-Tex suture without sliding. Care should be taken to ensure that the papillae are placed in their original locations. The reason for using

resorbable graft is both the activation of new bone formation and the more regular healing of the damaged regions.² (Fig. 3)

As mentioned previously, the canine retraction and the eruption of the impacted teeth are also included in the indications of these operations. The surgical and orthodontic procedures in the canine retraction process are almost the same. The braces are bonded 2 weeks before the surgery and a very light NiTi wire is placed.² IV sedation is given to the patient before surgery and the surgery is performed under local anesthesia. The labial and lingual full-thickness flap is removed and the first premolar teeth are extracted. If possible, the cortical bone surrounding the extraction side is weakened to the apex of the canine roots. However, this weakening should be limited to the labial, lingual and distal surfaces of canines. After corticotomy, 9 ccs of bone graft including two-thirds of cortical graft and one-third of calf bone graft is placed and sutured. Two weeks later, the sutures are removed. Naturally, the distal movement of canine is naturally desired. Therefore, the thinnest area in mesio-distal direction must be the distal part of the interseptal bone. If the mesial part of the interseptal bone of the second premolar teeth is too thin, a second premolar mesialization, which is an undesirable situation, occurs together with canine distalization. Care must

be taken during the cortical bone weakening surgery to avoid damaging the anatomical structures such as maxillary sinus in the upper jaw and the inferior alveolar neurovascular bundle in the lower jaw. This operation increases the rate of canine distalization movement compared to the canine retraction mechanics without corticotomy.⁶

Following the operation, the patient is usually prescribed 250 mg antibiotics (penicillin derivatives) four times a day. 550 mg naproxen sodium derivatives such as analgesic agents are given and the patient should be advised to maximize oral hygiene. 4 of 5 days after the surgery, the patient should be advised to visit the clinic for a follow-up check. The aim of this visit is to check whether there is any sliding or separation of the flap. The sutures are removed two weeks after the surgery and the orthodontic treatment can be resumed several days later.⁶

Gürkan et al.⁷ reported that the canine retraction procedures normally last 6 or 8 weeks but if the distraction osteogenesis procedures are performed, then it lasts 8 or 14 days. In this study, the retraction force was applied to the canine 3 days after the distraction surgery. The rate of distraction was 0.8 mm per day, divided into two 0.4 mm equal increments. The second premolar and the first molar teeth were used as an anchorage and there was no anchorage loss. Mild inflammation was observed after the operations, but this did not disturb the patients in the postoperative period. In clinical and radiographic examinations, no root resorption, devitalization, or periodontal problems were observed. The study concluded that the fixed orthodontic treatment should be immediately initiated as soon as the desired amount of retraction is achieved.⁷

Sebaoun et al.⁸ conducted a study on rats and reported that the modeling of the trabecular bone and lamina dura was 3 times faster following selective alveolar decortication.

Tissue healing after alveolar decortication consists of three stages. In the first stage, the local tissues begin to renew themselves rapidly, leading to the formation of osteoprogenitor cells and osteoinductive agents. In the second stage, the slow tissue healing is accelerated, which is called “osteopenia” and means that the density of bone is decreased with no change in the amount of bone. Finally, proper anatomical areas occur and these areas provide rapid tooth movements through effective biomechanical forces. Rapid tooth movements persist until alveolar decalcification is completed as a result of medullar bone osteopenia. In this way, the rate of orthodontic treatment is increased 2-3 times compared to treatment without the application of AOO.¹

So, is the rate of the treatment the only advantage of AOO?

Certainly, no. This procedure increases not only the rate of the treatment but also the amount of tooth movements. Proffit⁸ reported that the tooth movements are limited in adult orthodontic patients. According to Proffit, 7 mm retrusion, 2 mm protraction, 4 mm extrusion, and 2 mm intrusion occur in the upper central incisors with standard orthodontic therapy, whereas 8 mm retrusion, 5 mm protraction, 10 mm extrusion, and 5 mm intrusion occur after alveolar decortication procedures. During these movements, the amount of alveolar bone increases with no expansion in midpalatal suture and the orthodontic treatment can be performed with no need for tooth extraction in moderate crowding cases.¹

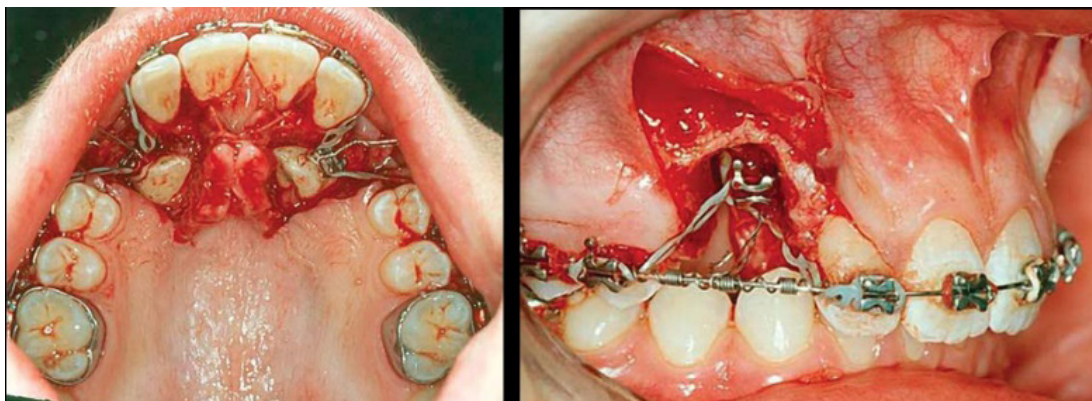


Figure 4. Rapid eruption of impacted canines. ⁸

In the lower central incisors, 3 mm retrusion, 5 mm protraction, 2 mm extrusion, and 4 mm intrusion occur following the standard procedure, whereas 4 mm retrusion, 9 mm protraction, 6 mm extrusion and 7 mm intrusion occur after alveolar decortication. ¹

One of the most important situations prolonging the period of orthodontic treatment is impacted teeth. Canines, premolars, incisors, and particularly the third molars often remain buried and the treatment of impacted teeth should be carried out through cooperation between the surgery and orthodontics clinics. The duration of these treatments can vary in different cases. The success of treatment is higher in younger patients; however, the risk of ankylosis increases with age and this adversely affects the treatment success. Prior to the orthodontic eruption of impacted teeth, stainless steel wires must be passed into the arch in order avoid tipping of the neighboring teeth. The localization of impacted teeth is one of the factors that affect the success and duration of the procedure. If the impacted teeth go beyond the alveolar bone and remain under the gums, the window form incision is made without lifting the flap, the bracket is placed and the tooth is erupted. ⁹ (Fig. 4)

Nevertheless, the situation may be different if it remains under the alveolar bone. In this

case, it is necessary to completely open the clinical crown, the bone around the impacted tooth should be weakened with alveolar decortication, and the eruption way should be guided by the alveolar osteotomy cuts. This requires a major surgery compared to the first situation. The impacted teeth may be positioned labially or buccally. The full-thickness mucoperiosteal flap is elevated from the labial sulcus for labially positioned teeth. In the cases of canine eruption, the borders of the flap must include the first premolar and lateral incisor in order to keep the working area broad and thus to prevent the tearing of the flap and to provide better nutrition. There is no need to remove the lingual flap in addition to the labial flap. However, care should be taken to retain 1.5 mm bone both at the mesial and distal sides of adjacent teeth. ¹⁰

The eruption procedure of lingually impacted teeth is slightly different and performing decortication in such situations will help a lot in this area. Both labial and lingual full-thickness mucoperiosteal flaps are elevated and the flap is released with vertical incisions in order to reach the deeply impacted teeth more easily. After decortication, at least 1.5 mm bone should be remained at the mesial and distal sides of adjacent teeth. To the possible extent, the bracket should be placed at an ideal location. If no opportunity is available

for this placement, the distolabial area can be preferred. After all these processes, sutures are tied and are later removed approximately a week later and the force is applied for tooth eruption.¹⁰

Disadvantages of AOO

It is a mildly invasive surgical procedure and like all surgeries, it has its risks like pain and possibility of infection. Extra-surgical cost is one of the disadvantages of this procedure. The crestal bone loss and gingival recessions may occur. Proper case selection is necessary to attain a good result. For example, this technique is not recommended in Class-III malocclusions.¹ And also patients who take NSAIDS on regular basis or have other chronic health problems cannot be treated with this technique.¹¹

CONCLUSION

Throughout human history, people have developed many ideas and the new technologies produced by humans have systematically made our lives more comfortable and prosperous. Orthodontic treatment combined with surgery may seem challenging and the patients may feel discomfort after the operations; however, this period may last only 3-4 days with good oral hygiene and medical support. More efficient orthodontic treatments which may last as short as 6-8 months, compared to traditional orthodontic treatments which last 20-24 months, provide more stable results as well as increased bone support. Moreover, these treatments are more popular since they provide greater aesthetic and healthy periodontal status. Considering that the procedure is a good example of team work, any mistake in surgery or orthodontics affects the success of the treatment.

REFERENCES

- [1] Ferguson DJ, Wilcko WM, Wilcko MT. Selective alveolar decortication for rapid surgical-orthodontic resolution of skeletal malocclusion treatment. *Distraction Osteogenesis of the Facial Skeleton*. Hamilton:BC Decker, 2006: 199-203.
- [2] Wilcko Wm, Ferguson DJ, Bouquot JE, Wilcko MT. Rapid orthodontic decrowding with alveolar augmentation: case report. *World J Orthodont* 2003; 4: 197-505.
- [3] Neetha J Shetty. Periodontally assisted osteogenic orthodontics: A review. *IAIM*, 2015; 2 (2): 165-168.
- [4] Johnson Ly, Mangalekar Sa, More Sh, Thakur Pr, Reddy Na, Sodawala Ja. Periodontal Accelerated Osteogenic Orthodontics – An Interdisciplinary Approach. *Chhattisgarh Journal of Health Sciences*, September 2013;1(1) : 61-65
- [5] Wilcko MT, Wilcko WM, Pulver JJ, Bissada NF, Bouquot JE. Accelerated osteogenic orthodontics technique: A 1-stage surgically facilitated rapid orthodontic technique with alveolar augmentation: *J oral maxillofac surg.* 2009;67(10):2149-2159.
- [6] Wilcko MT, Wilcko WM, Breindel-Omniewski K, et al: The periodontally “accelerated osteogenic orthodontics” (PAOO™) technique: Efficient space closing with either orthopedic or orthodontic forces. *J Implant Adv Clin Dent* 2009; 1:45.
- [7] Gürgan CA, İşeri H, Kişnişçi R, Alteration in gingival dimensions following rapid canine retraction using dentoalveolar distraction osteogenesis. *EJO* 2005; 27: 324-332 doi: 10.1093/ejo/cji011.
- [8] Sebaoun, J. D., Kantarci, A., Turner, J. W., Carvalho, R. S., Van Dyke, T. E., & Ferguson, D. J. Modeling of trabecular bone and lamina dura following selective alveolar decortication in rats. *Journal of periodontology*, 2008; 79(9): 1679-1688.
- [9] Proffit WR, editor. *Contemporary orthodontics*, 3rd edition. Mosby; 2000.
- [10] Wilcko MT, Wilcko MW, Marquez MG, Ferguson DJ. Chapter 4. The contribution of periodontics to orthodontic therapy. In: *Practical Advanced Periodontal Surgery*. Wiley Blackwell 2007: 23-50.
- [11] Wilcko MT, Wilcko WM, Bissada NF: An evidence-based analysis of periodontally accelerated orthodontic and osteogenic techniques: A synthesis of scientific perspectives. *SeminOrthod* 2008; 14: 305.