











HISTOLOGICAL STUDY OF A CORRECTIVE INFLUENCE OF SODIUM 2-((4-AMINO-5-(THIOPHEN-2-YLMETHYL)-4H-1,2,4- TRIAZOL-3-YL)THIO) ACETATE ON THE STATE OF RATS LIVER UNDER CONDITIONS OF ACUTE IMMOBILIZATION STRESS

*AKUT HAREKETSİZLİK STRES KOŞULLARINDA SODYUM 2-((4-AMİNO-5-(TİYOFEN-2-İL
İLMETİL)-4H-1,2,4-TRİAZOL-3-İL)TİYO) ASETAT'IN SIÇAN KARACİĞERİNİN DURUMU
ÜZERİNDEKİ DÜZELTİCİ ETKİSİNİN HİSTOLOJİK ÇALIŞMASI*

Andrii SAFONOV^{1*} , **Denys DEMIANENKO²** , **Yevheniia VASHCHYK³** ,
Yuliia LARIANOVSKA⁴ , **Dmytro LYTKIN⁴** , **Roman SHCHERBYNA¹** ,
Anna OCHERETNIUK⁵ , **Svitlana ROMANOVA⁶** 

¹Zaporizhzhya State Medical University, Faculty of Pharmacy, Department of Natural Sciences
for Foreign Students and Toxicological Chemistry, 69035, Zaporizhzhya, Ukraine

²Sumy National Agrarian University, Faculty of Veterinary Medicine, Postgraduate of
Department of Veterinary examination, Microbiology, Zoohygiene and Safety and Quality of livestock
products, 40021, Sumy, Ukraine

³National University of Pharmacy, Faculty of Medical and Pharmaceutical Technologies,
Department of Veterinary Medicine and Pharmacy, 61000, Kharkiv, Ukraine

⁴Educational and Scientific Institute of Applied Pharmacy, National University of Pharmacy,
61000, Kharkiv, Ukraine

⁵National Pirogov Memorial Medical University, Faculty of Pharmacy, Department of
Pharmaceutical Chemistry, 21018, Vinnytsya, Ukrain

⁶National University of Pharmacy, Faculty of Pharmacy, Department of Pharmacognosy, 61000,
Kharkiv, Ukraine

* **Corresponding Author / Sorumlu Yazar:** Andrii Safonov
e-mail / e-posta: 8safonov@gmail.com, **Phone / Tel.:** +380661777106

ABSTRACT

Objective: *The aim of the work was the histological study of a corrective influence of sodium 2-((4-amino-5-(thiophen-2-ylmethyl)-4H-1,2,4-triazol-3-yl)thio) acetate on the state of rats liver under conditions of acute immobilization stress.*

Material and Method: *As an object of research sodium 2-((4-amino-5-(thiophen-2-ylmethyl)-4H-1,2,4-triazol-3-yl)thio) acetate was used. All substances were injected intragastrically, daily for 5 days in appropriate doses on an empty stomach from 9.00-10.00. 1 hour after the last injection, immobilization 6-hour stress was simulated. The central part of the liver was fixed for further histological examination in 10% formaldehyde solution, dehydrated in alcohols of increasing strength, poured into paraffin.*

Result and Discussion: *The results of the study demonstrate the presence of stress-protective properties of sodium 2-((4-amino-5-(thiophen-2-ylmethyl)-4H-1,2,4-triazol-3-yl)thio) acetate in the model of acute immobilization stress, which was reproduced for 6 hours. As can be seen from the described and presented microscopic picture, the test sample to some extent reduced the degree of stress damage to the liver. In terms of the positive effect on the histological condition of the liver parenchyma (a more pronounced structural orientation of hepatocytes was noted, their beam structure was contoured, dystrophic changes of hepatocytes are less pronounced, round cell infiltrates and foci of hepatocyte necrosis are absent), sodium 2-((4-amino-5-(thiophen-2-ylmethyl)-4H-1,2,4-triazol-3-yl)thio)acetate exhibits a stress-protective effect in the model of acute immobilization stress. We can conclude about similarity of activity of the test sample with comparison drug (Mebicar®) at studying of influence on a histologic condition of a liver parenchyma*

Keywords: *1,2,4-triazole, acute immobilization stress, heterocyclic compounds, histological study*

ÖZ

Amaç: *Çalışmanın amacı, akut immobilizasyon stresi koşulları altında sodyum 2-((4-amino-5-(tiofen-2-ilmetil)-4H-1,2,4-triazol-3-il) tio)asetat'ın sıçan karaciğeri üzerindeki düzeltici etkisinin histolojik açıdan çalışılmasıydı.*

Gereç ve Yöntem: *Araştırmanın konusu olarak sodyum 2-((4-amino-5-(tiofen-2-ilmetil)-4H-1,2,4-triazol-3-il) tio)asetat kullanılmıştır. Tüm maddeler uygun dozlarda 5 gün süreyle günde 9.00-10.00 saatleri arasında aç karnına intragastrik olarak uygulanmıştır. Son enjeksiyondan 1 saat sonra immobilizasyon 6 saatlik stres simüle edilmiştir. Karaciğerin merkezi kısmı, daha sonra yapılacak histolojik incelemeler için %10 formaldehit çözeltisi içinde sabitlenmiş, artan konsantrasyonda alkollerde dehidre edilmiş, parafine dökülmüştür.*

Sonuç ve Tartışma: *Çalışmanın sonuçları, 6 saat boyunca oluşturulan akut immobilizasyon stresi modelinde sodyum 2-((4-amino-5-(tiofen-2-ilmetil)-4H-1,2,4-triazol-3-il) tio)asetat'ın stresten koruyucu özelliklerinin varlığını göstermektedir. Açıklanan ve sunulan mikroskopik resimden görülebileceği gibi, test numunesi bir ölçüde karaciğerdeki stres hasarının derecesini azaltmıştır. Karaciğer parankiminin histolojik durumu üzerindeki olumlu etkisi açısından (hepatositlerin daha belirgin bir yapısal yönelimi gözlenmiştir, giriş yapıları şekillendirilmiştir, hepatositlerin distrofik değişiklikleri daha az belirgindir, yuvarlak hücre infiltratları ve hepatosit nekroz odakları yoktur, sodyum 2-((4-amino-5-(tiofen-2-ilmetil)-4H-1,2,4-triazol-3-il)tio)asetat, akut immobilizasyon stresi modelinde stres koruyucu bir etki sergilemektedir. Karaciğer parankimasının histolojik koşulları üzerindeki etkileri açısından test örneği ile karşılaştırılan ilacın (Mebicar®) aktivitelerindeki benzerlik ileri sürülebilir.*

Anahtar Kelimeler: *1,2,4-triazol, akut immobilizasyon stresi, heterosiklik bileşikler, histolojik çalışma*

INTRODUCTION

There is a theory that most diseases that occur in humans are caused by stress. In general, stress is a kind of protection of the body against external stimuli. It allows people to better adapt to the modern pace of life. But constant stress causes failures in various body systems (stomach, liver, adrenal glands, thymus, etc.), which leads to fatal consequences [1].

One of the mechanisms to reduce stress is a stress-implementing system that coordinates adaptation processes, but under conditions of strong stress, the system can lead to stress-induced

damage. Studies show that under the influence of immobilization stress there are irreversible changes in blood composition, structure and function of internal organs [2, 3].

There are drugs that in one way or another can reduce the effects of stimuli on the body and thus reduce stress. These are substances with anxiolytic, stress-protective, nootropic and antioxidant effects [4].

1,2,4-Triazole derivatives are of great interest. A huge number of compounds have already been synthesized among 1,2,4-triazole derivatives [5-10]. Some of them have proven themselves as antimicrobial, antifungal, actoprotective, diuretic, antipyretic substances [11-15].

The sodium 2-((4-amino-5-(thiophen-2-ylmethyl)-4H-1,2,4-triazol-3-yl)thio)acetate is a derivative of the 1,2,4-triazole system. This compound belongs to the class of low-toxic substances and has already proven itself as an actoprotective agent [16]. An interesting feature of some anti-stress drugs is not the suppression of efficiency and concentration, but rather increase. Thus, it would be interesting to investigate the anti-stress properties of this compound. The study of morphological changes in the liver is one of the factors of anti-stress properties of the new substance. [17]

The aim of the work was the histological study of a corrective influence of sodium 2-((4-amino-5-(thiophen-2-ylmethyl)-4H-1,2,4-triazol-3-yl)thio)acetate on the state of rats liver under conditions of acute immobilization stress.

MATERIAL AND METHOD

As an object of research sodium 2-((4-amino-5-(thiophen-2-ylmethyl)-4H-1,2,4-triazol-3-yl)thio)acetate (test sample) was used [16]. Taking into account the results of previous studies, a dose of 100 mg / kg was chosen in this experiment, which has already demonstrated the presence of actoprotective properties. Mebicar (Adaptol®, tetramethyltetraazabicyclooctanedione) (a commercial drug with proven anxiolytic, stress-protective, nootropic and antioxidant effects) was used as a comparison drug (reference sample). The range of doses equivalent to the experimental animals for the reference sample (62 mg / kg - 155 mg / kg) was determined taking into account the interspecific difference in body weight and surface area, taking into account the daily therapeutic doses for the clinical. [18] Based on the design of the experiment, a dose of the reference sample of 100 mg / kg was selected, which practically corresponds to the equivalent of the average therapeutic dose for animals and is quantitatively equal to the used dose of the test sample.

Studies of stress-protective properties were performed on 28 white outbred female rats aged 12 months (270 ± 20 g), which were kept in standard conditions for this species (temperature 18-25°C, relative humidity $55 \pm 10\%$, 12:12 hour cycle day-night, with free access to water and food) on the basis of the vivarium of the Educational and Scientific Institute of Applied Pharmacy of the National University of Pharmacy [19]. All stages of the study were conducted in accordance with Directive

2010/63 / EC of the European Parliament and of the Council of 22 September 2010 on the protection of animals used for scientific purposes (Minutes of the Commission on Bioethics № 6 of 08.06.2021) [20].

After a period of animal adaptation, it was randomized to minimize differences in mean body weight into 4 experimental groups (7 animals each):

- Negative control (NC) - animals that were not subject to immobilization stress;
- Positive control (PC) - animals subjected to immobilization stress;
- Reference group (RG) - animals that received a reference sample before immobilization stress;
- Experimental group (TG) - animals that received a test sample before immobilization stress.

The test agents were injected intragastrically using a special metal probe in the form of a suspension with purified water (20 mg / ml). The drugs were injected daily for 5 days in appropriate doses on an empty stomach from 9.00-10.00. 1 hour after the last injection, immobilization 6-hour stress was simulated. For immobilization stress the animals were fixed on the plate with their stomach up for 4 limbs [21]. After 6 hours rats were released.

Animals were euthanized humanely in a CO₂ chamber 39 hours after completion of immobilization. The period before euthanasia was due to the period of manifestation of changes at the stage of stress response [21].

From each animal made 7 samples for research. There were 7 animals in each experimental group. Microscopic examination was performed on all fields of view of each sample.

Liver samples were fixed in 10% formalin solution. Then the samples were washed with water, then - dehydration of samples in ethyl alcohol of increasing concentration (50, 60, 70, 80, 96%). After that, the samples were alternately placed in an alcohol-chloroform mixture, then in pure chloroform, then in chloroform-paraffin suspension, then the samples were poured into pure paraffin. Micropreparations (the thickness is 5µm) were stained with Hematoxylin® Harrisa and Eosin® Diapath (Italy).

Examination of was performed under a Granum light microscope, microscopic images were photographed with a Granum DSM 310 digital video camera. Photos were processed using Toup View.

RESULT AND DISCUSSION

As shown by microscopy, liver tissue had a typical structure for this species for intact rats from the group of negative control. The particles are not separated from each other by connective tissue layers. Their limit is determined by triads. Zones of triads (portal tracts) are narrow. The hepatic lobules are formed by a system of beams, which are interconnected. The plates themselves consisted of a series of hepatocytes, which are located fairly regular radial strands. The most pronounced radial direction of cell strands is centrilobular. Hepatocytes had a characteristic polygonal shape, their border is quite clear. Cell nuclei of regular round

shape, located centrally. Heterogeneity of nucleus size within the physiological norm. The vast majority of nuclei contained one large enough nucleolus, two or more - much less often. Dinuclear hepatocytes were quite common. The cytoplasm of hepatocytes is uniformly stained, optically dense, and small accumulations of fine-grained basophilic material are visible in the perinuclear zone. No inclusions visible in the cytoplasm at the optical level were determined, mitosis was not visible in the cells. The lumen of the intraparticle sinusoidal hemocapillaries is normal, as a rule, it did not contain blood, a moderate number of lymphoid cells was observed. Stellate reticuloendotheliocytes (Kupffer cells) are without features. The condition of the epithelium of the bile ducts and endothelium of the terminal branches of blood vessels (veins, arteries) in the triads, as well as the endothelium of other blood vessels, is within normal limits (Figure 1).

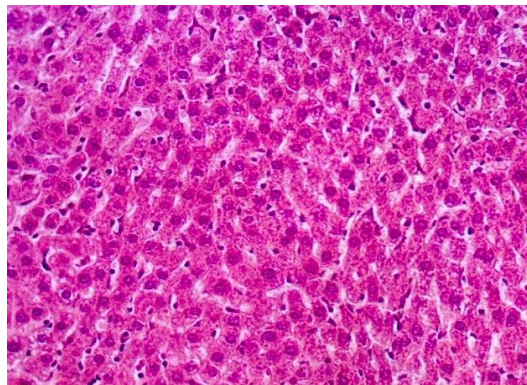


Figure 1. The liver of an intact rat (NC) The radial orientation of the hepatocyte strands is not violated, the lumen of the hemocapillaries is normal, does not contain blood. Hematoxylin-eosin. x200.

39 hours after 6 hours of immobilization stress, the cytoarchitectonics of rat liver was focally disturbed - loss of radial orientation of hepatocytes were revealed. Mostly more affected periportal lobules and perivascular areas. The hepatocytes of these areas are of varying severity dystrophic (hydropic, balloon dystrophy in combination with lipid dystrophy) changes. Some of the cells are in a state of decay (Figure 2).

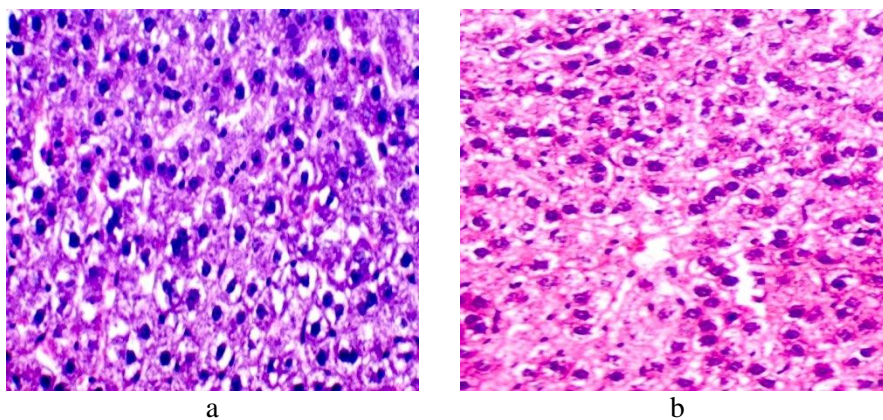


Figure 2. Rat liver 39 hours after immobilization stress (PC): a - violation of the radial orientation of hepatocytes, balloon-lipid cell dystrophy; b - decay of some hepatocytes. Hematoxylin-eosin. x250.

There is a clear venous plethora. Focal sinusoidal blood capillaries are clearly dilated, full-blooded, marked erythrocyte sludge (Figure 3).

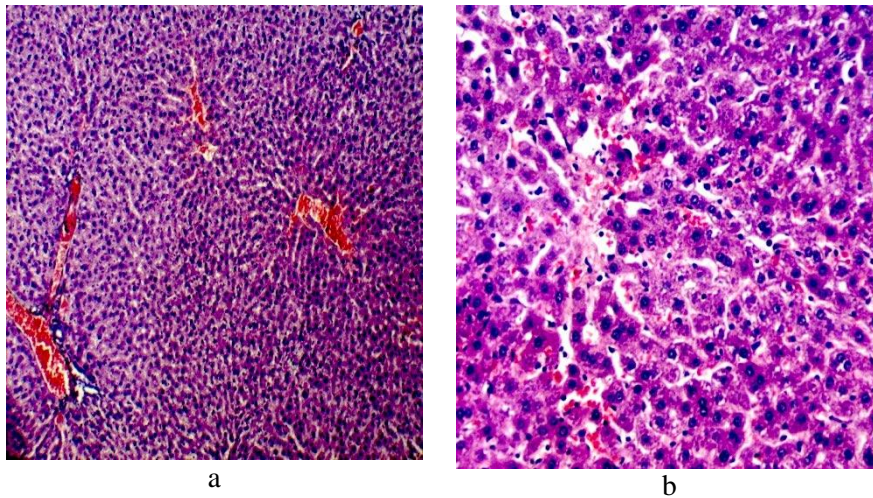


Figure 3. Rat liver 39 hours after immobilization stress (PC): a - pronounced plethora of venous vessels (x100); b - dilation and fullness of blood capillaries (x200). Hematoxylin-eosin.

In addition, in some animals, round cell infiltrates of perivascular and around triads, foci of hepatocyte necrosis with cellular infiltration of dead cells were found to be of different severity (Figure 4).

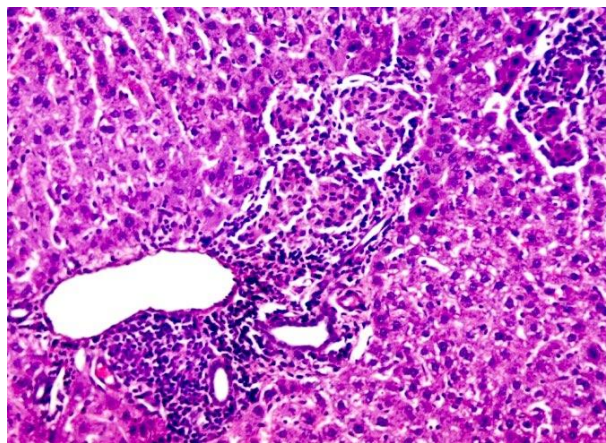


Figure 4. Rat liver 39 hours after immobilization stress (PC). Distinct round-cell infiltration in the triad zone, foci of hepatocyte necrosis with cellular infiltration of dead cells. Hematoxylin-eosin. x200.

There was a decrease in dinuclear hepatocytes, more noticeable near the areas of violation of the cytoarchitectonics of the parenchyma, an increase in cells with signs of apoptosis (intense eosinophilic cytoplasm and pyknotic nucleus), the appearance of hepatocytes with hypertrophic nuclei (Figure 5).

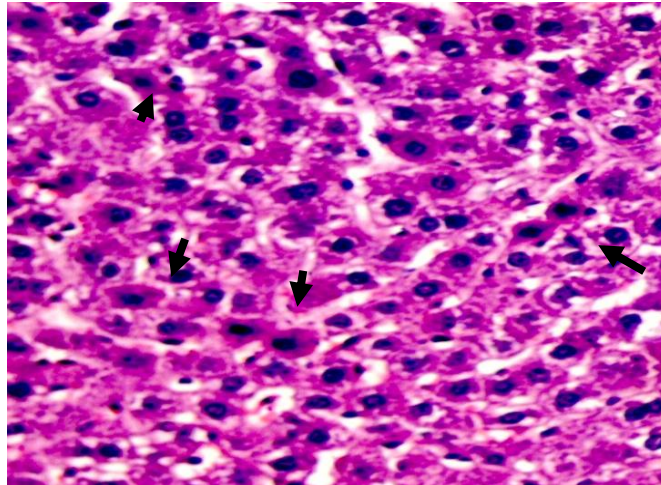


Figure 5. Rat liver 39 hours after immobilization stress (PC). Increase in cells with signs of apoptosis (arrows), appearance of cells with hypertrophic nuclei, decrease in dinuclear hepatocytes. Hematoxylin-eosin. x400.

The obtained microscopic data correspond to the histological picture of stress liver damage at the stage of anxiety (end of stage) stress response [17, 22].

After prophylactic use of the reference drug in 60% of rats there was a more pronounced beam orientation of hepatocytes (although the areas of violation of cytoarchitectonics were still quite large). Both hepatocytes without signs of dystrophy and altered parenchymal cells were detected in these areas, but the severity of dystrophic changes was reduced compared with control pathology. In most rats there was a fairly pronounced fullness of venous vessels, sinusoidal capillaries (Figure 6), different severity of hepatocyte necrosis (Figure 7), moderately weak round cell infiltration perivascularly (Figure 8).

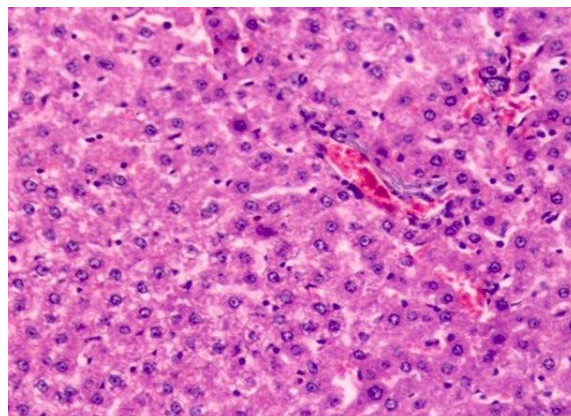


Figure 6. Liver of a rat injected with a reference drug for immobilization stress (RG). More pronounced beam orientation of hepatocytes, reduction of manifestations of cell dystrophy, venous plethora of venous structures. Hematoxylin-eosin. x250.

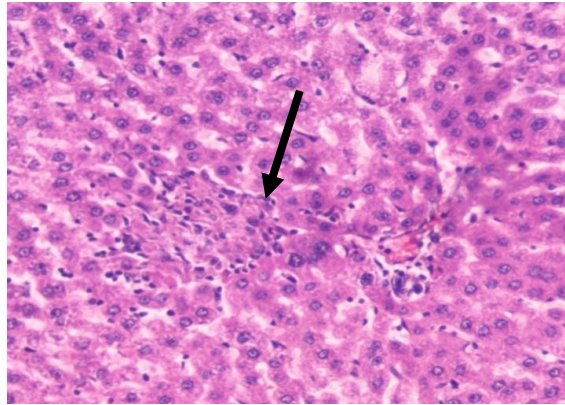


Figure 7. The liver of a rat, which was injected with a reference drug (RG). The focus of hepatocyte necrosis. Hematoxylin-eosin. x250.

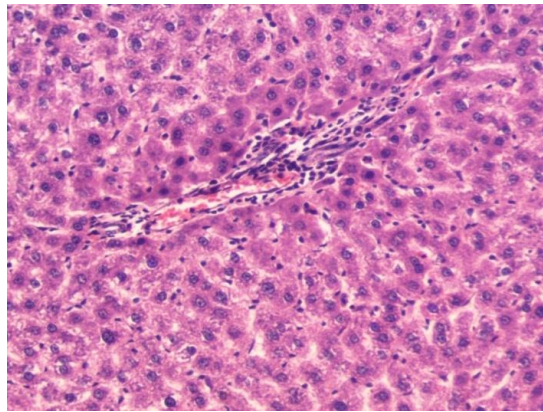


Figure 8. Liver of rat, which was injected with a reference drug (RG). Moderate infiltration of portal tract structures. Hematoxylin-eosin. x250.

Certain structural shifts were noted in 66.7% of rats against the background of the test sample, which are aimed at normalizing the cytoarchitectonics of the liver parenchyma. Thus, a more pronounced structural orientation of hepatocytes was noted, their beam structure was contoured, and the foci of violation were narrowed (Figure 9).

Dystrophic changes of hepatocytes are less pronounced, round cell infiltrates (perivascular and around triads) and foci of hepatocyte necrosis are absent. Venous plethora is significantly less, the presence of binuclear cells is increased (Figure 10).

The obtained microscopic data indicate the presence of a fairly effective protection of the liver parenchyma of these rats during the prophylactic injection of the test sample. In other animals, the signs of stress damage to the liver parenchyma at the stage of anxiety were more pronounced, in severity they are close to the control (positive control) indicators (Figure 11).

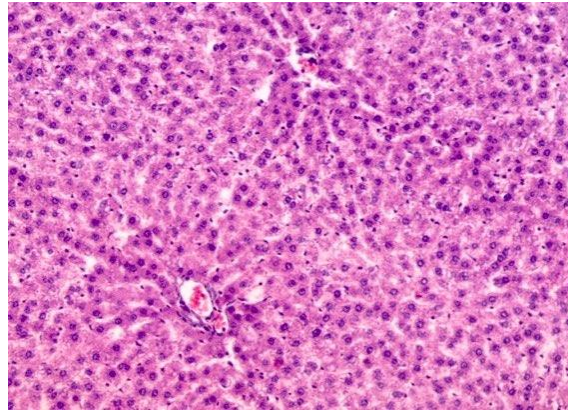


Figure 9. The liver of a rat that was injected with a test sample (TG). More pronounced structural orientation of hepatocytes. Hematoxylin-eosin. x200.

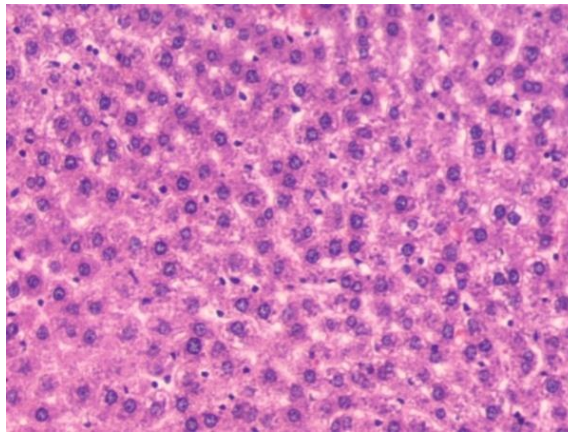


Figure 10. The liver of a rat, which was injected with a test sample (TG). Reducing the severity of hepatocyte dystrophy, venous plethora of sinusoidal capillaries. Hematoxylin-eosin. x250.

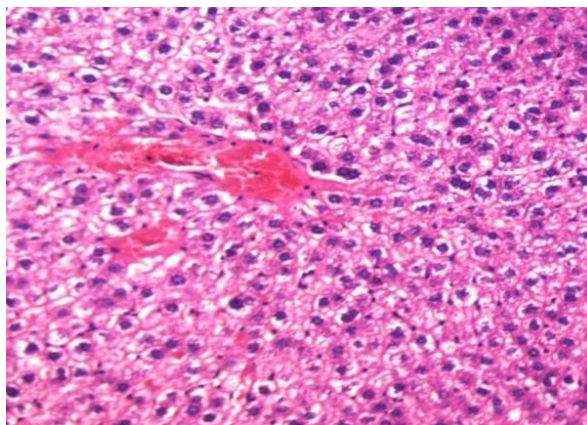


Figure 11. The liver of a rat that was injected with a test sample (TG). The severity of signs of stress damage to the liver parenchyma. Hematoxylin-eosin. x250.

In conclusion, the results of the study demonstrate the presence of stress-protective properties of sodium 2-((4-amino-5-(thiophen-2-ylmethyl)-4H-1,2,4-triazol-3-yl)thio)acetate in the model of acute immobilization stress, which was reproduced for 6 hours.

As can be seen from the described and presented microscopic picture, the test sample to some extent reduced the degree of stress damage to the liver. In terms of the positive effect on the histological condition of the liver parenchyma (a more pronounced structural orientation of hepatocytes was noted, their beam structure was contoured, dystrophic changes of hepatocytes are less pronounced, round cell infiltrates and foci of hepatocyte necrosis are absent), sodium 2-((4-amino-5-(thiophen-2-ylmethyl)-4H-1,2,4-triazol-3-yl)thio)acetate exhibits a stress-protective effect in the model of acute immobilization stress.

We can conclude about similarity of activity of the test sample with comparison drug (Mebicar®) at studying of influence on a histologic condition of a liver parenchyma.

ACKNOWLEDGEMENTS

We're grateful to the Zaporizhzhia State Medical University for providing some facilities in carrying out the research.

AUTHOR CONTRIBUTIONS

Concept: *A.S., D.D., Y.V., Y.L., D.L.*; Design: *R.Sh., A.O., S.R.*; Control: *A.S., D.D., Y.V.*; Sources: *Y.L., D.L.*; Materials: *R.Sh., A.O., S.R.*; Data Collection and processing: *Y.L., D.L., R.Sh.*; Analysis and interpretation: *A.S., D.D., Y.V.*; Literature review: *A.O., S.R., Y.L.*; Manuscript writing: *A.S., D.D.*; Critical review: *A.S., D.D., Y.V., Y.L., D.L., R.Sh., A.O., S.R.*; Other: -

CONFLICT OF INTEREST

The authors declare no conflict of interest.

ETHICS COMMITTEE APPROVAL

Minutes of the Commission on Bioethics № 6 of 08.06.2021 by National University of Pharmacy

REFERENCES

1. Sahakyan, N.A., Shogeryan, S.A., Simonyan, L.Y., Avanesyan, L.G. (2017). The effect of taurine on heart rate variability and structural and functional changes in the liver and adrenal glands during immobilization stress. *Biological Journal of Armenia*, 69(1), 61-67. From <http://test.journals.sci.am/index.php/sci-armenian-biology/article/view/1342>. Accessed date: 10.04.2022.
2. Lomakina, Y.V., Bulyk, R.E., Chernovskaya, N.V. (2015). Stress-limiting system of an aging organism under immobilization stress. *Priority Directions of Development of Science and Education*, 2, 14-15. From <https://interactive-plus.ru/e-articles/138/Action138-9894.pdf>. Accessed date: 10.04.2022.
3. Prokudina, E.S., Gorbunov, A.S., Kazakov, V.A., Saushkin, V.V., Maslov, L.N. (2019). Morphofunctional aspects of heart damage during immobilization stress in rats. *Russian Physiological Journal IM Sechenov*, 105(2), 248-257. [CrossRef]
4. Sameliuk, Y., Kaplaushenko, T., Al Zedan, F. (2021). 1,2,4-Triazole derivatives in medicine and pharmacy and application prospects. *Journal of Faculty of Pharmacy of Ankara University*, 45(3), 598-614. [CrossRef]
5. Shcherbyna, R. (2019). Microwave-assisted synthesis of some new derivatives of 4-substituted-3-(morpholinomethyl)-4H-1,2,4-triazole-5-thioles. *Journal of Faculty of Pharmacy of Ankara University*, 43(3), 220-229. [CrossRef]
6. Safonov, A. (2020). Microwave synthesis of new N-R-3-(alkylthio)-5-(thiophen-2-ylmethyl)-1,2,4-triazol-4-amines. *Journal of Faculty of Pharmacy of Ankara University*, 44(1), 89-98. [CrossRef]
7. Shcherbyna, R.A., Panasenko, A.I., Knysh, E.G., Varinsky, B.A. (2014). Synthesis and physicochemical properties of 2-((4-R-3-(morpholinomethylene)-4H-1,2,4-triazol-5-yl)thio)acetic acids. *Aktual'ni Pitannâ Farmaceutičnoi i Medičnoï Nauki ta Praktiki*, 3(16), 18-21. [CrossRef]
8. Hulina, Y.S., Kaplaushenko, A.G. (2018). Synthesis, physical and chemical properties of 5-((1H-tetrazole-1-yl) methyl)-4-R-4H-1, 2, 4-triazole-3-thiols and their chemical transformations. *Biopharmaceutical Journal*, 10(1), 26-30. From <https://elibrary.ru/item.asp?id=32694739>. Accessed date: 10.04.2022.
9. Shcherbyna, R., Parchenko, V., Varynskyi, B., Kaplaushenko, A. (2019). The development of HPLC-DAD method for determination of active pharmaceutical ingredient in the potassium 2-((4-amino-5-(morpholinomethyl)-4H-1, 2, 4-triazol-3-yl) thio) acetate substance. *Current Issues in Pharmacy and Medical Sciences*, 32(1), 5-9. [CrossRef]
10. Frolova, Y., Kaplaushenko, A., Nagornaya, N. (2020). Design, synthesis, antimicrobial and antifungal activities of new 1,2,4-triazole derivatives containing 1H-tetrazole moiety. *Journal of Faculty of Pharmacy of Ankara University*, 44(1), 70-88. [CrossRef]
11. Shcherbyna, R. (2020). An investigation of the pharmacokinetics and potential metabolites of potassium 2-((4-amino-5-(morfolinometyl)-4H-1,2,4-triazol-3-yl)thio)acetate on rats. *Journal of Faculty of Pharmacy of Ankara University*, 44(2), 233-241. [CrossRef]

12. Shcherbyna, R., Vashchyk, Y. (2019). The research of 1,2,4-triazole derivatives hepatoprotective activity under tetracycline and infectious hepatitis. *Journal of Faculty of Pharmacy of Ankara University*, 43(2), 135-146. [CrossRef]
13. Vashchyk, Y., Shcherbyna, R., Parchenko, V., Bushueva, I., Gutyj, B., Fotina, H., Fotina, T., Stronskyi, Y. (2020). Histological study of a corrective influence of a compound potassium 2-((4-amino-5-(morpholinomethyl)-4H-1,2,4-triazol-3-yl)thio)acetate (PKR-173) on the state of chicken's liver under infection by pseudomonas aeruginosa. *Journal of Faculty of Pharmacy of Ankara University*, 44(1), 1-17. [CrossRef]
14. Shcherbyna, R., Parchenko, V., Martynyshyn, V., Hunchak, V. (2018). Evaluation of acute and subacute toxicity of oil liniment based on 4-((5-(decylthio)-4-methyl-4H-1,2,4-triazol-3-yl)methyl)morpholine. *Journal of Faculty of Pharmacy of Ankara University*, 42(1), 43-52. [CrossRef]
15. Samelyuk, Y.G., Kaplaushenko, A.G. (2014). Synthesis of 3-alkylthio (sulfo)-1,2,4-triazoles, containing methoxyphenyl substituents at C5 atoms, their antipyretic activity, propensity to adsorption and acute toxicity. *Journal of Chemical and Pharmaceutical Research*, 6(5), 1117-1121. From <https://www.jocpr.com/articles/synthesis-of-3alkylthiosulfo124triazoles-containing-methoxyphenyl-substituents-at-c5-atoms-their-antipyretic-activity-pr.pdf>. Accessed date: 10.04.2022.
16. Knysh, Y.G., Panasenko, O.I., Safonov, A.A. (2016). Sodium 2-((4-amino-5-(thiophen-2-ylmethyl)-4H-1,2,4-triazol-3-yl)thio)acetate, which shows actoprotective activity. *Patent of Ukraine № 112619*, Patent published on 26.09.2016, bulletin. № 18/2016. From <https://base.uipv.org/searchINV/search.php?action=viewdetails&IdClaim=227417>. Accessed date: 10.04.2022.
17. Vyborova, I.S., Khandzhav, U., Vasilieva, L.S., Makarova, N.G. (2005). The structure of the liver in rats in the dynamics of immobilization stress. *Siberian Medical Journal (Irkutsk)*, 52 (3), 30-33. From <https://cyberleninka.ru/article/n/struktura-pecheni-u-krysv-v-dinamike-immobilizatsionnogo-stressa> Retrieved March 21, 2022. Accessed date: 10.04.2022.
18. Nair, A. B., Jacob, S. (2016). A simple practice guide for dose conversion between animals and human. *Journal of Basic and Clinical Pharmacy*, 7(2), 27. [CrossRef]
19. National research council. (2011). Guide for the care and use of laboratory animals: eighth edition, Washington, DC: The National Academies Press, p.246. [CrossRef]
20. Union, E. (2010). Directive 2010/63/EU of the European Parliament and of the Council of 22 September 2010 on the protection of animals used for scientific purposes. *Official Journal of the European Union*, 276, 33-79. From <https://eur-lex.europa.eu/LexUriServ/LexUriServ.do?uri=OJ:L:2010:276:0033:0079:en:PDF> Accessed date 21.03.2022. Accessed date: 10.04.2022.
21. Mironov, A. K. (2012). Guidelines for conducting preclinical studies of drugs. Part one, M. Grifi K. p.944.
22. Ivanov, A.V., Bobyntsev, I.I., Shepeleva, O.M., Kryukov, A.A., Andreeva, L.A., Myasoedov, N.F. (2017). Morphological changes in the liver of rats under stress and their features after the introduction of Semax. *Morphology*, 151(1), 39-43. From ftp://fulltext.kursksmu.net/fulltext/Publications_KGMU/2017/morfologicheskie.pdf Accessed date: 21.03.2022.