

## Relationship of Impacted Maxillary Third Molar Teeth with Sella Turcica Morphology

### Gömülü Maksiller Üçüncü Molar Dişlerin Sella Turcica Morfolojisi ile İlişkisi

Sanaz SADRY<sup>1</sup>, Cansu KOCA<sup>2</sup>

<sup>1</sup>Department of Orthodontics, Faculty of Dentistry, Istanbul Aydin University, Istanbul, Turkey

<sup>2</sup>Uşak University, Faculty of Dentistry, Department of Oral, Maxillofacial Surgery, Uşak, Turkey

Alınış / Received: 28.10.2019 Kabul / Accepted: 07.07.2020 Online Yayınlanma / Published Online: 31.12.2020

#### Özet

**Amaç:** Gömülü maksiller üçüncü molar dişlere sahip bireylerde sella turcica'nın morfolojik varyasyonları ile diş gömülülüğü ilişkisinin değerlendirilmesidir. **Materyal ve Metot:** Bu çalışmanın materyalini sagittal yönde üç farklı iskeletsel maloklüzyona sahip (Sınıf I, 79; Sınıf II, 71; Sınıf III, 20) 170 bireyin (79 erkek, 91 kadın, ortalama yaşı  $19,02 \pm 1,62$ ) panoramik ve lateral sefalometrik radyografları oluşturmaktadır. Çalışmaya dahil olan bireylerde gömülü maksiller üçüncü molar dişleri tek taraflı (n=121) veya çift taraflı (n=49) olarak gömülüdür. Bireylere ait lateral sefalometrik radyograflarda 6 farklı alt-grupta değerlendirilen sella turcica morfolojisinin varyasyonları ve gömülülük ilişkisi, gömülülüğün tek veya çift taraflı olması, iskeletsel anomali açısından incelenmiştir. Grupların değerlendirilmesinde Ki-Kare analiz karşılaştırma testleri kullanılmıştır. **Bulgular:** Gömülü maksiller üçüncü molar dişi bulunan 170 bireyin 91' i bayan, 79'u erkektir. Unilateral ve bilateral gömülülük açısından aralarında istatistik fark yoktur ( $p > 0,05$ ). Totalde gömülü 170 molar vakasının 79'u Sınıf I, 71' i Sınıf II, 20'si Sınıf III' dür. Fasiyal iskeletsel sınıflamada unilateral ve bilateral gömülü vakalar arasında istatistik fark yoktur ( $p > 0,05$ ). 170 bireyin yer aldığı bu çalışmada gömülü dişler total olarak değerlendirildiğinde bu çalışmada yer alan bireylerde en çok 2 numaralı sella varyasyonu izlenmiştir (170/79) (%46,5). Bu durum istatistik olarak önemlidir ( $p < 0,001$ ). Unilateral 121 gömülü molarlarda en belirgin sella varyasyonu 2 nolu varyasyondur (121/69) (%57). Bunu sırası ile sella 1, sella 4, sella 6 varyasyonları izlemektedir. Bilateral 49 gömülü molarlarda belirgin sella varyasyonu sella 6'dır (49/21)(%42,9). Bunu sırası ile sella 4, sella 2, sella 1 varyasyonları izlemektedir. Ancak bunlar istatistik olarak önemli değildir ( $p > 0,05$ ). **Sonuç:** Gömülülük ile en çok ilişkili olan sella varyasyonu 2 nolu sella varyasyonudur Bilateral maksiller molar üçüncü molar gömülülüğü Sınıf II maloklüzyona sahip kız bireylerde erkek bireylee nazaran daha fazla görülmektedir.

**Anahtar kelimeler:** Sella Turcica, Maksiller Üçüncü Molar, Sefalometri

#### Abstract

**Objective:** To evaluate the relationship between the morphological variations of sella turcica and maxillary third molar teeth impaction. **Material and Method:** The material of this study consisted panoramic radiographs and lateral cephalometric radiographs of 170 individuals (79 men, 91 women, mean age  $19.02 \pm 1.62$ ) (Class I, 79; Class II, 71; Class III, 20). Individuals, included in this study, had impacted maxillary third molars unilaterally (n = 121) or bilaterally (n = 49). The variations of the sella turcica morphology evaluated in 6 different sub-groups on the individual lateral cephalometric radiographs. And the unilateral or bilateral impaction was investigated in terms of skeletal anomaly. Chi-Square analysis comparison tests were used to evaluate the groups. **Results:** 170 individuals with impacted maxillary third molar, 91 were female and 79 were male. There is no statistical difference between them in terms of unilateral and bilateral impacted teeth ( $p > 0.05$ ). Of the 170 molar cases impaction in total, 79 are Class I, 71 are Class II, and 20 are Class III. There is no statistical difference between unilateral and bilateral buried cases in facial skeletal classification ( $p > 0.05$ ). In this study, which included 170 individuals, when the impacted teeth were evaluated as total, the 2<sup>nd</sup> sella variation was observed in the individuals in this study (170/79) (46.5%). This is statistically significant ( $p < 0.001$ ). The most evident sella variation in unilateral 121 impacted molar is 2 (121/69) (57%). This is followed by the sella 1, sella 4, sella 6 variations, respectively. In the bilateral 49 embedded molar, the prominent sella variation is 6 (49/21) (42.9%). This is followed by the sella 4, sella 2, sella 1 variations, respectively. However, these are not statistically significant ( $p > 0.05$ ). **Conclusion:** Sella 2 variation is the one most associated with impaction. Bilateral maxillary third molar impaction is more common in female individuals with Class II malocclusion than in male individuals.

**Keywords:** Sella Turcica, Maxillary Third Molar, Cephalometry.

## Introduction

Sella turcica is the anatomical structure in the middle cranial fossa, which contains the pituitary gland and has an important place in cephalometric analysis by being detected as a “sella point” on the lateral cephalometric radiograph (1). The word 'sedella' in Latin, which is shown as the origin of the word 'saddle' in English, means a chair or seat derived from the word 'sedeo' meaning 'sitting', without any support for the back or head (2). The geometric center of the structure, which is located at the base of the skull and is called sella turcica as it is compared to the Turkish saddle, has been defined as the sella (S) point on lateral cephalometric radiographs. The morphology of Sella turcica is important both in the evaluation of treatment results and late-period growth changes and in the evaluation of cranial morphology (3). Sella turcica is one of the anatomical formations used in the radiographic analysis of the neurocranial and neurofacial complex (4). Sella turcica, dental epithelial stem cells, maxillary, palatal and frontonasal development areas originate from the same embryological cells (5-7). Genetic mutations can negatively affect dental development, the development of midface and sella turcica. Sella turcica bridge is a common morphological variation that occurs as a result of an ossification of the dura mater (interclinoid ligament (ICL)) between the posterior and anterior clinoid processes or an anomaly that occurs during the embryological development of the sphenoid bone (2,5,8). At the same time, undiagnosed pathologies associated with the pituitary gland can be found on the background of the anatomical differentiation of the region (9). Sella turcica bridge can be associated with numerous local dental anomalies such as many craniofacial or systemic developmental syndromes and disorders, tooth transposition, congenital tooth deficiencies (4,5,8,10). Elongation and fusion of posterior and anterior clinoid processes are known as sella turcica bridging (11). According to the study results regarding the incidence of sella turcica bridging in radiography and autopsy studies, the incidence of bridging was reported as 4.6% (12), while bridging incidence determined by direct measurements on the skull and observation in autopsies was reported to vary between 5.5% and 6% (13, 14). Tuberculum sella, dorsum sella and sella base, which are among the anatomical parts of the sella, can be used to evaluate the variations of the sella turcica. According to the classification formed by Axelsson et al. (15) based on regional evaluation of tuberculum sella, dorsum sella and sella base, sella turcica variations (a) are normal; (b) oblique anterior wall; (c) sella turcica bridging; (d) double contours of the base; (e) irregularity in the posterior of the dorsum cella; (f) pyramidal shape of dorsum sella; (g) is studied in seven sub-classes, the combination of variations. The frequency and rate of anatomical variations in healthy individuals are considerably high. Among these morphological deviations, bridging in sella turcica is a variation frequently associated with chronic and genetic disorders (17-19). However, different studies report the probability of bridging in healthy individuals in sella turcica between 3.8% and 18% (16,20,21). The third molar teeth are the last teeth in the dental arch. They may be impacted due to various factors such as insufficient jaw growth, early physical maturation, late mineralization of the third molar tooth, absence of deciduous teeth, distal direction of eruption of other teeth, regression in facial growth, and reverse direction of growth (19). In the studies performed, it was found that the most frequently impacted teeth are the third molar teeth and this rate forms 98% of all impacted teeth (22). Factors such as poor development of the jaws, differences in facial growth, size of the teeth, insufficient retromolar distance and early loss of the mandibular second molar tooth can also be effective in the impaction of the third molar. If the third molar remains impacted, infection in the adjacent tooth, pain, dental caries, periodontal disease, root resorption, complications in denture users, indeterminate pain, dental crowding, preventing orthodontic treatment and can cause odontogenic cyst or tumors, perichoronitis, resorption, osteomyelitis ( 23). Therefore, if these teeth remain impacted, they must be prophylactically removed or regular radiological and clinical follow-up.

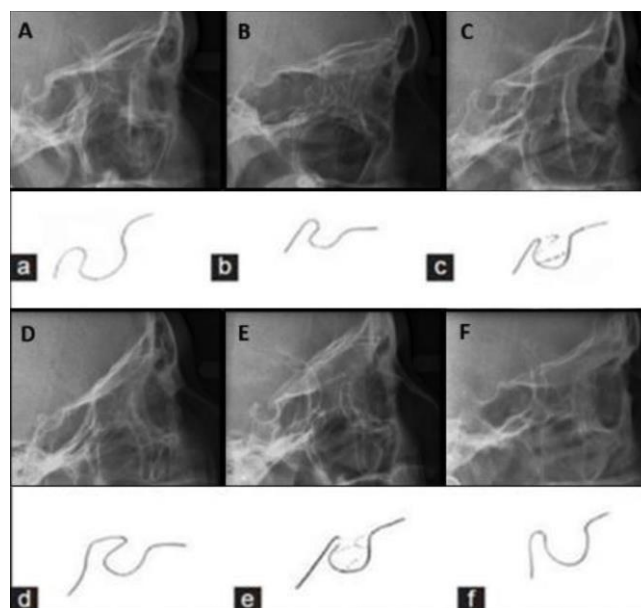
One of the most frequently used points for cephalometric examination and follow-up in lateral cephalometric radiographs is the “sella” point located in the geometric center of sella turcica (9,11). Sella Turcica morphology can vary from person to person (9). There is no study to our knowledge in the literature that examines the relationship between the anatomical variations of this important region and the impaction of maxillary third molar teeth. The revealing of this relationship can provide predictable and even precautionary measures for possible maxillary third molar tooth impaction in individuals. Additionally, the frequency of maxillary third molar impaction can be associated with different types of sella turcica. Therefore, the aim of this study is to compare the relationship between

unilateral or bilateral impaction of maxillary third molar teeth with the morphological variations of sella turcica. Additionally, the relation of facial skeletal classification type with sella turcica variations is investigated.

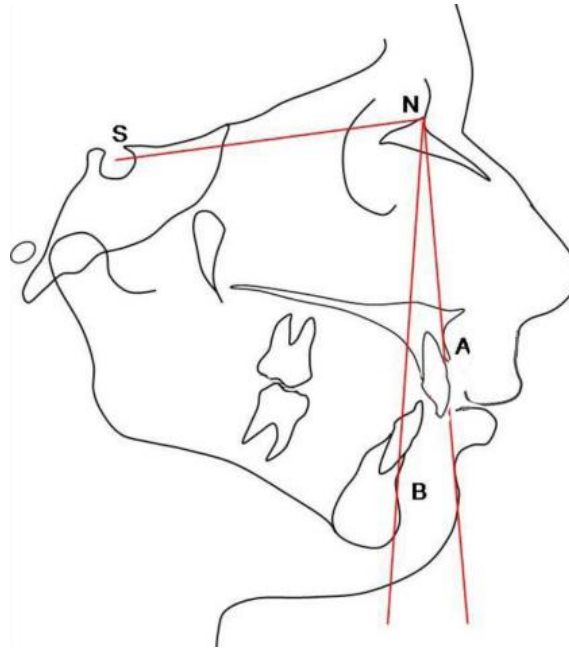
## Materials and Methods

This study was reviewed and approved by the Istanbul Aydın University Institute of Health Sciences Non-Interventional Clinical Research Ethics Committee (No:B.30.2AYD.0.00.00-50.06.04/67). In this study, the panoramic and lateral cephalometric radiographs of 170 adult individuals between the ages of 20-40 ( $25,98 \pm 4,42$ ) were used from those referred to Istanbul Aydın and Uşak University Faculty of Dentistry for orthodontic treatment between 2015-2018. All individuals included in this study had unilateral or bilateral impacted maxillary third molar teeth with full bone retention, that were examined by panoramic radiography. Patients with hereditary disorder, syndrome, incomplete root development, or a missing teeth other than third molar for any reason were excluded from the study. The sample size was calculated based on a power analysis and 90% strength using the G \* Power Software version 3.1.9.2 (Universität Düsseldorf, Germany) for the sella turcica classification with an alpha error probability of 0.05. Power analysis showed that 134 samples were needed. Lateral cephalometric radiographs were taken after the patient's head was fixed on the cephalostat, and the Frankfort horizontal plane was adjusted parallel to the ground. Natural head posture was obtained in centric occlusion parallel to the horizontal plane of Frankfurt. Radiographs were taken with the central beam perpendicular to the patient's mid oxal plane and the teeth in centric occlusion. (Promax 2D Ceph®, Planmeca, Helsinki, Finland). Attention was paid to view sella turcica clearly.

Lateral cephalometric images used in our study group are sufficient to show the craniofacial structures and the anatomy of the sella turcica, with high diagnostic quality. Anatomical sella measurements on images were made with Romexis ®Software (Planmeca, Helsinki, Finland). In this study, the classification, which was formed by Axelsson et al. (12) based on regional evaluation of tuberculum sella, dorsum sella and sella base, was used to classify our patients according to 6 different sella turcica variation groups (figure 1). Our patients' cephalometric records were measured with NemoCeph NX (Nemotech, Madrid, Spain) computerized cephalometric analysis system. The individuals in our study were classified according to the ANB angle (figure 2), determined on the lateral cephalometric radiographs as Class I, Class II and Class III in the sagittal direction (Table 1). Unilateral or bilateral maxillary third molar teeth were examined in panoramic radiographs (Proline Pan/Ceph X-Ray (Planmeca, Helsinki, Finlandiya) of each patient and recorded.



**Figure 1:** Sella calcification variations a, normal; b, oblique anterior wall; c, sella turcica bridging; d, double contours of the base; e, irregularity in the posterior of the dorsum cella; f, pyramidal shape of dorsum sella.



**Figure 2:** Cephalometric Angular Measurements

1. SNA: Angle between the anterior cranial base (S-N plane) and point A.
2. SNB: Angle between the front cranial base (S-N plane) and point B.
3. ANB: Angle between NA and NB lines. Determines the relation of the apical bases of the lower and upper jaw relative to each other. According to Steiner analysis, normal value of ANB is between 0 and 4 degrees.

To evaluate the method error, 50 films were redrawn and measured again by the same researcher 2 weeks later. Paired t test was applied between the first and second measurements and no statistically significant difference was found between the two measurements. These results show that our drawings and measurements are repeatable.

The data were evaluated in SPSS 21.0 (Statistical Package for Social Sciences, Chicago, Illinois, USA) statistical package program. The analysis of the data was evaluated using the chi-square test. The significance level was considered as  $p < 0.05$ .

## Results

This study was performed on 195 maxillary third molar teeth in a total of 170 patients, including 91 females (53.5%) and 79 (46.5%) males. In 170 patients included in the study, 49 had bilateral and 121 were unilateral impacted maxillary third molar teeth. In this study, no sella variations of 3 and 5 were detected in lateral cephalometric radiographs of cases included. For this reason, sella variations were examined over sella 1, sella 2, sella 4, sella 6. When the impacted teeth were evaluated totally, the 2nd sella variation was observed most of the individuals in this study (170/79) (46.5%) and this is statistically significant ( $p < 0.001$ ). In unilateral 121 impacted molar, the 2nd sella variation is seen, markedly (121/69) (57%). This is followed by the sella 1, sella 4, sella 6 variations, respectively. In the bilateral 49 impacted molar, the major sella variation is 6 (49/21) (42.9%). This is followed by sella 4, sella 2, sella 1 variations, respectively. However, these are not statistically significant ( $p > 0.05$ ) (Table 1). Of 170 individuals with impacted maxillary third molars, 91 were female and 79 were male. There is no statistical difference between them in terms of unilateral and bilateral impaction ( $p > 0.05$ ). 69 of 121 unilateral impacted molars are in female patients (121/69) (57%) and 52 are in male patients (121/52) (43%). Although unilateral impaction is higher in women, there is no statistical difference between them ( $p > 0.05$ ). Of the 49 bilateral impacted cases, 22 were female (49/22) (44.9%) and 27 were male (49/27) (55%). Although bilateral impaction is higher in males, there is no statistical difference between males and females ( $p > 0.05$ ) (Table 1). For this reason, the data of male and female individuals were pooled in this study. Of the 170 molar cases impacted in total, 79 are Class I, 71 are Class II, and 20 are Class III. There is no statistically significant difference between unilateral and bilateral impacted cases in facial skeletal classification ( $p > 0.05$ ). In 121 cases with unilateral maxillary

impacted third molar teeth, 55 cases (121/55) (45.5%) were Class I, 49 cases (121/49) (40.5%) and 17 cases were Class II, (121/17) (14%) is Class III. Unilateral impaction is mostly seen in individuals with Class I facial skeletal pattern. However, there is no statistical difference between them ( $p > 0.05$ ). Among 49 cases with bilateral impacted maxillary third molar teeth, 24 cases (49/24) (49%) were Class I, 22 cases (49/22) (44%) were Class II and 3 cases (49/3) (6%, 1) were Class III. Bilateral impaction is most common in Class I cases, but there is no statistical difference between them ( $p > 0.05$ ) (Table 1).

**Table 1.** Relationship of impacted molar with gender and facial skeletal classification

		Maxillary third molar teeth						chi square analysis	
		Unilateral Impacted		Bilateral Impacted		Total			
		n	%	n	%	n	%	chi square	p
Sella variations	Sella 1	30	24.8	4	8.2	34	20.0	53.1	<b>0.000</b>
	Sella 2	69	57.0	10	20.4	79	46.5		
	Sella 4	17	14.0	14	28.6	31	18.2		
	Sella 6	5	4.1	21	4.9	26	15.3		
Gender	Female	69	57.0	22	44.9	91	53.5	2.1	0.151
	Male	52	43.0	27	55.1	79	46.5		
Facial Skeletal Classification	Class I	55	45.5	24	49.0	79	46.5	2.11	0.347
	Class II	49	40.5	22	44.9	71	41.8		
	Class III	17	14.0	3	6.1	20	11.8		
<b>Total</b>		<b>121</b>	<b>100.0</b>	<b>49</b>	<b>100.0</b>	<b>170</b>	<b>100.0</b>		

n, number of individuals; %, percent; p, significance level according to ANOVA test

In cases with unilateral impacted maxillary third molar teeth and Sella 1 variation, Class II facial skeletal malocclusion was the highest with a rate of 50%. In cases with unilateral impacted maxillary third molar teeth and Sella 2 variation, Class I facial skeletal malocclusion was the highest with a rate of 49.3%. In cases with unilateral embedded maxillary third molar teeth and Sella 4 variation, Class I facial skeletal malocclusion was the highest with a rate of 58.8%. In cases with unilateral impacted maxillary third molar teeth and Sella 6 variation, Class I facial skeletal malocclusion was the highest with a rate of 60%. However, there is no statistical difference between other malocclusions ( $p > 0.05$ ) (Table 2).

**Table 2.** Relation of unilateral impacted molar with sella and facial skeletal classification

		Unilateral Impacted Molar										chi square analysis	
		Sella 1		Sella 2		Sella 4		Sella 6		Total			
		n	%	n	%	n	%	n	%	n	%	chi square	p
Facial skeletal classification	Class I	8	26.7	34	49.3	10	58.8	3	60.0	55	45.5	0.252	
	Class II	15	50.0	26	37.7	6	3.3	2	40.0	49	40.5		
	Class III	7	23.3	9	13.0	1	5.9	0	0.0	17	14.0		
	Total	30	100.0	69	100.0	17	100.0	5	100.0	121	100.0		

n, number of individuals; %, percent; p, significance level according to chi square test

In cases with bilateral impacted maxillary third molar teeth and Sella 1 variation, Class II facial skeletal malocclusion was the highest with a rate of 75%. In cases with bilateral impacted maxillary third molar teeth and Sella 2 variation, Class I facial skeletal malocclusion was the highest with a rate of 60%. In cases with bilateral impacted maxillary third molar teeth and Sella 4 variation, Class I facial skeletal malocclusion was the highest with a rate of 71.4%. In cases with bilateral impacted maxillary third molar teeth and Sella 6 variation, Class II facial skeletal malocclusion was the highest with a rate of 57.1%. However, there is no statistical difference between other variations ( $p > 0.05$ ) (Table 3).



**Table 3.** Relation of bilateral impacted molar with sella and facial skeletal classification

		Bilateral Impacted Molar										chi square analysis	
		Sella 1		Sella 2		Sella 4		Sella 6		Total		chi square	p
		n	%	n	%	n	%	n	%	n	%		
Facial Skeletal Classification	Class I	0	0.0	6	60.0	10	71.4	8	38.1	24	49.0	0.089	
	Class II	3	75.0	4	40.0	3	21.4	12	57.1	22	44.9		
	Class III	1	25.0	0	0.0	1	7.1	1	4.8	3	6.1		
	Total	4	100.0	10	100.0	14	100.0	21	100.0	49	100.0		

n, number of individuals; %, percent; p, significance level according to chi square test

In cases with unilateral impacted maxillary third molar teeth, the skeletal Class II ratio was higher in female cases (40.6%), and Class I ratio (51.9%) was higher in male cases. In cases with unilateral impacted maxillary third molar teeth, there was no statistically significant difference between the female and male individuals in terms of facial skeletal classification ( $p > 0.05$ ) (Table 4).

**Table 4:** Relationship of unilateral impacted molar with gender and facial skeletal classification

		Unilateral Impacted Molar						chi square analysis	
		Female		Male		Total		chi square	p
		n	%	n	%	n	%		
Facial Skeletal Classification	Class I	28	40.6	27	51.9	55	45.5	0.433	
	Class II	33	47.8	16	30.8	49	40.5		
	Class III	8	11.6	9	17.3	17	14.0		
	Total	69	100.0	52	100.0	121	100.0		

n, number of individuals; %, percent; p, significance level according to chi square test

In cases with bilateral impacted maxillary third molar teeth, the skeletal Class II ratio was higher in female cases (50.0%), and Class II ratio (40.7%) was lower in male cases. And this is statistically significant ( $p < 0.05$ ) (Table 5).

**Table 5:** Relationship of bilateral impacted molar with gender and facial skeletal classification

		Bilateral Impacted Molar						chi square analysis	
		Female		Male		Total		chi square	p
		n	%	n	%	n	%		
Facial Skeletal Classification	Class I	11	50.0	13	48.1	24	49.0	0.026*	
	Class II	11	<b>50.0a</b>	11	<b>40.7b</b>	22	44.9		
	Class III	0	0.0	3	11.1	3	6.1		
	Total	22	100.0	27	100.0	49	100.0		

## Discussion

The morphology of sella turcica can vary from person to person. Revealing the relationship between the anatomical variations of sella and the impaction of maxillary third molar teeth can provide predictable and even precautionary measures for possible maxillary third molar tooth impaction in individuals. In this study, unilateral or bilateral impaction of maxillary third molar teeth with the morphological variations of sella turcica is compared.

Impacted teeth; its prevalence is between 18-32% and is a common problem among a large population in the world (25). For proper insertion procedures for impacted teeth, it is necessary, as in the relations of the interlaced teeth with the adjacent anatomical structures and teeth, within the jaw. It plays an important radiological role in the treatment plan. To examine two-dimensional imaging methods such as periapical, occlusal and panoramic radiographs in radiological evaluation (26). Factors that make it difficult for the maxillary third molar teeth to settle behind the dental arch; shortness of space, difficulties in eruption and the distance they cover during rising is high (27). Skeletal development, localization of the dentition distally, the distal distance of the second molar tooth is insufficient, space shortage, make third molar teeth (TMT) the most frequently encountered teeth with their embedding due to the fact that the application is slower and later than other teeth (28,29).

In this study, sella turcica bridging was investigated in individuals with an impacted upper third molar tooth and its relationship with skeletal anomaly was compared. In the literature review, it has been determined that there are studies examining the growth-related physiological change of sella turcica morphology. These studies showed that the anterior wall of sella turcica was stable from the age of 5, and there was no significant change in the morphology of sella turcica after 12 years of age. Therefore, measurements were made on lateral cephalometric films obtained from 170 adult patients (30,31). Lang (32) reported that there was sella turcica foaming in the newborn and 9 years old child. Platzer (33) found a relationship between attachment in the internal coronoid artery and sella turcica bridging. It has also been reported that the enlargement of the sella turcica may be intracellular or juxtasellar tumor sign (34,35) or asymptomatic (36). In our study, the relationship between the sella turcica bridging and the impacted upper third molar tooth of the sella morphology was investigated.

In general, the most frequently impacted teeth in the third molar teeth are thought to be the mandibular third molar. However, there are studies reporting that the maxillary third molar teeth have a higher incidence of impaction (37). Venta et al. (38) reported that the incidence of impaction in the third molar in societies can range from 22% to 66%. However, Sağlam et al. reported that the teeth most commonly seen in Turkish society were mandibular third molar in males and maxillary third molar in females and the incidence of impaction in Turkish society was 11% (39).

In our study on 170 patients, gender difference was evaluated and 91 patients and 53.5% of individuals were females, and 79 of the patients and 46.5% were male. These rates appear to be consistent with gender distributions in similar population studies in the literature. Sarı et al (40) reported that 66% of 1602 individuals evaluated in their studies were female and 34% were male; Sayın and Türkkahraman (41), in their research covering 1356 patients, 58.48% of the individuals reported that they were female and 41.51% were male.

In our study, it is seen that there is no statistically significant difference between tooth impaction and gender. In accordance with our study, Tuğsel et al. (42) and Çelikoğlu et al. (43) did not mention a difference between the genders in the impacted tooth distribution; Dural et al. (44) and Yazıcı et al. (45) reported that the incidence of impacted teeth was higher in women than in men. This may be due to the fact that the individuals included in our study were particularly a group with maxillary third molar impaction.

In this study, the lowest patient age was 19 and the highest patient age was 40 years. The average age of 170 patients in our study was 25.98 (25.98 ± 4.4), and the median value was calculated as 25. In the literature, the timing of the third molar teeth varies according to the populations; For example, it was reported that Nigerians were around 16 years old, while Greeks were 24 years old, in men this time was 3-6 months ahead of women (46,47). However, the average age for these teeth to continue is accepted as 20 years. In our study, individuals between the ages of 19-40 were included in the study group since the problems with the third molars were the most common and therefore the most treated period for these teeth. Interlinoid ligament calcification is defined radiologically as the roof or bridge of sella. Becktor et al. (3), Jones et al. (20) reported bridging in many individuals with severe craniofacial anomalies. Many pathological conditions are associated with sella calcification, but if there are no clinical symptoms, the sellabridge is considered a developmental anatomical variation of sella turcica (21). No sella variations 3 and 5 were encountered in individuals included in this study. For

this reason, Sella variations were investigated on sella 1, sella 2, sella 4, sella 6. In our study group, it was observed that other studies were compatible with our results as the frequency of 6 types of skeletal malocclusion and sella turcica (10, 20,21).

In this study, a linear relationship was found between age and sella calcification in our study group consisting of individuals between the ages of 19-40. Although not statistically significant, female rates are higher in Sella 1, 2, 6 groups, while male rates (64.5%) are higher in Sella 4 group. However, our study results revealed that there was no statistically significant relationship between sella calcification and gender. And this conclusion is consistent with the results of Ali et al. (48), who revealed that there was no relationship between gender and age and sella calcification in their studies. In contrast, Haji Ghadimi et al. (5) reported a positive relationship between sella turcica bridge and gender in their studies. The reason for this may be the ages of the individuals in the study because Leonardi et al. (7,8) showed in their studies that the interlinoid ligament calcification degree does not change between men and women, and the frequency of complete calcification increases with age.

The frequency of sella calcification variations according to facial skeletal classification was evaluated in our study group. In the sample group used in our study, it was seen that individuals with sella calcification type 4 had a higher rate in Class I malocclusion. On the other hand, none of the individuals in the study material had sella type 3 and sella type 5. The findings of the study obtained are not compatible with the literature (49,50). This may be attributed to the very small number of individuals with Class III malocclusion in our study. A limited number of studies have been conducted in the literature on this subject. In future studies, it may be appropriate to evaluate this situation by conducting studies in which case distribution is similar according to facial skeletal classification. Future studies are planned to be the same.

In the literature review, no study on the morphology of sella turcican was found in individuals with Class II and Class III malocclusion according to facial skeletal classification. In our study, sella 1 and 6 variations in skeletal Class II individuals and sella 2 and 4 variations in Class I individuals were observed. In the literature, it has been revealed that in skeletal Class III individuals, sella calcification type 3 is more common than type 1 and type 2 (4,51,52). Although no statistically significant difference was observed, according to the information obtained from this study, individuals with Class 1 Sella variation, with Class II malocclusion, are more likely to have unilateral-bilateral impaction in their maxillary third molar teeth. Individuals with Class II or 4 Sella variations and Class I skeletal malocclusion are more likely to have unilateral-bilateral impaction in their maxillary third molar teeth. In addition, in cases with Class I malocclusion compared to other malocclusions, unilateral or bilateral impacted maxillary third molar teeth are more likely seen.

## Conclusion

The sella variation that is most associated with impaction is the sella variation 2. Bilateral maxillary molar third molar impaction is more common in female individuals with Class II malocclusion than in male individuals.

## References

1. Yassir AY, Nahidh M, Yousif HA. Size and morphology of sella turcica in Iraqi adults. *Mustansiria Dent J* 2010;(7):23-30.
2. Mutluer S. Sella turcica. *Childs Nerv Syst* 2006;(22):333.
3. Becktor JP, Einersen S, Kjaer I. A sella turcica bridge in subjects with severe craniofacial deviations. *Eur J Orthod* 2000;(22):69-74.
4. Meyer-Marcotty P, Reuther T, Stellzig-Eisenhauer A. Bridging of the sella turcica in skeletal Class III subjects. *Eur J Orthod* 2010;(32):148-53.
5. Haji Ghadimi M, Amini F, Hamed S, Rakhshan V. Associations among sella turcica bridging, atlas arcuate foramen (ponticulus posticus) development, atlas posterior arch deficiency, and the occurrence of palatally displaced canine impaction. *Am J Orthod Dentofacial Orthop* 2017;(151):513-20.



6. Kjær I. Sella turcica morphology and the pituitary gland- a new contribution to craniofacial diagnostics based on histology and neuroradiology. *Eur J Orthod* 2015;(37):28-36.
7. Leonardi R, Barbato E, Vichi M, Caltabiano M. Skeletal anomalies and normal variants in patients with palatally displaced canines. *Angle Orthod* 2009;(79):727-32.
8. Leonardi R, Barbato E, Vichi M, Caltabiano M. A sella turcica bridge in subjects with dental anomalies. *Eur J Orthod* 2006;(28):580-5.
9. Alkofide EA. The shape and size of the sella turcica in skeletal Class I, Class II, and Class III Saudi subjects. *Eur J Orthod* 2007;(29):457-63.
10. Shrestha GK, Pokharel PR, Gyawali R, Bhattarai B, Giri J. The morphology and bridging of the sella turcica in adult orthodontic patients. *BMC Oral Health* 2018;(18):45.
11. Sobuti F, Dadgar S, Seifi A, Musavi SJ, Hadian H. Relationship between bridging and dimensions of sella turcica with classification of craniofacial skeleton. *Pol J Radiol* 2018;(83):120-6.
12. Zagga AD, Ahmed H, Tadros AA, Saidu SA. Description of the normal variants of the anatomical shapes of the sella turcica using plain radiographs: experience from Sokoto, Northwestern Nigeria. *Ann Afr Med* 2008;(7):77-81.
13. Camp JD. The normal and pathologic anatomy of the sella turcica as revealed at necropsy. *Radiology* 1923;(1):65-73.
14. Berglund RM, Ray BS, Torack RM. Anatomical variations in the pituitary gland and adjacent structures in 225 human autopsy cases. *J Neurosurg* 1968;(28):93-99.
15. Carstens M. Die sella diagnostik. *Fortschr Geb Rontgenstrahlen* 1949;(71):257-272.
16. Axelsson S, Storhaug K, Kjaer I. Post-natal size and morphology of the sella turcica. Longitudinal cephalometric standards for Norwegians between 6 and 21 years of age. *Eur J Orthod* 2004;(26):597-604.
17. Canigur Bavbek N, Dincer M. Dimensions and morphologic variations of sella turcica in type 1 diabetic patients. *Am J Orthod Dentofacial Orthop* 2014;(145):179-87.
18. Korayem M1, Alkofide E. Size and shape of the sella turcica in subjects with Down syndrome. *Orthod Craniofac Res* 2015;(18):43-50.
19. Venta I, Ylipaavalniemi P, Turtola L. Clinical Outcome of Third Molars in Adults Followed During 18 Years. *J Oral Maxillofac Surg.* 2004;(62):182-185.
20. Jones RM, Faqir A, Millett DT, Moos KF, McHugh S. Bridging and dimensions of sella turcica in subjects treated by surgical-orthodontic means or orthodontics only. *Angle Orthod* 2005;(75):714-8.
21. Leonardi R, Barbato E, Vichi M, Caltabiano M. A sella turcica bridge in subjects with dental anomalies. *Eur J Orthod* 2006;(28):580-5.
22. Peterson LJ. Principles of oral and maxillofacial surgery. Philadelphia: Lippincott; 2nd ed., London: BC Decker, Inc, 2004.
23. Peterson LJ, Ellis III E, Hupp JR, Tucker MR Contemporary Oral & Maxillofacial Surgery, 3rd ed. Mosby, St. Louis. 1998;215-48.
24. Taveras JM, Wood EH. Diagnostic Neuroradiology. MD: Williams & Wilkins Co 1964.
25. Padhye MN, Dabir AV, Girotra CS, Pandhi VH. Pattern of mandibular third molar impaction in the Indian population: a retrospective clinico-radiographic survey. *Oral surgery, oral medicine, oral pathology and oral radiology.* 2013;116(3):e161-6.
26. Liu DG, Zhang WL, Zhang ZY, Wu YT, Ma XC. Localization of impacted maxillary canines and observation of adjacent incisor resorption with cone-beam computed tomography. *Oral surgery, oral medicine, oral pathology, oral radiology, and endodontics.* 2008;105(1):91-8.
27. Turker MN. Evaluation of 20 age teeth and M3 distance buried in people who lived in different circuits in Anatolia. *Journal of A.U. Dentist. Faculty* 1980;(18): 37-48.
28. Milles M, Desjardins PJ, Pawel HE. The facial plethysmograph: A new instrument to measure facial swelling volumetrically. *J Oral Maxillofac Surg* 1985; (43): 346-352.
29. Quek SL, Tay CK, Tay KH, Toh SL, Lim KC. Pattern of third molar impaction in a Singapore Chinese population: a retrospective radiographic survey. *Int J Oral Maxillofac Surg.* 2003;32:548-52.
30. Björk A. Cranial base development: A follow-up xray study of the individual variation in growth occurring between the ages of 12 and 20 years and its relation to brain case and face development. *Am J Orthod* 1955;41:198-225.
31. Melsen B. The cranial base. *Acta Odontologica Scandinavica* 1974;32: suppl 62,1-126.

32. Lang J. Structure and postnatal organization of heretofore uninvestigated and infrequent ossifications of the sella turcica region. *Acta Anat* 1977;99:121-139.
33. Platzer W. Zur anatomie der "sellabrücke" und ihrer beziehung zur A. carotis interna. *Fortsch Geb Roentgen Nuklear* 1957;87:613-616.
34. Weisberg LA, Zimmerman EA, Frantz A. Diagnosis and evaluation of patients with enlarged sella. *Am J Med* 1976;61:590-596.
35. Teal JS. Radiology of the adult sella turcica. *Bull Los Angeles Neurol Soc* 1977;42:111-174.
36. Weisberg LA. Asymptomatic enlargement of the sella turcica. *Arch Neurol* 1975;32:483-485.
37. Miloro M, Ghali GE, Larsen PE, Waite PD. Peterson's Principles of Oral and Maxillofacial Surgery. 2nd ed., London: BC Decker, Inc, 2004.
38. Venta I, Turtola L, Ylipaavalniemi P. Radiographic follow-up of impacted third molars from age 20 to 32 years, *Int J Oral Maxillofac Surg.* 2001;(30): 54 -57.
39. Sağlam AA, Tüzüm MS. Clinical and radiologic investigation of the incidence, complications, and suitable removal times for fully impacted teeth in the Turkish population. *Quintessence Int.* 2003;34(1):53-9.
40. Sarı Z, Uysal T, Karaman Aİ, Başçiftçi FA, Üşümez S, Demir A. Ortodontik malokluzyonlar ve tedavi seçeneklerinin değerlendirilmesi: epidemiyolojik çalışma, *Türk Ortodonti Dergisi*, 2003;16(2), 119-26.
41. Sayın MO, Türkkahraman H. Malocclusion and crowding in an orthodontically referred Turkish population, *Angle Orthod*, 2004;74(5), 635-9.
42. Tuğsel Z, Kandemir S, Küçükler F. Evaluation of Burial Situations of Third Molars in University Students. *Cumhuriyet University. Dentist. Faculty. Journal* 2001; 22 (4): 102-5.
43. Çelikoğlu M, Miloğlu Ö, Kamak H, Kazancı F, Öztekin Ö, Ceylan İ. Retrospective Investigation of Embedded Teeth Frequency in Individuals Living in Erzurum and its Vicinity and Their Age Between 12-55. *Atatürk Univ. Dentist. Faculty. Journal.* 2009; 19: 72-5.
44. Dural S, Avcı N, Karabıyıkoglu T. The incidence of buried teeth, their distribution according to the jaws and the reasons for impaction. *Journal of Health Sciences Research.* 1996; 7: 127-33.
45. Yazıcı S, Kökden A, Tank A. A Retrospective Study on Embedded Teeth. *Cumhuriyet University Dentist. Faculty Journal.* 2002; 5: 46-51.
46. Kronmiller, JE, beeman, CS, nguyen, T, bemdt, W. Blockade of the initiation of murine odontogenesis in vitro by citral, an inhibitor of endogenous retinoic acid synthesis. *Arch Oral Biol.* 1995;(40): 645-652.
47. Alling CC, Helfrick JF, Alling RD, *Impacted Teeth*, WB Saunders Company, Philadelphia, 1993.
48. Ali B, Shaikh A, Fida M. Association between sella turcica bridging and palatal canine impaction. *Am J Orthod Dentofacial Orthop* 2014;(146):437-41.
49. Abdel-Kader HM. Sella turcica bridges in orthodontic and orthognathic surgery patients. A retrospective cephalometric study. *Aust Orthod J* 2007;(23):30-5.
50. Marsan G, Oztas E. Incidence of bridging and dimensions of Sella turcica in class I and class III Turkish adult female patients. *World J Orthod* 2009;(10):99-103.
51. Weisberg LA. Asymptomatic enlargement of the sella turcica. *Arch Neurol* 1975;(32):483-485.
52. Cederberg RA, Benson BW, Nunn M, English JD. Calcification of the interclinoid and petroclinoid ligaments of sella turcica: a radiographic study of the prevalence. *Orthod Craniofac Res* 2003;(6):227-32.