

Isolated Sphenoid Sinus Pathology: Retrospective Analysis of 7 Cases ***İzole Sfenoid Sinüs Patolojileri: 7 Olgunun Retrospektif Analizi***

Alper Dilci, Ömer Bilaç, Ersem Giritli

Eskişehir Yunus Emre Devlet Hastanesi, Kulak Burun Boğaz Hastalıkları Baş Boyun Cerrahisi Bölümü,
Eskişehir, Türkiye

Abstract: To investigate the clinical characteristics of the patients who underwent endoscopic sphenoid sinus surgery for isolated sphenoid sinus disease and to evaluate the management skills of ENT Department of Eskisehir Yunus Emre State Hospital in isolated sphenoid pathologies. Seven patients who underwent endoscopic sphenoid sinus surgery for isolated sphenoid sinus disease are included in the study. Clinical characteristics and main symptoms of patients, physical examination, radiologic findings and management approaches were investigated retrospectively. We identified 7 cases of isolated sphenoid sinus disease between January 2015 and January 2016 in ENT Department of Eskisehir Yunus Emre State Hospital. Three cases with fungal infection of sphenoid sinus, 2 cases with with sphenochanal polyp and 2 cases with mucocele were treated by endoscopic sphenoidotomy. Isolated sphenoid sinus pathologies are rare clinical entities. Diagnosis is based on the history, endoscopic examination and computed tomography findings. Endoscopic sphenoidotomy is a safe and easy treatment option and represented the gold standard for this disease at the present time.

Keywords: sphenoid sinus, sphenoidotomy, endoscopic

Dilci A, Bilac Ö, Giritli E. (2018). Isolated sphenoid sinus pathology: retrospective analysis of 7 cases, *Osmangazi Journal of Medicine* 40 (1):83-89 **Doi:** 10.20515/otd.359851

Öz: Eskişehir Yunus Emre Devlet Hastanesi KBB Kliniği'nde izole sfenoid sinüs hastalığı için endoskopik sfenoid sinüs cerrahisi yapılan hastaların klinik özelliklerini ve tedavi stratejilerini paylaşım yaklaşım önerilerinde bulunmak. İzole sfenoid sinüs patolojisi için endoskopik sfenoid sinüs cerrahisi yapılan 7 hastanın klinik özellikleri, fizik muayeneleri, radyolojik bulguları ve tedavi yaklaşımları retrospektif olarak incelendi. Ocak 2015 ve Ocak 2016 arasında Eskişehir Yunus Emre Devlet Hastanesi KBB Kliniği'nde 7 hasta izole sfenoid sinüs hastalığı için tedavi edildi. Bu hastaların 3 tanesinde fungal enfeksiyon, 2 tanesinde sfenokanal polip ve 2 tanesinde mukosel mevcuttu ve tüm hastalar endoskopik sfenoidotomi tekniği ile tedavi edildi. İzole sfenoid sinüs hastalıkları klinik pratikte nadir karşılaşılan bir klinik antitedir. Hastalığın tanısı; hikaye, endoskopik muayene ve bilgisayarlı tomografi bulguları ile konulur. Endoskopik sfenoidotomi günümüzde bu patolojiler için altın standart olarak kabul gören güvenli ve efektif bir tedavi seçeneğidir.

Anahtar Kelimeler: sfenoid sinüs, sfenoidotomi, endoskopik

Dilci A, Bilac Ö, Giritli E. (2018), İzole sfenoid sinüs patolojileri: 7 olgunun retrospektif analizi, *Osmangazi Tıp Dergisi* 40(1):83-89 **Doi:** 10.20515/otd.359851

1. Introduction

The sphenoid sinus was defined as the neglected sinus by van Alyea, in 1941 because of its isolated position and difficult accessibility (1). However, sphenoid sinus disease has been reported increasingly in recent medical literature. Isolated sphenoid sinus pathology is a rare clinical condition among patients with paranasal sinus disease, reported incidence between 1% - 3% (2). The location and difficult accessibility of sinus is suggested to make it less accessible to infectious agents.

Isolated sphenoid sinus lesions most commonly present with headache, ophthalmological and nasal symptoms. Delayed diagnosis may occur due to its nonspecific symptoms (3). However, there are many vital structures, including the middle cranial fossa, internal carotid artery, optic nerve and optic chiasm, cavernous sinus, brain, meninges and cranial nerves adjacent to sphenoid sinus (4). Improper management of sphenoid sinus disease may lead to serious complications such as orbital abscess, cavernous sinus thrombosis, meningitis, epidural, subdural, cerebral abscess (5).

The signs and symptoms of isolated sphenoid sinus disease may be unclear and nonspecific, is difficult to diagnose with history and physical examination due to the location of the sinus (6). Beside the symptoms and physical examination finding(s); nasal

endoscopy and better imaging technologies such as CT and MRI allow the early diagnosis of sphenoid sinus disease. Differential diagnosis has to be made with sphenoid sinusitis, fungal infection, benign neoplasms such as inverted papilloma and malignant neoplasms for isolated sphenoid sinus pathology (7).

In this study, we present seven patients who underwent endoscopic sphenoid sinus surgery for isolated sphenoid sinus disease in Eskisehir Yunus Emre State Hospital. The purpose of this study is to review our experience with lesions located in the sphenoid sinus.

2. Material and methods

In this retrospective study, seven patients who underwent endoscopic sphenoid sinus surgery for isolated sphenoid sinus disease were presented between January 2015 and January 2016 in Eskisehir Yunus Emre State Hospital ENT Department. Data collected from the archives of patient files and surgical notes of Eskisehir Yunus Emre State Hospital. Informed consent was taken from all patients who included in this study. Patient demographics, presenting symptoms, surgical details and histopathological outcome were evaluated (Table 1).

Table 1.

Sociodemographic findings and histopathologic outcomes of the sample

Patients	Age / Gender	Signs and symptoms	Histopathological outcome
1	62 y / female	Vertex and occipital headache, postnasal drip	Fungal infection
2	57 y / male	Retroorbital headache	Fungal infection
3	65 y / female	Retroorbital headache, postnasal drip, nasal discharge	Fungal infection
4	22 y / female	Vertex and occipital headache	Mucocele
5	35 y / male	Nasal obstruction and bifrontal headache	Mucocele
6	38 y / female	Nasal obstruction, nasal discharge	Polyp
7	32 y / female	Nasal obstruction	Polyp

Diagnosis of isolated sphenoid sinus disease was based on the history, physical examination, nasal endoscopy and radiological evaluation. At the time of the diagnosis, there was no involvement of the other sinuses. Patients were evaluated by objective ear, nose, throat examination including flexible nasal sinus endoscopy. The diagnosis was confirmed by paranasal sinus CT in axial and coronal sections. This series also included patients whose disease was detected incidentally by other departments especially neurology and neurosurgery. MRI was performed in patients suspected for fungal infection and malignancy; also performed in patients whose disease was detected in neurology and neurosurgery.

2. Surgical technique

The endoscopic sphenoid sinus surgery was performed in anti-trendelenburg position under general anesthesia. Nasal decongestion is obtained by applying a lidocaine and adrenaline soaked cotton pledgets in nasal cavity before the surgery. After the decongestion, cotton pledgets are removed and local anesthetic infiltration is applied. Middle turbinate is gently displaced laterally. The sphenoid sinus rostrum is approached between the middle and superior turbinates laterally and the septum medially. The sphenoid sinus ostium is identified 1.5 cm above the choana. Superior concha is visualized by 0 or 30 degree endoscope and the inferior portion of superior concha is resected. Sphenoidotomy is performed in an inferomedial direction. Sphenoid sinus ostium is widened and pathology is removed. The whole mucosa is never excised. At the end of the intervention, nasal cavity is irrigated and nasal packs are placed. Tampons are removed between first and second postoperative days. After the intervention, patients are treated with antibiotic therapy. Every patient is followed in 3 months intervals in the first postoperative year.

3. Results

Seven patients who underwent endoscopic sphenoidotomy for isolated sphenoid sinus pathology were included in this study. There

were 5 female and 2 male patients ranging from 22 to 65 years. Sphenoid sinus involvement was unilateral in 3 patients. Two patients with sphenoidal polyps and 2 patients with sphenoidal mucocele had unilateral sphenoidal disease. Patients were stratified into groups based on the pathological condition. Fungal infection, polyps and mucoceles are the main groups of isolated sphenoid disease in this study.

Five patients presented with headache that did not respond to simple analgesia. Headache was either occipital, retroorbital, bifrontal and vertex; was nonspecific in quality. Nasal symptoms were the second most common presenting symptoms. These included nasal obstruction in three patients, postnasal drip and nasal discharge in two patients. Nasal obstruction was major complaint in the sphenoidal polyp cases due to the size of the polyp. Nasal symptoms were resistant to main medical treatment.

Endoscopic examination was performed in all patients. Four patients had positive findings in the endoscopic examination. Polypoid tissue in the sphenoidal recess in two patients (Fig1), mucopurulent discharge in the sphenoid ostium in a patient and swelling, congestion and edema in a patient. All patients were investigated with CT scan of the paranasal sinuses. If there was a suspicion of sphenoidal mass, contrast enhancement was utilized and MRI was performed (Fig2). Four patients underwent MRI evaluation and fungal infection was diagnosed in three of them and mucocele was diagnosed in the other (Fig 3).

Endoscopic sphenoidotomy was performed for all patients. In three of the patients extended unilateral sphenoidotomy was performed for fungus ball. Internal carotid artery dehiscence was seen in a patient with fungal infection (Fig 4). There were no major complications during the surgeries. All patients reported improvement in symptoms postoperatively. Hospital stay ranged from a minimum number of a day to a maximum of 3 days. Routine postoperative CT or MRI scanning were not conducted; nasoendoscopy was applied in the follow up period. Patients

were followed up in 3 months intervals during a year and no recurrences were reported.

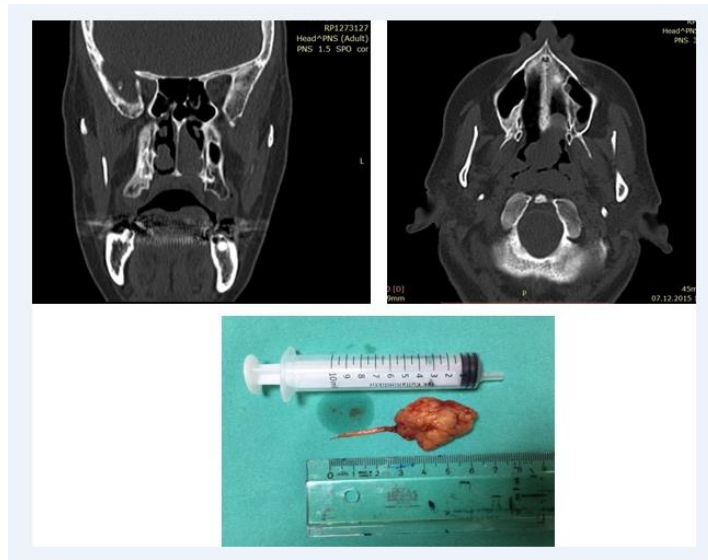

Figure 1. Polypoid tissue excised from the sphenoid sinus and preoperative CT findings of the patient

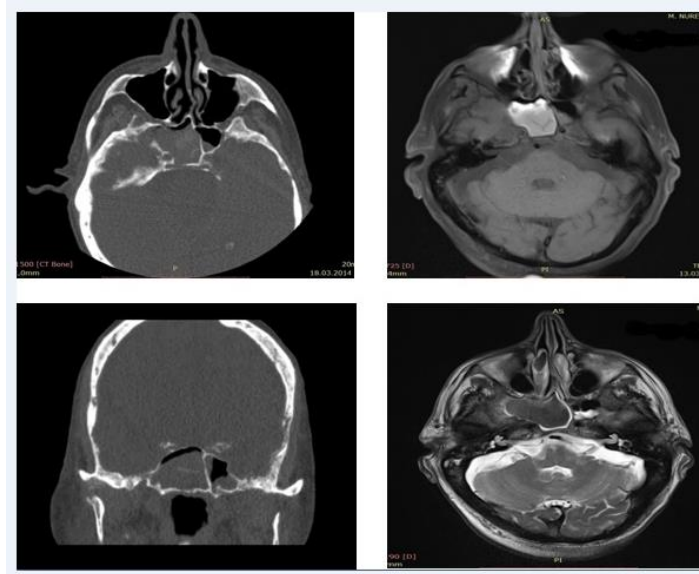


Figure 2. CT and MRI images of the case with fungus ball of sphenoid sinus.

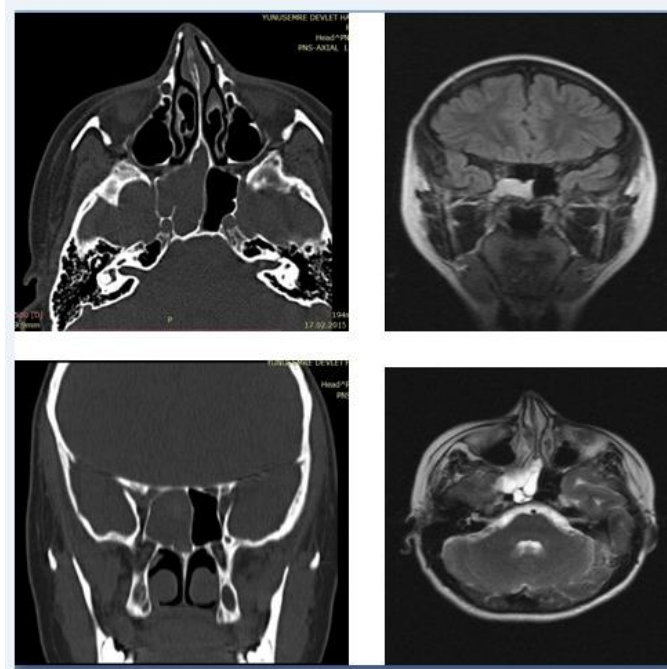


Figure 3. CT and MRI findings of the mucocoele in the sphenoid sinus

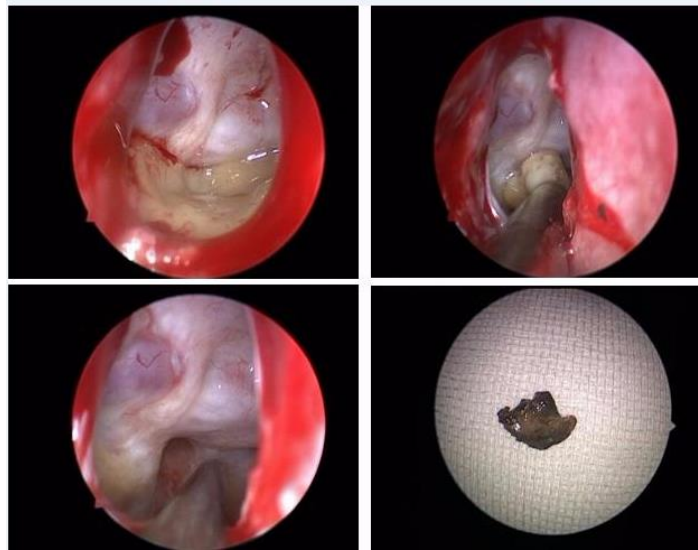


Figure 4. Intraoperative images of fungal infection of sphenoid sinus. Dehiscence was detected on the wall of carotid canal and calcified material resulted from fungal infection (in the) sphenoid sinus

4. Discussion

Isolated sphenoid sinus disease is an uncommon disease that affects 1-3 % of patients. Compared to the other sinuses, it presents several diagnostic and therapeutic challenges. Inflammatory etiologies are

responsible for 61 -82% of isolated sphenoid pathologies, followed by benign or malignant neoplasm (8). Malignancy of sphenoid sinus could also be reported, yet in our series we could not diagnose any. Fulminant headaches, visual disturbances, CSF rhinorrhea, cranial nerves deficits can be seen in malignant cases

of this region (9). It is usually insidious in onset and may present with nonspecific symptoms like headache and nasal obstruction. The most common symptom of sphenoid sinus disease is headache. In the majority of previous reports, headache was nonspecific in location, quality and intensity (10). Headache was presenting and major symptom in 71 % of cases in our series. Nasal symptoms were the second most commonly complaint in our case series. Two patients had a huge polypoid mass arising from sphenoid sinus blocking the nasal airway. Visual disturbances are often the second most common symptoms for sphenoid pathology in other series, but in our study we could not see any. It may be due to the fact that there is not any neoplastic mass in sphenoid sinus in this study.

The diagnosis of isolated sphenoid sinus disease is based on history, physical examination including nasoendoscopy and radiologic studies. Sphenoethmoidal recess can be identified by endoscopic nasal examination (11). However; 57% patients in our series present with endoscopic findings. Normal looking sphenoethmoidal recess on nasoendoscopy does not exclude sphenoid pathology so radiologic studies must be used (12). In isolated sphenoid sinus pathologies; CT imaging may reveal a spectrum of pathology ranging from mucosal thickening to opacifications of sinus. It is valuable in showing the bone details with the ability of differentiating the sinus wall expansion and destruction. Fungal infections of the sphenoid sinus require more special attention. It is occasionally not distinguishable from benign or malignant tumors. All suspected mass lesions within the sphenoid sinus should be evaluated with MRI as it provides more information about the soft tissues (13).

There are many surgical techniques used to access the sphenoid sinus including subfrontal, frontotemporal, subtemporal transcranial, transfacial, transseptal. These techniques require surgical violation to the other structures to reach sphenoid sinus. The transnasal surgical approaches to isolated sphenoid sinus diseases include the

endoscopic transnasal, endoscopic transtympanic, endoscopic transethmoid, transseptal and endoscopic pterygoid fossa (14). If necessary each of these can be used in conjunction with an extracranial approach. In cases involving inflammatory process like in this case series; endoscopic transnasal sphenoidotomy has been reported to be safe and effective. The key point in approaching the sphenoid sinus is adequate exposure of the sphenoethmoidal recess to identify the sphenoid sinus ostium endoscopically. Once the sphenoid ostium is sufficiently enlarged, surgery can be performed with caring to optic and carotid canal. Like in our series, dehiscence can be seen in optic or carotid canals and harmful maneuvers to these structures can cause major complications during the surgery. This technique offers several advantages: better view of anatomic structures, no visible scars, lesser traumatism, small postoperative morbidity, preservation of physiological mucociliary drainage and shorter hospitalization. Unfortunately, difficult management of intraoperative bleeding and any other complications in surgery, long and difficult learning curve for the operator and need for special instruments are the major disadvantages.

5. Conclusion

Isolated sphenoid sinus diseases occurs relatively infrequent and presenting symptoms are often nonspecific. Headaches, nasal symptoms, visual disturbances, cranial nerve findings can be reported. Inflammatory diseases are the most common reasons of isolated sphenoid sinus disease presented with unlocalized headache and nasal findings. Diagnosis and management of sphenoid sinus can be challenging in some cases. History, physical examination including nasoendoscopy and radiologic studies must be necessary for appropriate diagnosis. Especially, for inflammatory lesions of sphenoid sinus; minimally invasive endoscopic transnasal sphenoidotomy is safe and effective method. Anatomic relations of major structures in sphenoid sinus and skull base should always be kept in mind during the management.

KAYNAKLAR

1. Van Alyea OE. Sphenoid sinus: anatomic study, with consideration of the clinical significance of the structural characteristics of the sphenoid sinus. *Arch Otolaryngol.* 1941;34:225-253.
2. Lawson W, Reino AJ: Isolated sphenoid sinus disease: an analysis of 132 cases. *Laryngoscope.* 1997;107(12 pt 1):1590-1595.
3. Nour YA, Al-Madani A, El-Daly A, Gaafar A. Isolated sphenoid sinus pathology: Spectrum of diagnostic and treatment modalities. *Auris Nasus Larynx.* 2008;35:500-508.
4. Wang ZM, Kanoh N, Dai CF, Kutler DI, Xu R, Chi FL, et al: Isolated sphenoid sinus disease: an analysis of 122 cases. *Ann Otol Rhinol Laryngol.* 2002;111:323-327.
5. Goldman A. Complications of sphenoid sinusitis. *Oper Techn Otolaryngol.* 2003;14:216-218.
6. Ng YH, Sethi DS: Isolated sphenoid sinus disease: differential diagnosis and management. *Curr Opin Otolaryngol Head Neck Surg.* 2011; 19:16-20.
7. Grillone GA, Kasznica P. Isolated sphenoid sinus disease. *Otol Clin N Am.* 2004;37:435-451.
8. Cakmak O, Shohet MR, Kern EB. Isolated sphenoid sinus lesions. *Am J Rhinol.* 2000; 14:13-19.
9. Ghosh R, Dubal PM, Chin OY, Patel TD, Echanique KA, Baredes S, et al. Sphenoid sinus malignancies: a population - based comprehensive analysis. *Int Forum Allergy Rhinol* 2016; 19 [Epub ahead of print].
10. Ruoppi P, Seppa J, Pukkila M, Nuutinen J. Isolated sphenoid sinus diseases: report of 39 cases. *Arch Otolaryngol Head Neck Surg.* 2000; 126:777-781.
11. Gibbons MD, Sillers MJ. Minimally invasive approaches to the sphenoid sinus. *Otolaryngol Head Neck Surg.* 2002;126:635-641.
12. Sethi DS. Isolated sphenoid lesions: diagnosis and management. *Otolaryngol Head Neck Surg.* 1999;120:730-736.
13. Branstetter IV BF, Weismann JL. Role of MR and CT in the paranasal sinuses. *Otolaryngol Clin North Am.* 2005;38:1279-1299.
14. Martin TJ, Smith TL, Smith MM, Loehrl TA. Evaluation and surgical management of isolated sphenoid sinus disease. *Arch Otolaryngol Head Neck Surg.* 2002;128:1413-1419.